This is a digital copy of a book that was preserved for generations on library shelves before it was carefully scanned by Google as part of a project to make the world's books discoverable online.

It has survived long enough for the copyright to expire and the book to enter the public domain. A public domain book is one that was never subject to copyright or whose legal copyright term has expired. Whether a book is in the public domain may vary country to country. Public domain books are our gateways to the past, representing a wealth of history, culture and knowledge that's often difficult to discover.

Marks, notations and other marginalia present in the original volume will appear in this file - a reminder of this book's long journey from the publisher to a library and finally to you.

Usage guidelines

Google is proud to partner with libraries to digitize public domain materials and make them widely accessible. Public domain books belong to the public and we are merely their custodians. Nevertheless, this work is expensive, so in order to keep providing this resource, we have taken steps to prevent abuse by commercial parties, including placing technical restrictions on automated querying.

We also ask that you:

+ *Make non-commercial use of the files* We designed Google Book Search for use by individuals, and we request that you use these files for personal, non-commercial purposes.

+ *Refrain from automated querying* Do not send automated queries of any sort to Google's system: If you are conducting research on machine translation, optical character recognition or other areas where access to a large amount of text is helpful, please contact us. We encourage the use of public domain materials for these purposes and may be able to help.

+ *Maintain attribution* The Google "watermark" you see on each file is essential for informing people about this project and helping them find additional materials through Google Book Search. Please do not remove it.

+ *Keep it legal* Whatever your use, remember that you are responsible for ensuring that what you are doing is legal. Do not assume that just because we believe a book is in the public domain for users in the United States, that the work is also in the public domain for users in other countries. Whether a book is still in copyright varies from country to country, and we can't offer guidance on whether any specific use of any specific book is allowed. Please do not assume that a book's appearance in Google Book Search means it can be used in any manner anywhere in the world. Copyright infringement liability can be quite severe.

About Google Book Search

Google's mission is to organize the world's information and to make it universally accessible and useful. Google Book Search helps readers discover the world's books while helping authors and publishers reach new audiences. You can search through the full text of this book on the web at `http://books.google.com/`

PUBLIC LIBRARY OF THE CITY OF BOSTON.
DEPOSITED IN THE BOSTON MEDICAL LIBRARY

THE FRANCIS A. COUNTWAY
LIBRARY OF MEDICINE
BOSTON, MA

SEP 03 2003

TRANSACTIONS

OF THE

PATHOLOGICAL SOCIETY OF LONDON.

* 7786.3
v.34.
1882-83.

VOLUME THE THIRTY-FOURTH.

COMPRISING THE REPORT OF THE PROCEEDINGS FOR THE SESSION 1882-83.

THE FRANCIS A. COUNTWAY
LIBRARY OF MEDICINE
BOSTON, MA

SEP 03 2003

LONDON:
SMITH, ELDER & CO., 15, WATERLOO PLACE.
1883.

B. M.
343.269
March 1, 1884

THE present publication, being the Thirty-fourth Volume of Transactions, constitutes the Thirty-seventh published Annual Report of the Pathological Society's Proceedings.

The COUNCIL think it right to repeat that the exhibitors are alone responsible for the descriptions given of the Specimens exhibited by them, the only change made in the Reports furnished by the authors being such verbal alterations as were absolutely necessary.

53, BERNERS STREET, OXFORD STREET:
October, 1883.

TABLE OF CONTENTS

OF VOLUME XXXIV.

	PAGE
List of Presidents of the Society	iv
List of Officers and Members for 1883	v—xxxv
Annual Report of Council for 1882	xxxvii
List of Specimens Exhibited during the Session 1882–83	xliii
List of Specimens Reported on by the Committee on Morbid Growths	liv
List of Plates	lv
List of Woodcuts	lvii
Diseases, etc., of the Nervous System	1
Diseases, etc., of the Organs of Respiration	19
Diseases, etc., of the Organs of Circulation	29
Diseases, etc., of the Organs of Digestion	79
Diseases, etc., of the Genito-Urinary Organs	138
Diseases, etc., of the Osseous System	185
Diseases, etc., of the Organs of Special Sense	230
Morbid Growths and Tumours	233
Diseases, etc., of Spleen, Supra-Renal Capsules, and Thyroid	270
Diseases of the Skin	272
Miscellaneous Specimens	291
Diseases, etc., of the Lower Animals	308
Discussion upon the Morbid Anatomy of Diabetes	328
Index	399

Presidents of the Society.

ELECTED	
1846	CHARLES J. B. WILLIAMS, M.D., F.R.S.
1848	CHARLES ASTON KEY.
1850	PETER MERE LATHAM, M.D.
1852	CÆSAR H. HAWKINS, F.R.S.
1853	BENJAMIN GUY BABINGTON, M.D., F.R.S.
1855	JAMES MONCRIEFF ARNOTT, F.R.S.
1857	Sir THOMAS WATSON, Bart., M.D., F.R.S.
1859	Sir WILLIAM FERGUSSON, Bart., F.R.S.
1861	JAMES COPLAND, M.D., F.R.S.
1863	Sir PRESCOTT G. HEWETT, Bart., F.R.S.
1865	THOMAS BEVILL PEACOCK, M.D.
1867	JOHN SIMON, D.C.L., F.R.S.
1869	RICHARD QUAIN, M.D., F.R.S.
1871	JOHN HILTON, F.R.S.
1873	Sir WILLIAM JENNER, Bart., M.D., K.C.B., D.C.L., F.R.S.
1875	GEORGE D. POLLOCK.
1877	CHARLES MURCHISON, M.D., LL.D., F.R.S.
1879	JONATHAN HUTCHINSON.
1881	SAMUEL WILKS, M.D., F.R.S.
1883	JOHN WHITAKER HULKE, F.R.S.

OFFICERS AND COUNCIL

OF THE

Pathological Society of London,

ELECTED AT

THE GENERAL MEETING, JANUARY 2ND, 1883.

President.

JOHN WHITAKER HULKE, F.R.S.

Vice-Presidents.

WILLIAM BOWMAN, F.R.S.
WILLIAM HENRY BROADBENT, M.D.
THOMAS BUZZARD, M.D.
SIR ANDREW CLARK, BART., M.D.
JOHN CROFT.
ARTHUR EDWARD DURHAM.
JONATHAN HUTCHINSON, F.R.S.
SAMUEL WILKS, M.D., F.R.S.,

Treasurer.

GEORGE JOHNSON, M.D., F.R.S.

Council.

ROBERT BARNES, M.D.
JOHN CAVAFY, M.D.
JOHN CURNOW, M.D.
FREDERICK AKLAR MAHOMED M.D.
JOSEPH FRANK PAYNE, M.D.
GEORGE VIVIAN POORE, M.D.
R. DOUGLAS POWELL, M.D.
FREDERICK THOMAS ROBERTS, M.D.
GEORGE HENRY SAVAGE, M.D.
REGINALD SOUTHEY, M.D.
W. MORRANT BAKER.
WILLIAM HARRISON CRIPPS.
ALBAN H. G. DORAN.
ALFRED PEARCE GOULD.
THOMAS RIDGE JONES, M.D.
JOHN LANGTON.
R. CLEMENT LUCAS.
EDWARD NETTLESHIP.
ROBERT WILLIAM PARKER.
WILLIAM JOHNSON WALSHAM.

Honorary Secretaries.

JAMES FREDERIC GOODHART, M.D.
HENRY MORRIS.

Trustees.

RICHARD QUAIN, M.D., F.R.S.
GEORGE D. POLLOCK.

Members are requested to indicate to the Secretaries corrections when necessary.

LIST OF MEMBERS OF THE SOCIETY.

Honorary Members.

ARNOTT, JAMES MONCRIEFF, F.R.S., Chapel House, Lady Bank, Fifeshire; and 36, Sussex-gardens, Hyde-park, W.

BILLROTH, THEODOR, M.D., Professor of Surgery in the University of Vienna.

BRUECKE, ERNST, M.D., Professor of Physiology in the University of Vienna.

CHARCOT, J. M., M.D., Physician to the "Hôpital de la Salpêtrière," and Professor at the Faculty of Medicine of Paris.

CHAUVEAU, A., M.D., Professor of Physiology at the Medical School of Lyons.

COHNHEIM, JULIUS, M.D., Professor of General Pathology and Pathological Anatomy in the University of Breslau.

DONDERS, FRANZ CORNELIUS, M.D., LL.D., Professor of Physiology and Ophthalmology at the University of Utrecht.

GROSS, SAMUEL D., M.D., D.C.L. Oxon., LL.D., Professor of Surgery in the Jefferson Medical College of Philadelphia.

HELMHOLTZ, H., M.D., Professor of Physiology in the University of Heidelberg.

HENLE, J., M.D., Professor of Anatomy and Physiology in the University of Göttingen.

LUDWIG, C., M.D., Professor of Physiology in the University of Leipzig.

PANUM, PROFESSOR P. L., Copenhagen.

PASTEUR, PROFESSOR L., Member of the Institute, Paris.

RINDFLEISCH, EDOUARD, M.D., Professor of Pathological Anatomy in the University of Bonn.

ROBIN, CHARLES, M.D., Professor of Histology at the Faculty of Medicine of Paris.

THIERSCH, CARL, M.D., Professor of Surgery in the University of Leipzig.

VIRCHOW, RUDOLF, M.D., Professor of Pathological Anatomy in the University of Berlin.

EXPLANATION OF ABBREVIATIONS.

O.M.—Original Member.
Pres.—President.
T.—Treasurer.
V.-P.—Vice-President.
S.—Secretary.
C.—Member of Council.

Those marked thus (†) have paid Composition Fee for Annual Subscription.
Those marked thus (‡) have paid Composition Fee for Transactions.

GENERAL LIST OF MEMBERS.

Elected

1879 ABERCROMBIE, JOHN, M.D., 39, Welbeck-street, Cavendish-square, W.

1858 ACLAND, HENRY WENTWORTH, M.D., F.R.S., Regius Professor of Medicine, University of Oxford, Physician to the Radcliffe Infirmary, Oxford.

1883 ACLAND, THEODORE DYKE, M.B., 79, Palace Road, Lambeth, S.E.

‡1866 ADAMS, ARTHUR BAYLEY.

1869 ADAMS, JAMES EDWARD, Surgeon to the London Hospital; 17, Finsbury-circus, E.C.

O.M. ADAMS, WILLIAM, Consulting Surgeon to the National Orthopædic Hospital; 5, Henrietta-street, Cavendish-square, W. (C. 1851-4. V.-P. 1867-9.)

1859 ADAMS, WILLIAM, Tower Lodge, Regent's-park-road, Gloucester-gate, N.W. (C. 1877-8.)

1848 AIKIN, CHARLES A., 7, Clifton-place, Sussex-square, Hyde-park, W. (C, 1864-6.)

1872 AIKIN, CHARLES EDMUND, 7, Clifton-place, Sussex-square, Hyde-park, W.

1871 AIR, A. CUMMINGS, 316, Kennington-park-road, S.E.

1880 AITKEN, WILLIAM, M.D., F.R.S., Professor of Pathology, Army Medical School, Netley, Southampton; Park Villa, Weston-grove-road, Woolston, Southampton.

1869 ALLBUTT, THOMAS CLIFFORD, M.D., F.R.S., Physician to the Leeds General Infirmary; 35, Park-square, Leeds.

1882 ALLCHIN, WILLIAM HENRY, M.B., Physician to, and Lecturer on Medicine at, the Westminster Hospital; 25, Chandos-street, Cavendish-square, W.

1877 ALTHAUS, JULIUS, M.D., Senior Physician to the Hospital for Epilepsy and Paralysis, Regent's Park; 48, Harley-street, Cavendish-square, W.

1868 ANDERSON, J. FORD, M.D., 28, Buckland-crescent, Belsize-park, N.W.

1880 ANDERSON, JAMES, M.A., M.D., C.M., 84, Wimpole-street, Cavendish-square, W.

1871 ANDERSON, WILLIAM, Assistant Surgeon to, and Lecturer on Anatomy at, St. Thomas's Hospital; 13, Welbeck-street, Cavendish-square, W.

1859 ANDREW, EDWYN, M.D., Hardwick House, St. John's-hill, Shrewsbury.

1863 ANDREW, JAMES, M.D., Physician to St. Bartholomew's Hospital; 22, Harley-street, W. (C. 1868-70.)

1882 AXE, J. WORTLEY, Professor of Pathological Histology and Morbid Anatomy at the Royal Veterinary College; The Mount, Manor-park-road, Willesden.

1863 BAGSHAWE, FREDERICK, M.A., M.D., 16, Warrior-square, Hastings.

1864 BAKER, WILLIAM MORRANT (C.), Assistant Surgeon to, and Lecturer on Physiology at, St. Bartholomew's Hospital; 26, Wimpole-street, Cavendish-square, W. (C. 1873-6, 1881-3. S. 1878-80.)

Elected

‡1856 BALDING, DANIEL BARLEY, Royston, Herts.

1880 BALL, BENJAMIN, Professeur à la Faculté de Médecine de Paris, Médecin en Chef de la Clinique des Maladies Mentales; rue du Faubourg St. Honoré, 8, Paris.

1881 BALLANCE, CHARLES A., M.S., St. Thomas's Hospital; 56, Harley-street, W.

1851 BARCLAY, A. WHYTE, M.D., Consulting Physician to St. George's Hospital; Whitney-wood, Stevenage. (C. 1858-61.)

1875 BARKER, ARTHUR E. J., Assistant Surgeon and Assistant Teacher of Clinical Surgery, University College Hospital; 87, Harley-street, Cavendish-square, W.

1874 BARLOW, THOMAS, M.D., B.S., Assistant Physician to University College Hospital and to the Children's Hospital, Great Ormond-street; 10, Montague-street, Russell-square, W.C. (C. 1879-81.)

1871 BARNES, ROBERT, M.D. (C.), Obstetric Physician to St. George's Hospital; 15, Harley-street, Cavendish-square, W. (C. 1883.)

1862 BARRATT, JOSEPH GILLMAN, M.D., Accoucheur to the St. George's and St. James's Dispensary; 8, Cleveland-gardens, Bayswater, W.

1877 BARROW, A. BOYCE, Assistant Surgeon to the Westminster Hospital; 17, Welbeck-street, Cavendish-square, W.

1881 BARRS, ALFRED GEORGE, M.B., General Infirmary, Leeds.

1879 BARTLETT, HENRY, M.D., 171, Loughboro'-road, Stockwell, S.W.

1853 BARWELL, RICHARD, Surgeon to, and Lecturer on Surgery at, the Charing Cross Hospital; 32, George-street, Hanover-square, W. (C. 1862-4.)

1861 BASTIAN, H. CHARLTON, M.A., M.D., F.R.S., Professor of Pathological Anatomy in University College, and Physician to University College Hospital; 20, Queen Anne-street, W. (C. 1869-71.)

1877 BATEMAN, ARTHUR W., B.A., Tenterfield, New South Wales.

†1876 BATTESON, JOHN, Medical Officer of the Royal Humane Society; 1, Coborn-place, Bow-road, E.

1882 BATTLE, WILLIAM HENRY, 65, Lambeth Palace-road, S.E.

1870 BÄUMLER, CHRISTIAN G. H., M.D., Professor of Materia Medica in the University of Erlangen.

1871 BAXTER, EVAN BUCHANAN, M.D., Professor of Materia Medica, King's College, London, and Physician to King's College Hospital; 28, Weymouth-street, Portland-place, W. (C. 1880-2.)

1874 BEACH, FLETCHER, M.B., Metropolitan District Asylum, Darenth, near Dartford, Kent.

1879 BEALE, EDWIN CLIFFORD, M.B., 23, Upper Berkeley-street, Portman-square, W.

1852 BEALE, LIONEL S., M.B., F.R.S., Professor of Medicine at King's College, Physician to King's College Hospital; 61, Grosvenor-street, W. (C. 1858-9. V.-P. 1874-5.)

1856 BEALEY, ADAM, M.D., M.A., Oak-lea, Harrogate.

†1878 BEANEY, JAMES GEORGE, Senior Surgeon to the Melbourne Hospital Melbourne, Victoria.

Elected

1870 Beck, Marcus, M.S., Assistant Surgeon to University College Hospital; 30, Wimpole-street, Cavendish-square, W. (C. 1875-7.)

1865 Beeby, Walter, M.D., Bromley, Kent.

†1880 Beevor, Charles Edward, M.B., 129, Harley-street, Cavendish-square.

1875 Bell, H. Royes, Surgeon to King's College Hospital; 12, Queen Anne-street, Cavendish-square, W.

1865 Bellamy, Edward, Surgeon to the Charing Cross Hospital; 17, Wimpole street, Cavendish-square, W. (C. 1876-8.)

1883 Bendall, Howard, M.D., 9, Titchfield-terrace, Regent's-park.

1883 Benham, Robert Fitzroy, Abercorn House, Baron's-court, S.W.

1847 Bennet, James Henry, M.D., Weybridge, Surrey.

1877 Bennett, William Henry, Assistant Surgeon to St. George's Hospital, Surgeon to the Belgrave Hospital for Children; 4, Chesterfield-street, Mayfair.

1878 Bernard, Francis W., M.D., Medical Superintendent, Stockwell Small-pox Hospital, Stockwell, S.W.

1882 Berridge, William Alfred, Redhill, Surrey.

‡1856 Bickersteth, Edward R., Surgeon to the Liverpool Royal Infirmary; 2, Rodney-street, Liverpool.

1882 Bindley, Philip Henry, M.B., Roccabruna, Branksome Wood-road, Bournemouth.

1878 Bindon, William John Vereker, M.D.

1850 Birkett, Edmund Lloyd, M.D., Consulting Physician to the City of London Hospital for Diseases of the Chest; 48, Russell-square, W.C. (C. 1856-7.)

O.M. Birkett, John, Consulting Surgeon to Guy's Hospital; 59, Green-street, Grosvenor-square, W. (C. 1851. V.-P. 1860-2.)

1881 Biss, Cecil Yates, M.B., Assistant Physician to the Middlesex Hospital, Assistant Physician to the Hospital for Consumption, Brompton; 65, Harley-street, Cavendish-square, W.

1865 Bisshopp, James, Bedford-place, Tunbridge Wells.

1853 Black, Cornelius, M.D., Physician to the Chesterfield Dispensary, St. Mary's-gate, Chesterfield.

1877 Black, James, 16, Wimpole-street, Cavendish-square, W.

1850 Blagden, Robert, Stroud, Gloucestershire.

1863 Blanchet, Jean B., M.D., M.S., Montreal, Quebec, Canada.

1876 Blasson, William, Edgeware, Middlesex.

1879 Boileau, J. P. H., M.D., Surgeon-Major, Army Medical Department; Assistant Professor of Pathology, Netley School of Medicine, Netley.

1876 Bond, Thomas, M.B., Assistant Surgeon and Lecturer on Forensic Medicine to Westminster Hospital; 7, Broad Sanctuary, Westminster, S.W.

1869 Bourne, Walter, M.D.

1880 Bowen, Alfred Longmore, 10, Lewisham-lower-road, S.E.

1861 Bowes, Richard Norris, 14, Doughty-street, Mecklenburg-square, W.C

1881 Bowlby, Anthony A., St. Bartholomew's Hospital; 75, Warrington-crescent, Maida Vale, W.

Elected

1851 BOWMAN, WILLIAM, F.R.S., (V.P.) Surgeon to the Royal Ophthalmic Hospital; 5, Clifford-street, Bond-street, W. (C. 1855-6. V.P. 1882-3.)

1882 BOYD, STANLEY, M.B., Assistant Surgeon to Charing Cross Hospital; 62, Guilford-street, Russell-square, W.C.

1879 BRAILEY, WM. ARTHUR, M.D., Lecturer on Comparative Anatomy at St. George's and Guy's Hospitals, Assistant Ophthalmic Surgeon to Guy's Hospital; 16, Orchard-street, Portman-square, W.

1880 BRAMWELL, BYROM, M.D., 4, Drumsheugh-gardens West, Edinburgh.

1877 BRIDGES, ROBERT, M.B., M.A. Oxford, Manor House, Yattendon, Berks.

‡1867 BRIDGEWATER, THOMAS, M.B. Lond., Harrow-on-the-hill, Middlesex.

1873 BRIGGS, JACOB MYERS, M.D., Coeymans, New York, U.S.

1868 BRIGHT, G. C., M.B., Cannes, France.

1857 BRISCOE, JOHN, 12, Broad-street, Oxford.

†1851 BRISTOWE, JOHN S., M.D., F.R.S., Physician to, and Lecturer on the Theory and Practice of Medicine at, St. Thomas's Hospital; 11, Old Burlington-street, W. (C. 1854-8. S. 1861-4. C. 1865-7. V.-P. 1868-76.)

1860 BROADBENT, WILLIAM HENRY, M.D. Lond., (V.P.) Physician to St. Mary's Hospital, and Consulting Physician to the London Fever Hospital; 34, Seymour-street, Portman-square, W. (C. 1871-3. V.P. 1882-3.)

1877 BROCKMAN, E. F., Madras Medical Service [care of Mr. Lewis, Gower-street.]

1852 BRODHURST, BERNARD E., Surgeon to the Royal Orthopædic Hospital; 20, Grosvenor-street, W. (C. 1862-4.)

1863 BRODIE, GEORGE BERNARD, M.D., Consulting Physician-Accoucheur to Queen Charlotte's Hospital; 3, Chesterfield-street, Mayfair, W.

1865 BROWN, AUGUSTUS, M.D., 38, Arundel-square, Islington, N.

1871 BROWN, FREDERICK GORDON, 16, Finsbury-circus, E.C.

1875 BROWNE, GEORGE BUCKSTON, 80, Wimpole-street, Cavendish-square, W.

1866 BROWNE, LENNOX, Surgeon to the Central Throat and Ear Hospital, and to the Royal Society of Musicians; 36, Weymouth-street, Portland-place, W.

O.M. BROWNE, JOSEPH HULLETT, M.D., late Physician to the St. Pancras Royal General Dispensary; Ridgeway House, near Southampton. (C. 1859-60.)

1877 BRUCE, J. MITCHELL, M.D., Assistant Physician to Charing Cross Hospital and to the Hospital for Consumption, Brompton; 70, Harley-street, Cavendish-square, W.

1855 BRYANT, THOMAS, Surgeon to Guy's Hospital; 53, Upper Brook-street, Grosvenor-square, W. (C. 1863-6. V.-P. 1877-79.)

1854 BUCHANAN, GEORGE, M.D., F.R.S., Medical Officer of the Local Government Board, 24, Nottingham-place, Marylebone-road, W. (C. 1864-6. V.-P. 1880-82.)

1862 BUCHANAN, ALBERT, M.B. Lond., 364, Camden-road, N.

Elected

1878 BURNET, ROBERT WILLIAM, M.D., 94, Wimpole-street, Cavendish-square, W.

1853 BURTON, JOHN M., Lee-park Lodge, Lee, Kent, S.E.

1880 BURTON, SAMUEL HERBERT, M.B., Norfolk and Norwich Hospital, Norwich.

1872 BUTLIN, HENRY TRENTHAM, Assistant Surgeon to, and Demonstrator of Practical Surgery and of Disease of the Larynx at, St. Bartholomew's Hospital; 47, Queen Anne-street, W. (C. 1876-8.)

1866 BUTT, WILLIAM FREDERICK, 25, Park-street, Park-lane, W.

1883 BUXTON, DUDLEY W., M.B., 99, Gower-street, W.C.

1856 BUZZARD, THOMAS, M.D. (V.-P.), Physician to the National Hospital for the Epileptic and Paralysed; 56, Grosvenor-street, W. (C. 1869-70. V.-P. 1881-3.)

†O.M. CAMPS, WILLIAM, M.D., 53, Radnor-street, Chelsea, S.W. (C. 1856-9.)

‡1855 CARPENTER, ALFRED, M.D., High-street, Croydon.

1879 CARRINGTON, ROBERT E., M.D., Medical Registrar at Guy's Hospital; 15, St. Thomas's-street, S.E.

1871 CARTER, CHARLES HENRY, M.D., B.S. Lond., Physician to the Hospital for Women, 45; Great Cumberland-place, Hyde-park, W.

1855 CARTER, H. VANDYKE, M.D., Professor of Anatomy and Physiology, Grant Medical College, Bombay.

1876 CARTER, ROBERT BRUDENELL, Ophthalmic Surgeon to, and Lecturer on Ophthalmic Surgery at, St. George's Hospital; 27, Queen Anne-street, Cavendish-square, W.

1879 CASSIDY, JOSEPH LAMONT, M.D., 82, Guilford-street, Russell-square, W.C.

1877 CASSON, JOHN HORNSBY.

†1868 CAVAFY, JOHN, M.D. (C.), Physician to St. George's Hospital; 2, Upper Berkeley-street, Portman-square, W. (C. 1881-3.)

1864 CAY, CHARLES VIDLER.

1863 CAYLEY, WILLIAM, M.D., Physician to, and Lecturer on the Principles and Practice of Medicine at, the Middlesex Hospital; 27, Wimpole-street, Cavendish-square, W. (C. 1870-1, 1875-8. S. 1872-4.)

1869 CHAFFERS, EDWARD, Keighley, Yorkshire.

1849 CHALK, WILLIAM OLIVER, 3, Nottingham-terrace, Regent's-park, N.W. (C. 1856-7.)

1876 CHARLES, T. CRANSTOUN, M.D., M.C., Lecturer on Practical Physiology at St. Thomas's Hospital; Cookstown, Co. Tyrone, Ireland, and Crofton Lodge, Hopton-road, Coventry-park, Streatham, S.E.

1870 CHEADLE, WALTER BUTLER, M.D., Physician (with charge of Out-patients) to St. Mary's Hospital, and Physician to the Hospital for Sick Children, Great Ormond-street; 2, Hyde-park-place, Cumberland-gate, W. (C. 1882.)

Elected

*1879 Cheyne, William Watson, M.B., C.M., Assistant Surgeon to King's College Hospital; 14, Mandeville-place, Manchester-square, W.

1858 Child, Gilbert W.

1873 Chisholm, Edwin, M.D., Abergeldie, Ashfield, near Sydney, New South Wales.

1855 Cholmeley, William, M.D., Physician to the Great Northern Hospital and to the Margaret-street Infirmary for Consumption; 63, Grosvenor-street, W. (C. 1871-3.)

1871 Christie, Thomas Beath, M.D., Superintendent of the Royal India Asylum, Ealing, Middlesex.

1865 Church, William Selby, M.D., Physician to St. Bartholomew's Hospital; 130, Harley-street, Cavendish-square, W. (C. 1871-3.)

†1868 Churchill, Frederick, M.B., Surgeon to the Victoria Hospital for Children; 4, Cranley-gardens, Queen's-gate, S.W.

1861 Clapton, Edward, M.D., 10A, St. Thomas's-street, Southwark, S.E.

1854 Clark, Sir Andrew, Bart., M.D., LL.D. Aberd. (V.-P.), Physician to the London Hospital; 16, Cavendish-square, W. (C. 1862-5. V.-P. 1881-3.)

1872 Clark, Andrew, Assistant Surgeon to the Middlesex Hospital; 19, Cavendish-place, W.

1883 Clarke, Ernest, M.B., B.S., 21, Lee-terrace, Blackheath, S.E.

1881 Clarke, W. Bruce, M.B., 46, Harley-street, Cavendish-square, W.

1867 Clarke, William Fairlie, M.A., M.D., Southborough, Tunbridge Wells. (C. 1873-5.)

1875 Clarkson, John, Surgeon in the India Department, Bombay Presidency, India.

1875 Clutton, Henry Hugh, M.A., Assistant Surgeon to St. Thomas's Hospital; 77, Lambeth-palace-road, S.E.

‡1865 Coates, Charles, M.D., Physician to the Bath General and Royal United Hospitals; 10, Circus, Bath.

1856 Cockle, John, M.D., M.A., Physician to the Royal Free Hospital; 13, Spring-gardens, Charing-cross, S.W.

Colley, see Davies-Colley.

1879 Collins, Wm. Maunsell, M.D., Surgeon, Scots Guards; 70A, Grosvenor-street, W.

1878 Collyns, R. T. Poole, Atkinson Morley Hospital, Copse-hill, Wimbledon.

1882 Colquhoun, Daniel, M.D. (Abroad)

1882 Compton, Francis Charles, L.R.C.P., Ed., 38, Hans-place, S.W.

1858 Cooke, R. T. E. Barrington, Consulting Surgeon to the Scarborough Dispensary, Consulting Surgeon to the Royal Northern Sea-Bathing Infirmary; 15, St. Nicholas-cliff, Scarborough, Yorkshire.

1871 Cooke, Thomas, Assistant Surgeon to the Westminster Hospital; 16, Woburn-place, W.C.

1866 Coombs, Rowland Hill, Mill-street, Bedford.

Elected

1879 COOPER, ARTHUR, 2, Stafford-street, Old Bond-street, W.

1853 CORNISH, WILLIAM ROBERT, Surgeon-Major, Madras Army, Sanitary Commissioner for Madras.

1875 COEY, ROBERT, M.D., Assistant Obstetric Physician to St. Thomas's Hospital; 73, Lambeth Palace-road, S.E.

1876 COTTLE, ERNEST WYNDHAM, M.A., Assistant Surgeon to the Hospital for Diseases of the Skin, Blackfriars; 3, Savile-row.

†1861 COUPER, JOHN, Surgeon to the London Hospital; 80, Grosvenor-street, Grosvenor-square, W. (C. 1870-2.)

1873 COUPLAND, SIDNEY, M.D., Physician to, and Lecturer on Pathological Anatomy at, the Middlesex Hospital; 14, Weymouth-street, Portland-place. (C. 1878-81.)

1882 COXWELL, CHARLES FILLINGHAM, M.B., Hospital for the Paralysed and Epileptic, Queen's-square, W.C.

1881 CREIGHTON, CHARLES, M.D., (C.), 6, Queen Anne-street, Cavendish-square, W.

1873 CRIPPS, WILLIAM HARRISON, Surgical Registrar to St. Bartholomew's Hospital; 6, Stratford-place, Oxford-street, W. (C. 1883)

1877 CROCKER, HENRY RADCLIFFE, M.D., Physician to the Skin Department, University College Hospital; Assistant Physician and Pathologist to the East London Hospital for Children; 28, Welbeck-street, Cavendish-square, W.

1856 CROFT, JOHN (V.-P.), Surgeon to St. Thomas's Hospital; 48, Brook-street Grosvenor-square, W. (C. 1870-2. V.-P. 1882-3)

1879 CROOKE, GEORGE FREDERICK, M.B. [Gainsborough, Lincolnshire.], Leeds Fever Hospital, Leeds.

1861 CROSBY, THOMAS BOOR, M.D., 21, Gordon-square, W.C.

1875 CROSS, FRANCIS RICHARDSON, 5, The Mall, Clifton, Bristol.

1871 CUMBERBATCH, ELKIN, Aural Surgeon at St. Bartholomew's Hospital; 17, Queen Anne-street, W.

1858 CUMBERBATCH, LAURENCE T., M.D., 25, Cadogan-place, Sloane-street, S.W.

1873 CURNOW, JOHN, M.D. (C.), Professor of Anatomy at King's College, and Assistant Physician to King's College Hospital; 3, George-street, Hanover-square, S.W. (C. 1882-3.)

‡1865 CURRAN, WILLIAM, M.D., Army Medical Staff. [Agent: Mr. H. K. Lewis 136, Gower-street, W.C.]

1873 DAVIDSON, ALEXANDER, M.D., Physician to the Liverpool Royal Infirmary Lecturer on Pathology at the Liverpool Medical School; 2, Gambier-terrace, Liverpool.

1869 DAVIES-COLLEY, J. NEVILLE C., M.B. Surgeon to Guy's Hospital 36, Harley-street, Cavendish-square. (C. 1880-82.)

Elected

O.M. Davies, Herbert, M.D., Consulting Physician to the London Hospital, and to the Infirmary for Asthma; 23, Finsbury-square, E.C. (C 1849-50. V.-P. 1871.)

1883 Davis, E. H., Erleigh, near Reading.

‡1859 Davis, Francis William, R.N., Surgeon to the Naval Medical Establishment, Lisbon. [Agents: Messrs. Hallett and Co., 7, St. Martin's-place, Trafalgar-square, W.C.]

1879 Davy, Henry, M.D., Physician to the Devon and Exeter Hospital; 34, Southernhay, Exeter.

1866 Day, William Henry, M.D., Physician to the Samaritan Free Hospital for Women and Children; 10, Manchester-square, W.

1872 Decastro, James C., M.B. [Pau, France.]

1871 De Liefde Temple, John, M.D. [per Mr. James Nimmo, 7, Red Lion-court, Watling-street, E.C.].

1880 Dent, Clinton T., Assistant Surgeon to St. George's Hospital; 19, Savile-row, W.

1863 Devereux, Daniel, Tewkesbury, Gloucestershire.

1856 Dick, H., M.D.

1871 Dickinson, Edward Harriman, M.A. Oxon., M.D., Physician to the Liverpool Northern Hospital, and Lecturer on Comparative Anatomy at the Liverpool School of Medicine; 162, Bedford-street, Liverpool.

1858 Dickinson, William Howship, M.D., Physician to the Hospital for Sick Children, Physician and Lecturer on Medicine to St. George's Hospital; 9, Chesterfield-street, Mayfair, W. (C. 1866-8. S. 1869-71. V.-P. 1872-4.)

1872 Diver, Ebenezer, M.D., Kenley, Caterham-valley, Surrey.

O.M. Dixon, James, Consulting Surgeon to the Royal Ophthalmic Hospital, Moorfields; Harrowlands, Dorking, Surrey. (C. 1852-6. V.-P. 1860-2.)

1872 Doran, Alban Henry Griffiths, (C.) Surgeon to Out-Patients, Samaritan Hospital; 51, Seymour-street, Portman-square, W. (C. 1882-83.)

†1866 Down, John Langdon H., M.D., Physician to, and Lecturer on Clinical Medicine at, the London Hospital; 81, Harley-street, Cavendish-square, W. (C. 1872-4.)

1872 Dowse, Thomas Stretch, M.D., 14, Welbeck-street, Cavendish-square.

1880 Dreschfeld, Julius, M.D., Physician to the Manchester Infirmary; 292, Oxford-road, Manchester.

1879 Drewitt, F. G. Dawtrey, M.D., 52, Brook-street, Grosvenor-square.

1865 Duckworth, Dyce, M.D., Assistant Physician to St. Bartholomew's Hospital; 11, Grafton-street, Bond-street, W. (C. 1877.)

1863 Dudfield, Thomas Orme, M.D., 8, Upper Phillimore-place, Kensington, W.

1847 Dudgeon, Robert E., M.D., 53, Montagu-square, W.

1852 Duff, George, M.D., High-street, Elgin.

Elected

1865 DUFFIN, ALFRED BAYNARD, M.D., Physician to King's College Hospital; 18, Devonshire-street, Portland-place, W. (C. 1872-4.)

1875 DUKA, THEODORE, M.D., Surgeon-Major, H.M.'s Bengal Army; (Abroad).

1868 DUKE, OLIVER THOMAS, M.B., India.

1871 DUKES, CLEMENT, M.D., B.S. Lond., Physician to Rugby School; Sunnyside, Rugby.

1877 DUNBAR, J. J. MACWHIRTER, M.D., Assistant House-Physician to St. George's Hospital; Argyle House, Clapham-common, S.W.

1877 DUNCAN, ANDREW, M.D., 8, Henrietta-street, Covent-garden, W.C.

1880 DUNCAN, JAS. MATTHEWS, M.D., Obstetric Physician to St. Bartholomew's Hospital; 71, Brook-street, Grosvenor-square, W.

1861 DUNN, ROBERT WILLIAM, 13, Surrey-street, Strand, W.C., and 29, Morgate-street, E.C.

1858 DURHAM, ARTHUR EDWARD (V.-P.), Surgeon to Guy's Hospital; 82, Brook-street, Grosvenor-square, W. (C. 1869-71. V.P. 1883)

1879 DURHAM, FREDERIC, M.B., 38, Brook-street, Grosvenor-square, W.

1880 EDMUNDS, WALTER, M.D., 79, Lambeth Palace-road, S.E.

1882 EDWARDES, EDWARD JOSHUA, M.D., 17, Orchard-street, Portman-square, W.

1882 EDWARDS, F. SWINFORD, Assistant Surgeon to the West London Hospital; 93, Wimpole-street, Cavendish-square, W.

1883 ELDER, GEORGE, M.D., Surgeon to the Hospital for Women; 17, Regent-street, Nottingham.

1867 ELLIS, JAMES, M.D., California.

1882 ELLISON, JOHN CLEMENT, 10, Clarence-road, Wood-green, Middlesex, N.

1873 ENGELMANN, GEORGE JULIUS, M.D., A.M., 3003, Locust-street, St. Louis, Miss., U.S.

1846 ERICHSEN, JOHN ERIC, F.R.S., Consulting Surgeon to University College Hospital; 6, Cavendish-place, Cavendish-square, W. (C. 1849-51. V.-P. 1863-4.)

1853 EVANS, CONWAY, M.D., The Garden House, Clement's-inn, W.C. (C. 1867-8.)

1875 EVANS, JULIAN, A.M., M.D., Physician to the Victoria Hospital for Children; 123, Finboro'-road, Redcliffe-square, West Brompton, S.W.

1879 EVE, FREDERIC S., Pathological Curator of the Museum, Royal Coll. Surgeons of England, and Surgical Registrar to St. Bartholomew's Hospital; 14, Furnival's Inn, Holborn, W.C.

1876 EWART, JAMES COSSAR, M.B., C.M., School of Medicine, Edinburgh.

1881 EWART, JOSEPH, M.D., late Professor of Medicine at Calcutta Medical College; Montpellier Terrace, Brighton.

1877 EWART, WILLIAM, M.B., Assistant Physician to and Lecturer on Physiology at St. George's Hospital; 33, Curzon-street, Mayfair, W.

‡1859 EWENS, JOHN, Cotham Brow, Bristol.

Elected

1864 FAGGE, CHARLES HILTON, M.D., Physician to, and Lecturer on Pathology at, Guy's Hospital; 76, Grosvenor-street, W. (C. 1870-2.)

1872 FAYRER, Sir JOSEPH, K.C.S.I., M.D. F.R.S. Ed., Hon. Physician to the Queen, Surgeon-Major, Bengal Army, Examining Medical Officer to the Secretary of State for India in Council; 53, Wimpole-street, Cavendish-square, W. (C. 1880-2.)

1872 FENN, EDWARD L., M.B., The Old Palace, Richmond, Surrey.

1880 FENWICK, BEDFORD, M.D., Assistant Physician to the City of London Hospital for Diseases of the Chest; 6, West-street, Finsbury-circus, E.C.

1872 FENWICK, JOHN C. J., M.D., Physician to the Durham County Hospital; Chilton Hall, Ferry-hill, and 16, Old Elvet, Durham.

1863 FENWICK, SAMUEL, M.D., Physician to the London Hospital; 29, Harley-street, W.

1846 FINCHAM, GEORGE T., M.D., Physician to the Westminster Hospital; 13, Belgrave-road, S.W. (C. 1855.)

1876 FINLAY, DAVID W., M.D., Assistant Physician to the Middlesex Hospital; 21, Montagu-street, Portman-square, W.

1870 FISH, JOHN CROCKETT, M.D., 92, Wimpole-street, W.

1859 FISHER, ALEXANDER, M.D., Assistant Surgeon R.N., Her Majesty's Ship "Endymion."

1882 FLEMING, GEORGE, M.R.C.V.S., Cathcart Lodge, Tyrwhitt-road, St. John's, S.E.

1855 FLOWER, WILLIAM H., F.R.S., President of the Zoological Society, Conservator of the Museum, Royal College of Surgeons; 39, Lincoln's-inn-fields, W.C. (C. 1862-4.)

1872 FORBES, DANIEL MACKAY, L.R.C.P. Ed., 204, Hoxton-street, N.

†O.M. FORSTER, JOHN COOPER, 29, Upper Grosvenor-street, W. (C. 1857-8. V.-P. 1871-3.)

‡1866 FOSTER, BALTHAZAR WALTER, M.D., Physician to the General Hospital, Birmingham; 16, Temple-row, Birmingham.

1872 FOTHERBY, HENRY J., M.D., Physician to the Metropolitan Free Hospital; 3, Finsbury-square, E.C.

1880 FOWLER, JAMES KINGSTON, B.A., M.B., Assistant Physician to the Middlesex Hospital, and Assistant Physician to the Hospital for Consumption, Brompton; 35, Clarges-street, Piccadilly, W.

1878 FOX, THOMAS COLCOTT, M.B., B.A., 14, Harley-street, Cavendish-square, W.

1862 FOX, WILSON, M.D., Holme Professor of Clinical Medicine in University College, and Physician to University College Hospital; 67, Grosvenor-street, W. (C. 1868-70. V.-P. 1875-77.)

1858 FRANCIS, CHARLES RICHARD, M.B., Bengal Medical Establishment, Indian Army.

O.M. FRERE, J. C.

1864 FRODSHAM, JOHN MILL, M.D., Streatham, S.W.

Elected

1880 Gabbett, Henry Singer, M.B., Assistant Physician to the City Road Hospital for Diseases of the Chest, 57, Queen Anne-street, Cavendish-square, W.

‡1858 Gairdner, William Tennant, M.D., Professor of Medicine in the University of Glasgow; 225, St. Vincent-street, Glasgow.

1870 Galton, Edmund H., Springfield House, Brixton-hill, S.W.

1870 Galton, John H., M.D., 39, Anerley-road, Upper Norwood, S.E.

1855 Gamgee, Joseph Sampson, Consulting Surgeon to the Queen's Hospital, Birmingham; 20, Broad-street, Birmingham.

1855 Gamgee, J.

1877 Garlick, George, M.D., 33, Great James-street, Bedford-row, W.C.

1846 Garrod, Alfred Baring, M.D., F.R.S., Consulting Physician to King's College Hospital; 10, Harley-street, Cavendish-square, W (C. 1851. V.-P. 1863-5.)

1879 Garstang, Thomas Walter Harropp, Oakleigh, Dobcross, Manchester.

1872 Garton, William, M.D., Hardshaw-street, St. Helen's, Lancashire.

O.M. Gay, John, Senior Surgeon to the Great Northern Hospital; 34, Finsbury-place, E.C. (C. 1852-4. V.-P. 1870-2.)

1880 Gibbes, Heneage, M.B., Lecturer on Physiology at the Westminster Hospital, 94, Gower-street, Bedford-square, W.

1853 Gibbon, Septimus, M.D., 39, Oxford-terrace, Hyde-park, W.

1878 Gibbons, R. A., M.D., 32, Cadogan-place, S.W.

1876 Gill, John, M.D., Newton Abbot, Devon.

1881 Glynn, Thomas Robinson, M.D., Physician to the Liverpool Royal Infirmary; 62, Rodney-street, Liverpool.

1873 Godlee, Rickman John, M.B., B.S., Assistant Surgeon to University College Hospital; Demonstrator of Anatomy in University College; 81, Wimpole-street, Cavendish-square, W. (C. 1877-80.)

1875 Godson, Clement, M.D., Assistant Physician-Accoucheur to St. Bartholomew's Hospital; 9, Grosvenor-street, W.

1879 Godwin, Charles Henry Young, Surgeon Major, Army; 23, The Common, Woolwich.

1878 Golding-Bird, Cuthbert H., M.B., Assistant Surgeon to Guy's Hospital; 13, St. Thomas's-street, S.E.

1871 Goodhart, James Frederic, M.D. (Hon. Secretary), Assistant Physician to, and Curator of the Museum at, Guy's Hospital; Physician to the Evelina Hospital for Sick Children; 25, Weymouth-street, Portland-place, W. (C. 1876-8. S. 1883.)

1875 Gould, Alfred Pearce, M.S. (C.), Assistant Surgeon to the Middlesex Hospital, Surgeon to the North-west London Hospital; 16, Queen Anne-street, W. (C. 1883.)

1870 Gowers, William Richard, M.D. (C.), Assistant Physician to University College Hospital; 50, Queen Anne-street, Cavendish-square, W. (C. 1878-9.)

1858 Gowland, Peter Y., Surgeon to St. Mark's Hospital; 34, Finsbury-square, E.C.

Elected

1867 GREEN, T. HENRY, M.D. (C.), Physician to Charing Cross Hospital, Assistant Physician to the Hospital for Consumption, Brompton; 74, Wimpole-street, W. (C. 1871-3, 1878-9. S. 1875-6.)

1873 GREENFIELD, WILLIAM SMITH, M.D., B.S., Professor of General Pathology in the University of Edinburgh; 7, Heriot-row, Edinburgh. (C. 1877-80.)

‡1855 GREENHILL, WILLIAM ALEXANDER, M.D., Carlisle-parade, Hastings.

1863 GREENHOW, EDWARD HEADLAM, M.D., F.R.S., Consulting Physician to the Middlesex Hospital; Castle Lodge, Reigate. (C. 1867-9. V.-P. 1877-8.)

1876 GRIFFITHS, THOMAS D., M.D., Hearne Lodge, Swansea.

1882 GROSS, CHARLES, St. Saviour's Infirmary; Walworth, S.E.

1861 GUENEAU DE MUSSY, HENRI, M.D., 15, Rue du Cirque, Paris.

1863 GULL, SIR WILLIAM WITHEY, Bart., M.D., D.C.L., F.R.S., Consulting Physician to Guy's Hospital; 74, Brook-street, Grosvenor-square, W.

1881 GULLIVER, GEORGE, M.B., Assistant Physician to St. Thomas's Hospital, 75, Lambeth Palace-road, S.E.

1880 GUNN, R. MARCUS, M.B., C.M., 108, Park-street, Grosvenor-square, W.

1876 GWYTHER, JAMES, M.B. Lond., St. Mary Church, Torquay.

1849-59 HABERSHON, SAMUEL OSBORNE, M.D., 70, Brook-street, Grosvenor-square, W. (Re-elected 1874.) (C. 1855-6.)

1851 HACON, E. DENNIS, 269, Mare-street, Hackney, N.E. (C. 1872.)

1879 HADDEN, WALTER BAUGH, M.D., Demonstrator of Morbid Anatomy at St. Thomas's Hospital; 21, Welbeck-street, W.

1882 HAIG, A., M.B., 30, Welbeck-street, Cavendish-square, W.

1877 HALLOWES, FREDERICK BLACKWOOD, Redhill, Surrey.

1882 HARBINSON, ALEXANDER, M.D., County Lunatic Asylum, Lancaster.

1848 HARE, CHARLES JOHN, M.D., late Physician to University College Hospital, Berkeley House, 15, Manchester Square, W. (C. 1852-4. V.-P. 1874-7.)

†1856 HARLEY, GEORGE, M.D., F.R.S., 25, Harley-street, Cavendish-square, W. (C. 1862-5. V.-P. 1878-80.)

1872 HARRIS, HENRY, M.D., Trengweath-place, Redruth, Cornwall.

1879 HARRIS, VINCENT DORMER, M.D., Casualty Physician to St. Bartholomew's Hospital; 39, Wimpole-street, Cavendish-square, W.

†1858 HART, ERNEST, 38, Wimpole-street, Cavendish-square, W. (C. 1867-8.)

1870 HAWARD, JOHN WARRINGTON, Surgeon to St. George's Hospital; 16, Savile-row, W. (C. 1879-81.)

O.M. HAWKINS, CÆSAR H., F.R.S., Consulting Surgeon to St. George's Hospital; 26, Grosvenor-street, W. (V.-P. 1846-51. *Pres.* 1852-3.)

1857 HAWKSLEY, THOMAS, M.D., Physician to the Margaret-street Dispensary for Consumption; 31, Grosvenor-street, W.

1856 HEATH, CHRISTOPHER, Holme Professor of Clinical Surgery in University College, and Surgeon to University College Hospital; 36, Cavendish-square, W. (C. 1866-7. V.-P. 1879-81.)

Elected

1881 Herb, Richard G., M.D., Westminster Hospital, S.W.

1881 Heddy, William Jackson, 25, Hollywood-road, West Brompton, S.W.

1878 Hellier, John B., M.B., Headingley, Leeds.

1879 Henderson, George Courtenay, M.D., Kingston, Jamaica, West Indies.

1869 Hensley, Philip J., M.D., Assistant Physician to St. Bartholomew's Hospital; 4, Henrietta-street, Cavendish-square, W.

‡1868 Heslop, Thomas P., M.D., Physician to the Children's Hospital, Birmingham.

O.M. Hewett, Sir Prescott G., Bart., F.R.S., Consulting Surgeon to St. George's Hospital; Chesnut Lodge, Horsham, Sussex. (C. 1846-52. V.-P. 1854-7. *Pres.* 1863-4. V.-P. 1865-8.)

1855 Hewitt, Graily, M.D., Obstetric Physician to University College Hospital; 36, Berkeley-square, W. (C. 1865-7.)

1864 Hickman, William, M.B., Surgeon to the Samaritan Free Hospital; 1, Dorset-square, N.W.

1860 Hill, M. Berkeley, M.B., Surgeon to University College Hospital, and Surgeon for Out-Patients to the Lock Hospital; 55, Wimpole-street, Cavendish-square, W. (C. 1874-5.)

1875 Hitchcock, Harry Knight, M.D., Christowell, Branksome-park, Bournemouth, Hants.

1880 Hobson, John Morrison, M.D., 3, Addiscombe-villas, Lower Addiscombe-road, Croydon.

1874 Hoggan, George, M.B., 7, Trevor-terrace, Rutland-gate, S.W.

1847 Holman, H. Martin, M.D., Hurstpierpoint, Sussex.

1854 Holmes, Timothy, Surgeon-in-Chief to the Metropolitan Police, Surgeon to St. George's Hospital; 18, Great Cumberland-place, Hyde-park, W. (C. 1862-3. S. 1864-7. C. 1868. V.-P. 1869-71.)

1850 Holt, Barnard Wight, Consulting Surgeon to the Westminster Hospital; 14, Savile-row, W. (C. 1853.)

O.M. Holthouse, Carsten. (C. 1852-4, V.-P. 1874-5.)

1887 Hood, Donald William Charles, M.D., Assistant Physician to the West London Hospital, 43, Green-street, Park Lane.

1864 Hood, Wharton P., M.D., 65, Upper Berkeley-street, Portman-square, W.

1870 Hope, William, M.D., 56, Curzon-street, Mayfair, W.

1882 Hopkins, John, Medical Superintendent, Central London Sick Asylum, Cleveland-street, W.

1879 Horrocks, Peter, M.D., Assistant Obstetric Physician to Guy's Hospital, 9, St. Thomas's-street, S.E.

1883 Horsley, Victor, M.B., B.S., 129, Gower-street, W.C.

1877 Houghton, Walter B., M.D., late Assistant Physician to Charing Cross Hospital; Church Villa, Warrior-square, St. Leonards-on-Sea.

1880 Hovell, T. Mark, Aural Surgeon to the London Hospital; 3, Mansfield-street, Portland-place, W.

1866 Howard, Edward, M.D.

Elected

1875 HOWSE, HENRY GREENWAY, M.S. (C.), Surgeon to Guy's Hospital, and to the Evelina Hospital for Sick Children; 10, St. Thomas's-street, S.E. (C. 1878-81.)

†1856 HUDSON, JOHN, M.D., 11, Cork-street, Bond-street, W.

1854 HULKE, JOHN WHITAKER, F.R.S. (PRESIDENT), Surgeon to the Middlesex Hospital and Surgeon to the Royal London Ophthalmic Hospital; 10, Old Burlington-street, W. (C. 1863-5. S. 1868-72. V.-P. 1873-6, 1877-9. P. 1883.)

1854 HULME, EDWARD CHARLES, Woodbridge-road, Guildford.

1853 HUMBY, EDWIN, M.D., 83, Hamilton-terrace, St. John's Wood, N.W.

1874 HUMPHREYS, HENRY, M.D., late Physician to the Children's Hospital at Pendlebury; 9, St. Margaret's-terrace, St. Leonard's-on-Sea.

1852 HUTCHINSON, JONATHAN, F.R.S. (V.-P.), Consulting Surgeon to the London Hospital and to the Royal London Ophthalmic Hospital, Moorfields; 15, Cavendish-square, W. (C. 1856-9. V.-P. 1872-3, 1881-3. P. 1879-80.)

1882 HUTCHINSON, JONATHAN, junr., 15, Cavendish-square, W.

1883 HUXTABLE, LOUIS RALSTON, M.B., C.M., 99, Priory-road, West Hampstead.

1880 INGRAM, ERNEST FORTESCUE, Chelsea Infirmary, Call-street, Chelsea.

1865 JACKSON, J. HUGHLINGS, M.D., Physician to the London Hospital, Physician to the National Hospital for the Paralysed and Epileptic; 3, Manchester-square, W. (C. 1872-3.)

1875 JALLAND, WILLIAM HAMERTON, St. Leonard's House, Museum-street, York.

‡1853 JARDINE, JOHN LEE, Capel, near Dorking, Surrey.

1847 JAY, EDWARD, 112, Park-street, Grosvenor-square, W.

O.M. JENNER, SIR WILLIAM, Bart., M.D., D.C.L., K.C.B., F.R.S., Consulting Physician to University College Hospital; 63, Brook-street, Grosvenor-square, W. (C. 1850-3. V.-P. 1862-4 1875-6. *Pres.* 1873-4.)

1881 JENNINGS, WILLIAM OSCAR, M.D., 8, Rue Roy, Paris.

1875 JESSETT, FREDERIC BOWREMAN, 16, Upper Wimpole-street, W.

1879 JESSOP, CHARLES MOORE, The Willows, Fulwood-park, Preston (agents Messrs. Vesey, Holt, and Co., 17, Whitehall-place, S.W.).

1866 JESSOP, THOMAS RICHARD, 31, Park-square, Leeds.

1878 JOHNSON, ARTHUR JUKES, Yorkville, Ontario, Canada.

1876 JOHNSON, CHARLES HENRY, late Staff Surgeon, Turkish Contingent; Repton, Burton-on-Trent.

O.M. JOHNSON, GEORGE, M.D., F.R.S. (*Treasurer*), Physician to King's College Hospital; 11, Savile-row, W. (C. 1846-50. V.-P. 1863-4. T. 1880-82.)

1881 JOHNSTON, JOSEPH, M.D., Brigade Surgeon, Army Medical Department; St. John's Wood Barracks, N.W.

1854 JOHNSTONE, ATHOL A. W., St. Moritz House, 61, Dyke-road, Brighton.

1853 JONES, SYDNEY, M.B., Surgeon to St. Thomas's Hospital; 16, George-street, Hanover-square, W. (C. 1864-6.)

Elected

1862 JONES, THOMAS RIDGE, M.D. (C.), Physician to the Victoria Hospital for Children; 4, Chesham-place, S.W. (C. 1882-3.)

1858 JONES, WILLIAM PRICE, M.D., Claremont-road, Surbiton, Kingston.

1867 KELLY, CHARLES, M.D., Professor of Hygiene, King's College, Strand; Broadwater-road, Worthing, Sussex. (C. 1874.)

1846 KENT, THOMAS J., 89, Piccadilly

1852 KERSHAW, W. WAYLAND, M.D., Kingston-on-Thames.

1872 KESTEVEN, WILLIAM B., M.D., Little-park, Enfield, Middlesex. (C. 1879-81.)

1879 KESTEVEN, WILLIAM HENRY, 401, Holloway-road, N.

1859 KIALLMARK, HENRY WALTER, 5, Pembridge-gardens, Bayswater, W. (C. 1875-6.)

1882 KIDD, PERCY, M.D., Assistant Physician to the Hospital for Consumption, Brompton; 60, Brook-street, Grosvenor-square, W.

1883 KING, DAVID ALEXANDER, M.B., Assistant Physician to the Hospital for Consumption, Brompton; 26, Harley-street, Cavendish-square, W.

1867 KING, EDWIN HOLBOROW, Killcott, Godalming, Surrey.

1871 KING, ROBERT, M.B., Bargaly, Newton Stewart, N.B.

1852 KINGDON, J. ABERNETHY, Surgeon to the City Dispensary, and to the City of London Truss Society; 2, New Bank-buildings, Lothbury, E.C.

‡1856 KINGSLEY, HENRY, M.D., Physician to the Stratford Infirmary; Stratford-on-Avon, Warwickshire.

1878 KLEIN, EDWARD EMANUEL, M.D., F.R.S., Joint Lecturer on Physiology at St. Bartholomew's Hospital; 94, Philbeach-gardens, Warwick-road, Earl's Court, S.W.

1877 KNIGHT, CHARLES FREDERICK, Victoria House, Highgate-hill, Upper Holloway, N.

1875 LACY, C. S. DE LACY, M.B., 31, Grosvenor-street.

1878 LANCEREAUX, ETIENNE, M.D., 3, Rue Volney, Paris.

‡1865 LANCHESTER, HENRY THOMAS, M.D., 53, High-street, Croydon.

1882 LANE, WILLIAM ARBUTHNOT, M.B., B.S., Demonstrator of Anatomy at Guy's Hospital; 4, St. Thomas's-street, S.E.

1877 LANG, ALEXANDER, M.B. [41, Warwick-road, S.W.]

1865 LANGTON, JOHN (C.), Surgeon to, and Lecturer on Anatomy at, St. Bartholomew's Hospital, and Surgeon to the City of London Truss Society; 2, Harley-street, Cavendish-square, W. (C. 1882-3.)

1869 LARCHER, O., M.D. Par., Laureate of the Institute of France, of the Medical Faculty and Academy of Paris; 97, Rue de Passy, Paris. [. Kliensieck, Libraire, Rue de Lille, 11, Paris, per Messrs. Longman.]

1873 LATHAM, PETER WALLWORK, M.D., Physician to Addenbrooke Hospital, and Downing Professor of Medicine, Cambridge University; 17, Trumpington-street, Cambridge.

1876 LAW, WILLIAM THOMAS, M.D., 20, Warrior Gardens, St. Leonards-on-Sea.

1853 LAWRENCE, HENRY JOHN HUGHES, Surgeon, Grenadier Guards' Hospital; Rochester-row, Westminster, S.W. (C. 1873-5.)

Elected

1859 LAWSON, GEORGE, Surgeon to the Middlesex Hospital, and Surgeon to the Royal London Ophthalmic Hospital, Moorfields; 12, Harley-street, Cavendish-square, W. (C. 1870-1.)

1879 LAYCOCK, GEORGE LOCKWOOD, M.B., 12, Upper Berkeley-street, Portman-square, W.

1875 LEDIARD, HENRY AMBROSE, M.D., Surgeon to the Cumberland Infirmary; 43, Lowther-street, Carlisle.

1852 LEE, HENRY, Consulting Surgeon to St. George's Hospital; 9, Savile-row, W. (C. 1860-2. V.-P. 1875-6.)

1879 LEECH, DANIEL JOHN, M.D., 96, Mosley-street, Manchester.

1877 LEES, DAVID B., M.D., Assistant Physician to St. Mary's Hospital, and to the Hospital for Sick Children; 2, Thurloe Houses, Thurloe-square, S.W.

1867 LEES, JOSEPH, M.D., 21, Brixton-road, S.W.

1877 LEESON, JOHN RUDD, M.D., C.M., 6, Clifden-road, Twickenham.

1868 LEGG, JOHN WICKHAM, M.D., Assistant Physician to, and Lecturer on Pathological Anatomy at, St. Bartholomew's Hospital; 47, Green-street, Park-lane, W. (C. 1874-5.)

‡1867 LEUDET, T. EMILE, M.D. Par., Professor of Clinical Medicine; 49, Boulevard Cauchoise, Rouen, France. [M. Kliensieck, Libraire, Rue de Lille 11, Paris, per Messrs. Longman.]

1861 LICHTENBERG, GEORGE, M.D., 47, Finsbury-square, E.C.

1875 LINGARD, ALFRED, 49, Palace-road, Albert Embankment, S.E.

1877 LISTER, JOSEPH, D.C.L., LL.D., F.R.S., Professor of Clinical Surgery at King's College, and Surgeon to King's College Hospital; 12, Park Crescent, Regent's Park, W. (C. 1880-2.)

1878 LITTLEJOHN, SALTER G., M.B., C.M., Central London District Schools, Hanwell.

1848 LITTLE, WILLIAM JOHN, M.D., 18, Park-street, Grosvenor-square, W. (C. 1851-2. V.-P. 1856-9.)

†1862 LITTLE, LOUIS S., China. [18, Park-street.]

1874 LIVEING, EDWARD, M.D., 52, Queen Anne-street, Cavendish-square, W.

1863 LIVEING, ROBERT, M.D., Physician to the Skin Department and Lecturer on Dermatology at the Middlesex Hospital; 11, Manchester-square, W. (C. 1876.)

1882 LOCKWOOD, C. B., Demonstrator of Anatomy at St. Bartholomew's Hospital; 8, Serjeant's Inn, Fleet-street.

1876 LONGHURST, ARTHUR EDWIN TEMPLE, M.D., 22, Wilton-street, Grosvenor-place, S.W.

1881 LUBBOCK, MONTAGU, M.D., Assistant Physician to Charing Cross Hospital, and to the Hospital for Sick Children, Great Ormond-street; 19, Grosvenor-street, W.

1873 LUCAS, R. CLEMENT, M.B., M.S. (C.), Assistant Surgeon to Guy's Hospital, and Surgeon to the Evelina Hospital for Sick Children; 18, Finsbury-square, E.C. (C. 1883.)

Elected

1880 LUND, EDWARD, Consulting Surgeon to the Royal Infirmary; 22, St. John-street, Manchester.

1879 LUNN, JOHN REUBEN, Resident Medical Officer, New Marylebone Infirmary; Rackham-street, Ladbroke-grove-road, Notting-hill, W.

1871 MCCARTHY, JEREMIAH, M.A., Surgeon to the London Hospital,; 15, Finsbury-square, E.C. (C. 1878-80.)

1878 MCCONNELL, J. F., Professor of Pathology, Medical College, Calcutta. [Per Grindlay & Co., Parliament-street.]

1871 MAC CORMAC, SIR WILLIAM, Surgeon to St. Thomas's Hospital; 13, Harley-street, W. (C. 1878-80.)

1875 MACKELLAR, ALEXANDER OBERLIN, Assistant Surgeon, St. Thomas's Hospital; 22, George-street, Hanover-square, W.

1873 MACKELLAR, PETER H., M.B., Medical Officer, Fever Hospital, Stockwell, S.W.

1870 MACKENZIE, GEORGE WELLAND, 13, William-street, Lowndes-square, S.W.

1870 MACKENZIE, JOHN T., Bombay, India. [East India United Service Club, 14, St. James's-square.]

1882 MACKENZIE, FREDERIC MORELL, 10, Hans-place, S.W.

1864 MACKENZIE, MORELL, M.D., Physician to the Hospital for Diseases of the Throat, and Lecturer on Diseases of the Throat at the London Hospital; 19, Harley-street, Cavendish-square, W.

1878 MACKENZIE, STEPHEN, M.D., Physician (with care of out-patients) to, and Lecturer on Medicine at, the London Hospital; 26, Finsbury-square, E.C.

1879 MACLAGAN, THOMAS JOHN, M.D., 9, Cadogan-place, Belgrave-square, S.W.

1865 MACLAURIN, H. N., M.D.

1879 MACMAHON, JAMES THOMAS, L.K.Q.C.P.I., Beaumont Lodge, Howard-road, South Norwood, S.E.

1876 MACNAMARA, CHARLES, Surgeon to the Westminster Hospital; 13, Grosvenor-street, W.

1879 MACREADY, JONATHAN FORSTER, 125, Harley-street, W.

1875 MAHOMED, FREDERICK AKBAR, M.D. (C.), Assistant Physician and Demonstrator of Morbid Anatomy at Guy's Hospital; 12, St. Thomas's-street, S.E. (C. 1883.)

1877 MAKINS, GEORGE HENRY, St. Thomas's Hospital, Albert Embankment, S.E.

1876 MALLAM, BENJAMIN, Meadow Side, Leacroft-road, Staines.

1876 MAPLES, REGINALD, King's Clere, near Newbury.

1857 MARCET, WILLIAM, M.D., F.R.S., 39, Grosvenor-street, W. (C. 1869-71.)

1868 MARSH, F. HOWARD, Assistant Surgeon to St. Bartholomew's Hospital, Surgeon to the Hospital for Sick Children; 36, Bruton-street, Berkeley-square. (C. 1876-7.)

1876 MARSHALL, FRANCIS JOHN, St. George's Hospital.

1846 MARSHALL, JOHN, F.R.S., Surgeon to University College Hospital; 10, Savile-row, W. (C. 1861.)

Elected

1856 MARTIN, ROBERT, M.D., Consulting Physician to St. Bartholomew's Hospital; 51, Queen Anne-street, Cavendish-square, W. (C. 1871-2.)

1860 MASON, FRANCIS, Surgeon to St. Thomas's Hospital; 5, Brook-street, Grosvenor-square, W. (C. 1873-5.)

1867 MASON, PHILIP BROOKES, Burton-on-Trent.

†1852 MAY, GEORGE, Jun., M.B., Surgeon, Royal Berkshire Hospital, Reading.

1881 MAYLARD, ALFRED ERNEST, M.B., Lecturer on Anatomy, Western Medical School, Glasgow; 46, Claremont-street, Glasgow.

1874 MEREDITH, WILLIAM APPLETON, M.B., Surgeon to the Samaritan Hospital; 6, Queen Anne Street, Cavendish Square, W.

1859 MESSER, JOHN COCKBURN, M.D., Assistant Surgeon R.N., Her Majesty's Ship "Edinburgh," Queensferry, N.B.

‡1867 MICKLEY, ARTHUR GEORGE, M.B., Resident Medical Officer, St. Mary's Infirmary, St. John's-road, Upper Holloway.

1866 MICKLEY, GEORGE, M.A., M.B., St. Luke's Hospital, Old-street, E.C.

1877 MILNER, EDWARD, Surgeon to the Lock Hospital; 32, New Cavendish-street, Portland-place, W.

1882 MONEY, ANGEL, M.D., Hospital for Sick Children, Great Ormond-street; 14, Langham-place, W.

1879 MOORE, NORMAN, M.D., Assistant Physician to St. Bartholomew's Hospital; and Demonstrator of Morbid Anatomy and Warden of the College; the College, St. Bartholomew's Hospital.

1881 MOORE, THOMAS, 6, Lee-terrace, Blackheath, S.E.

1847 MORGAN, JOHN, 3, Sussex-place, Hyde-park-gardens, W. (C. 1856-8.)

1875 MORGAN, JOHN H., Assistant Surgeon to the Charing Cross Hospital, and to the Hospital for Sick Children, Great Ormond-street; 68, Grosvenor-street, W.

1874 MORISON, ALEXANDER, M.B., C.M., 7, The Terrace, Green-lanes, N.

1880 MORISON, BASIL GORDON, M.B., C.M., 70, Marquess-road, Canonbury, N.

1869 MORRIS, HENRY, M.A., M.B. (HON. SECRETARY), Surgeon to, and Lecturer on Surgery at, the Middlesex Hospital; 2, Mansfield-street, Portland-place, W. (C. 1877-9. S. 1881-3.)

1879 MORRIS, MALCOLM ALEXANDER, Lecturer on Skin Diseases at St. Mary's Hospital; 63, Montagu-square, W.

1875 MORTON, JOHN, M.B., Guildford.

1879 MOULLIN, CHARLES W. MANSELL, M.D., Assistant Surgeon to the London Hospital; 69, Wimpole-street, Cavendish-square, W.

1860 MOXON, WALTER, M.D., Physician to, and Lecturer on Medicine at, Guy's Hospital; 6, Finsbury-circus, E.C. (C. 1868-70. V.P. 1876-8.)

1878 MUMFORD, WILLIAM LUGAR, M.D., 1, Bartlett's-passage, Holborn-circus, E.C.

1876 MUNRO, WILLIAM, M.D., C.M., 102, Carl-street, Lower Broughton-road, Manchester.

1864 MYERS, ARTHUR B. R., Surgeon to 1st Battalion Coldstream Guards, the Hospital, Vincent-square, Westminster, S.W. (C. 1872-3.)

1882 MYERS, A. T., M.D., Medical Registrar, St. George's Hospital; 24, Clarges-street, Piccadilly, W.

Elected

1874 NANKIVELL, ARTHUR WOLCOT, St. Bartholomew's Hospital, Chatham.

1873 NETTLESHIP, EDWARD, (C.), Ophthalmic Surgeon to St. Thomas's Hospital; 5, Wimpole-street, Cavendish-square, W. (C. 1882.)

1875 NEWBY, CHARLES HENRY, West Hartlepool, Durham.

1865 NEWMAN, WILLIAM, M.D., Stamford, Lincolnshire.

1868 NICHOLLS, JAMES, M.D., Chelmsford, Essex.

1876 NICHOLSON, JOHN FRANCIS, M.D., Physician to the Hull General Infirmary; 29, Albion-street, Hull.

1878 NOOTT, W. M., 8, Kensington-park-road, W.

1864 NORTON, ARTHUR T., Surgeon to St. Mary's Hospital; 6, Wimpole-street, Cavendish-square, W. (C. 1877-9.)

1883 NORVILL, FREDERIC HARVEY, M.B., Royal Free Hospital, Gray's-Inn-road, W.C.

1856 NUNN, THOMAS WILLIAM, Consulting Surgeon to the Middlesex Hospital; 8, Stratford-place, Oxford-street, W. (C. 1864-6. V.-P. 1878-80.)

1871 NUNNELEY, REV. FREDERICK BARHAM, M.D.

1880 O'CONNOR, BERNARD, M.D., Physician to the North London Consumption Hospital, and Physician to the Westminster General Dispensary; 40, Brook-street, Grosvenor-square, W.

1873 O'FARRELL, GEORGE PLUNKETT, M.B., Tangier House, Boyle, Ireland.

1880 OGILVIE, GEORGE, M.B., Lecturer on Experimental Physics at the Westminster Hospital; 27, Welbeck-street, Cavendish-square, W.

1880 OGILVIE, LESLIE, M.B., Lecturer on Comparative Anatomy at the Westminster Hospital, 46, Welbeck-street, Cavendish-square, W.

1850 OGLE, JOHN W., M.D., Consulting Physician to St. George's Hospital 30, Cavendish-square, W. (C. 1855-6. S. 1857-60. C. 1861-3. V.-P. 1865-8.)

1876 OLIVER, JOHN FERENS, M.D., 12, Old Elvet, Durham.

1860 ORANGE, WILLIAM, M.D., Broadmoor, Wokingham, Berkshire.

1875 ORD, WILLIAM MILLER, M.D., Physician to, and Lecturer on Medicine at, St. Thomas's Hospital; 7, Brook-street, Hanover-square, W. (C. 1880-2.)

1878 ORLEBAR, HOTHAM GEORGE, M.D., 11, Pevensey-road, St. Leonard's-on-Sea.

1879 ORMEROD, J. A., M.B., Casualty Physician to St. Bartholomew's Hospital; 25, Upper Wimpole-street, W.

1875 OSBORN, SAMUEL, 10, Maddox-street, Bond-street, W.

1881 OWEN, ISAMBARD, M.D., Assistant Physician to St. George's Hospital 41, Gloucester-gardens, W.

1865 OWLES, JAMES ALLDEN, M.D., 106, Philbeach-gardens, South Kensington.

1883 PADDISON, EDMUND HOWARD, M.B., Assistant Medical Officer, Surrey County Asylum, Tooting, S.W.

1875 PAGE, HERBERT WILLIAM, M.A., M.C. Cantab., Surgeon (with charge of out-patients) to and Lecturer on Operative and Practical Surgery at St. Mary's Hospital; 146, Harley-street, Cavendish-square, W.

Elected

1870 PAGET, SIR JAMES, Bart., D.C.L., F.R.S., Consulting Surgeon to St. Bartholomew's Hospital; 1, Harewood-place, Hanover-square, W.

1872 PARKER, ROBERT WILLIAM (C.), Assistant Surgeon to the East London Children's Hospital; 8, Old Cavendish-street, W. (C. 1881-3.)

1874 PARKER, RUSHTON, M.B., B.S., Professor of Surgery in University College, Liverpool, and Assistant Surgeon to the Royal Infirmary; 61, Rodney-street, Liverpool.

1853 PARKINSON, GEORGE, 50, Brook-street, Grosvenor-square, W.

1882 PASTEUR, WILLIAM, 19, Queen-street, May-fair, W.

1865 PAVY, FREDERICK WILLIAM, M.D., F.R.S., Physician to, and Lecturer on Medicine at, Guy's Hospital; 35, Grosvenor-street, W. (C. 1872-4.)

1868 PAYNE, JOSEPH FRANK, B.A., M.D. (C.), Assistant Physician to, and Lecturer on Pathological Anatomy at, St. Thomas's Hospital; 78, Wimpole-street, Cavendish-square, W. (C. 1873-5, 1883. S. 1880-2.)

1872 PEARCE, JOSEPH CHANING, M.D., C.M., The Manor House, Brixton-rise S.W.

1878 PEARSE, THOMAS FREDERICK, M.D., Bramshott, Liphook, Hants.

1863 PEARSON, DAVID R., M.D., 23, Upper Phillimore-place, Kensington, W.

1879 PEEL, ROBERT, 130, Collins-street East, Melbourne, Victoria.

1878 PHILIPPS, SUTHERLAND REES, M.D., 3, Berkeley-place, Cheltenham.

1871 PHILLIPS, CHARLES DOUGLAS F., M.D., 10, Henrietta-street, Cavendish-square, W.

1878 PHILLIPS, JOHN WALTER, Physician to the Benevolent Asylum of Melbourne; 30, Stanley-street, West Melbourne, Victoria.

1877 PHILLIPS, RICHARD, 27, Leinster-square, Bayswater, W.

1875 PHILPOT, HARVEY JOHN, 14, Finsbury-circus, E.C., and 55, Warwick-road, Maida-vale, W.

1868 PICK, THOMAS PICKERING, Surgeon to, and Lecturer on Anatomy at, St. George's Hospital; 13, South Eaton-place, S.W. (C. 1870-1.)

1867 PITT, EDWARD G., M.D.

1876 PITTS, BERNARD, M.A., M.B., Assistant Surgeon to St. Thomas's Hospital; 31, Harley-street, Cavendish-square, W.

1883 POLAND, JOHN, Surgical Registrar at Guy's Hospital; 27A, Finsbury-square.

1882 POLLARD, BILTON, M.D., The Royal Infirmary, Manchester.

1846 POLLOCK, GEORGE D. (TRUSTEE), Consulting Surgeon to St. George's Hospital; 36, Grosvenor-street, W. (S. 1850-3. C. 1854-6. V.-P. 1863-5. P. 1875-6.)

1850 POLLOCK, JAMES EDWARD, M.D., Physician to the Hospital for Consumption and Diseases of the Chest, Brompton; 52, Upper Brook-street, W. (C. 1862-4. V.-P. 1879-81.)

1870 POORE, GEORGE VIVIAN, M.D. (C.), Assistant Physician to University College Hospital; 30, Wimpole-street, W. (C. 1883.)

1876 PORT, HEINRICH, M.D., 48, Finsbury-square, E.C.

1879 POTTER, HENRY PERCY, Kensington Infirmary, Marloe's-road, Kensington, W.

1881 POWELL, HENRY ALBERT, M.A., Elm Cottage, Beckenham.

Elected

1866 POWELL, RICHARD DOUGLAS, M.D. (C.), Physician to the Middlesex Hospital, Physician to the Hospital for Consumption and Diseases of the Chest, Brompton; 62, Wimpole-street, Cavendish-square, W. (C. 1873-5, 1881-3. S. 1877-9.)

1865 POWER, HENRY, Ophthalmic Surgeon to St. Bartholomew's Hospital; 37A, Great Cumberland-place, Hyde-park, W. (C. 1876-7.)

1856 PRIESTLEY, WILLIAM OVEREND, M.D., Consulting Physician-Accoucheur to King's College Hospital, and to the St. Marylebone Infirmary; 17, Hertford-street, Mayfair, W.

1882 PRINGLE, J. J., M.B., Edinb., 85, Bruton-street, Mayfair.

†1848 PURNELL, JOHN JAMES, Surgeon to the Royal General Dispensary; Woodlands, Streatham-hill, S.W. (C. 1858-61.)

1865 PYE-SMITH, PHILIP HENRY, M.D., Assistant Physician to, and Lecturer on Physiology at, Guy's Hospital; 54, Harley-street, Cavendish-square, W. (C. 1874-7.)

O.M. QUAIN, RICHARD, M.D., F.R.S. (TRUSTEE), Consulting Physician to the Hospital for Consumption and Diseases of the Chest, Brompton; 67, Harley-street, Cavendish-square, W. (C. 1846-51. S. 1852-6. T. 1857-68. *Pres.* 1869-70. V.-P. 1871-3.)

1859 RADCLIFFE, CHARLES BLAND, M.D., Consulting Physician to the Westminster Hospital; 25, Cavendish-square, W.

1872 RALFE, CHARLES HENRY, M.D., M.A., Assistant Physician to the London Hospital; 26, Queen Anne-street, W. (C. 1877-9.)

1857 RAMSKILL, J. SPENCE, M.D., Consulting Physician to the London Hospital, Physician to the National Hospital for the Paralysed and Epileptic; 5, St. Helen's-place, Bishopsgate-street, E.C.

1848 RANDALL, JOHN, M.D., Medical Officer, St. Marylebone Infirmary; 204, Adelaide-road, N.W. (C. 1864-6.)

1875 RANGER, W. GILL, 4, Finsbury-square, E.C.

1857 RANKE, HENRY, M.D., Munich.

1865 RASCH, ADOLPHUS A., M.D., Physician for Diseases of Women to the German Hospital; 7, South-street, Finsbury-square, E.C.

1870 RAY, EDWARD REYNOLDS, Dulwich, S.E.

1871 RAYNER, HENRY, M.D., Lecturer on Mental Diseases at St. Thomas' Hospital, Medical Superintendent, Middlesex County Lunatic Asylum, Hanwell W.

1858 REED, FREDERICK GEORGE, M.D., 46, Hertford-street, Mayfair, W.

1866 REEVES, HENRY ALBERT, Assistant Surgeon to the London Hospital; 78, Grosvenor Street, W.

1875 REID, ROBERT WILLIAM, M.D., C.M., Lecturer on Anatomy at St. Thomas's Hospital; 75, Lambeth Palace-road, S.E.

1881 RENNER, WILLIAM, M.R.C.S., Wilberforce-street, Free Town, Sierra Leone.

1854 REYNOLDS, J. RUSSELL, M.D., F.R.S., Consulting Physician to University College Hospital; 38, Grosvenor-street, W. (C. 1868-9.)

Elected

1871 RICHARDS, J. PEEKE, Medical Superintendent, Middlesex County Lunatic Asylum, Hanwell, W.

1866 RIVINGTON, WALTER, M.S. Lond., Surgeon to the London Hospital; 22, Finsbury-square, E.C.

‡1865 ROBERTS, DAVID LLOYD, M.D., Physician to St. Mary's Hospital, Manchester; 23, St. John's-street, Manchester.

1871 ROBERTS, FREDERICK THOMAS, M.D. (C.), Professor of Materia Medica at University College, and Physician to University College Hospital, and to the Hospital for Consumption, &c., Brompton; 53, Harley-street, Cavendish-square, W. (C. 1883.)

1878 ROBERTS, WILLIAM HOWLAND, M.D., Surgeon, Madras Army, Madras [East India United Service Club, St. James's Square].

1882 ROBINSON, TOM., M.D., 19, Guilford-street, W.C.

1882 ROECKEL, WALDEMAR JOSEPH, 7, Grosvenor-street W.

1858 ROSE, HENRY COOPER, M.D., Surgeon to the Hampstead Dispensary, High-street, Hampstead, N.W. (C. 1873-4.)

1876 ROSE, WILLIAM, M.B., B.S., Assistant Surgeon to King's College; 50, Harley-street, Cavendish-square, W.

1879 ROSS, JAMES, M.D., C.M., 335, Oxford-street, Manchester.

1875 ROSSITER, GEORGE FREDERICK, Cairo Lodge, Weston-super-Mare.

1877 ROTH, BERNARD, 48, Wimpole Street, Cavendish-square, W., and Rossmore, Preston-road, Brighton.

1858 ROUSE, JAMES, Surgeon to St. George's Hospital; 2, Wilton-street, Grosvenor-place, S.W.

1881 ROUTH, AMAND JULES MCCONNEL, M.D., B.S., Assistant Physician Accoucheur to the Charing Cross Hospital, and Physician to the Samaritan Free Hospital; 6, Upper Montagu-street, W.

1869 RUTHERFORD, WILLIAM, M.D., F.R.S., Professor of Physiology in the University of Edinburgh; 14, Douglas-crescent, Edinburgh.

1882 SAINSBURY, HARRINGTON, M.B., 62, Guildford-street, Russell-square, W.C.

1853 SALTER, S. JAMES A., M.B., F.R.S. Late Dental Surgeon to Guy's Hospital; Basingfield, near Basingstoke, Hants. (C. 1861-3. V.-P. 1880-2.)

1852 SANDERSON, HUGH JAMES, M.D., 26, Upper Berkeley-street, Portman-square, W.

1854 SANDERSON, JOHN BURDON, M.D., F.R.S., Waynflete Professor of Physiology at the University of Oxford; Museum, Oxford. (C. 1864-7 V.-P. 1873-4.)

1877 SANGSTER, ALFRED, M.B., B.A., 6, Savile-row, W.

1875 SANGSTER, CHARLES, 148, Lambeth-road, S.E.

1877 SANKEY, H. R. O., County Asylum, Prestwich, Manchester.

‡1847 SANKEY, W. H. OCTAVIUS, M.D., Boreatton-park, Shrewsbury. (C. 1855.)

1871 SAUNDERS, CHARLES EDWARD, M.D., 21, Lower Seymour-street, Portman-square, W.

Elected

1873 SAVAGE, GEORGE HENRY, M.D. (C.), Bethlem Royal Hospital, St. George's-road, S.E. (C. 1881-3.)

1882 SAVILL, THOMAS DIXON, M.D., St. Thomas's Hospital, S.E.

1877 SEMON, FÉLIX, M.D., Assistant Physician for Diseases of the Throat to St. Thomas's Hospital; 59, Welbeck-street, Cavendish-square.

1852 SEMPLE, ROBERT HUNTER, M.D., Physician to the Bloomsbury Dispensary; 8, Torrington-square, W.C. (C. 1859-61.)

1872 SERGEANT, EDWARD, Medical Officer of Health, Town Hall, Bolton, Lancashire.

1876 SHARKEY, SEYMOUR, M.B., Assistant Physician and Demonstrator of Morbid Anatomy to St. Thomas's Hospital; 77, Palace-road, Albert Embankment, S.E.

1880 SHATTOCK, S. G., Curator of Museum, University College, Gower-street; 9, Downshire-hill, Hampstead.

1877 SHEPPARD, CHARLES E., Rotherwood, Oakhill-road, Putney.

1856 SHILLITOE, BUXTON, Surgeon to the Great Northern Hospital, and to the Lock Hospital; 2, Frederick's-place, Old Jewry, E.C.

1883 SHUTER, JAMES, Assistant Surgeon to St. Bartholomew's Hospital, and to the Royal Free Hospital; 58, New Broad-street. E.C.

1855 SIBLEY, SEPTIMUS W., 7, Harley-street, Cavendish-square, W. (C. 1863-5. V.-P. 1879-81.)

1875 SIDDALL, JOSEPH BOWER, M.D., C.M., Duxmere-house, Ross, Herefordshire.

1880 SILCOCK, A. QUARRY, M.D., B.S., St. Mary's Hospital, Paddington, W.

O.M. SIMON, JOHN, C.B., D.C.L., F.R.S., Consulting Surgeon to St. Thomas's Hospital; 40, Kensington-square, W. (C. 1846-8. V.-P. 1855-9. *Pres.* 1867-8. V.-P. 1869-71.)

1866 SIMS, FRANCIS MANLEY BOLDERO, Assistant Surgeon to the Hospital for Diseases of the Skin, and Surgeon to the St. George's Dispensary; 12, Hertford-street, May-fair, W.

1865 SIMS, J. MARION, M.D., 267, Madison-avenue, New York.

1877 SKINNER, WILLIAM A., 45, Upper Belgrave-street, S.W.

1875 SMEE, ALFRED HUTCHINSON, The Grange, Hackbridge, Carshalton, Surrey.

1879 SMITH, E. NOBLE, Senior Surgeon, and Surgeon to the Orthopædic Department of the Farringdon Dispensary; 24, Queen Anne-street, Cavendish-square.

1872 SMITH, GILBART, M.D., Assistant Physician to the London Hospital, Physician to the Royal Hospital for Diseases of the Chest, City-road, Visiting Physician to the Margaret-street Infirmary for Consumption 68, Harley-street, Cavendish-square, W.

1875 SMITH, GEORGE JOHN MALCOLM, M.B., Hurstpierpoint, Sussex.

1863 SMITH, HENRY, Surgeon to, and Professor of Surgery at, King's College Hospital; 82, Wimpole-street, Cavendish-square, W. (C. 1873-4.)

1878 SMITH, HERBERT URMSON, M.B., Cape Colony.

Elected

1866 SMITH, HEYWOOD, M.D., Physician to the Hospital for Women; 18, Harley-street, Cavendish-square, W.

SMITH (P. H. PYE), see PYE-SMITH.

1846 SMITH, PROTHEROE, M.D., Physician to the Hospital for Women; 42, Park-street, Grosvenor-square, W.

1873 SMITH, RICHARD T., M.D., Physician to the St. Pancras Dispensary; 53, Haverstock-hill, N.W.

1883 SMITH, ROBERT PERCY, M.D., St. Thomas's Hospital, Albert Embankment, S.E.

1869 SMITH, ROBERT SHINGLETON, M.D., Lecturer on Physiology, Bristol Medical School; 9, Richmond-hill, Clifton, Bristol.

1881 SMITH, ROBERT WILLIAM, M.D., Physician to the Cheltenham Dispenpensary; 15, Imperial-square, Cheltenham.

1856 SMITH, THOMAS, Surgeon to St. Bartholomew's Hospital; 5, Stratford-place, Oxford-street, W. (C. 1867-9. V.-P. 1877-8.)

1866 SMITH, WILLIAM, Melbourne, Australia.

1870 SMITH, WILLIAM JOHNSON, Surgeon, Seamen's Hospital, Greenwich, S.E. (C. 1879-81.)

1869 SMITH, WILLIAM WILBERFORCE, M.D., 14, Stratford-place, W.

1870 SNOW, WILLIAM VICARY, M.D., Richmond Gardens, Bournemouth.

1868 SOUTHEY, REGINALD, M.D. (C.), Commissioner in Lunacy; 6, Harley-street, Cavendish-square, W. (C. 1882-3.)

1868 SPEY, G. FREDERICK HUME, M.D., Surgeon-Major 2nd Life Guards, Army and Navy Club, Pall-mall, and Cavalry Barracks, Windsor.

1855 SQUIRE, WILLIAM, M.D., 6, Orchard-street, Portman-square, W. (C. 1870-2.)

1861 SQUIRE, ALEXANDER BALMANNO, 24, Weymouth-street, Portland-place, W.

1876 STARTIN, JAMES, 16A, Sackville-street, Piccadilly, W.

1854 STEWART, WILLIAM EDWARD, 16, Harley-street, Cavendish-square, W.

1879 STIRLING, EDWARD CHARLES, Adelaide, South Australia.

1881 STOKES, HENRY FRASER, 258, St. Paul's-road, Highbury, N.

†1853 STREATFEILD, J. F., Surgeon to the Royal London Ophthalmic Hospital, Moorfields, and Ophthalmic Surgeon to University College Hospital; 15, Upper Brook-street, W.

1875 STURGE, W. A., M.D., 9, Rue Longchamp, Nice, Alpes Maritimes, France.

1863 STURGES, OCTAVIUS, M.D., Physician to the Westminster Hospital; 85, Wimpole-street, Cavendish-square, W.

†1871 SUTHERLAND, HENRY, M.D., 6, Richmond-terrace, Whitehall, S.W.

1876 SUTRO, SIGISMUND, M.D., Senior Physician to the German Hospital; 37A, Finsbury-square, E.C.

1864 SUTTON, HENRY G., M.B., Physician to and Lecturer on Pathology at, the London Hospital, Physician to the City of London Hospital for Diseases of the Chest; 9, Finsbury-square, E.C. (C. 1875-6.)

1882 SUTTON, JOHN BLAND, Lecturer on Comparative Anatomy at the Middlesex Hospital; 22, Gordon-street, Gordon-square, W.C.

‡1867 SWAIN, WILLIAM PAUL, 20, Ker-street, Devonport.

Elected

1881 SYMONDS, CHARTERS JAMES, M.S., Assistant Surgeon to Guy's Hospital, and to the Evelina Hospital for Sick Children; 16, St. Thomas's-street, S.E.

1870 TAIT, ROBERT LAWSON, Surgeon to the Birmingham and Midland Hospital for Women; 7, Great Charles-street, Birmingham.

1864 TATHAM, JOHN, M.D., Physician to the Hospital for Consumption and Diseases of the Chest, Brompton; 12, George-street, Hanover-square, W.

1870 TAY, WARREN (C.), Surgeon to, and Demonstrator of Practical Anatomy at the London Hospital; 4, Finsbury-square, E.C. (C. 1881-2.)

1871 TAYLOR, FREDERICK, M.D., Assistant Physician to, and Lecturer on Materia Medica at, Guy's Hospital, and Physician to the Evelina Hospital for Sick Children; 11, St. Thomas's-street, S.E. (C. 1879-81.)

1880 TAYLOR, SEYMOUR, M.B., M.C., St. Thomas's Hospital; 22, Taviton-street, Gordon-square.

1861 TREVAN, WILLIAM FREDERIC, Mostyn-villa, Brockman-road, Folkestone.

1879 THIN, GEORGE, M.D., 22, Queen Anne-street, Cavendish-square, W.

1870 THOMAS, JOHN DAVIES, M.B., University College Hospital (India).

1852 THOMPSON, SIR HENRY, Knt., Emeritus Professor of Clinical Surgery in University College; 35, Wimpole-street, Cavendish-square, W. (S. 1859-63. C. 1865-67. V.-P. 1868-70.)

1874 THORNTON, JOHN KNOWSLEY, M.B., Surgeon to the Samaritan Free Hospital for Women and Children; 22, Portman-street, Portman-square.

1872 THORNTON, WILLIAM PUGIN, Surgeon to the St. Marylebone General Dispensary; 6, Duchess-street, Portland-place, W.

1865 THOROWGOOD, J. C., M.D., Lecturer on Materia Medica at the Middlesex Hospital, Physician to the City of London Hospital for Diseases of the Chest; 61, Welbeck-street, W. (C. 1876-78.)

1877 TIBBITS, HERBERT, F.R.C.P. Ed., 68, Wimpole-street, W.

1880 TIRARD, NESTOR ISIDORE, M.B. Lond. (C.), Assistant Physician to the Evelina Hospital for Sick Children; 27, Weymouth-street, Portland-place.

1856 TOMES, J., F.R.S., Consulting Dental Surgeon to the Middlesex Hospital Upwood Gorse, Caterham, Surrey. (C. 1867-9.)

1864 TONGE, MORRIS, M.D., Harrow-on-the-hill, Middlesex.

1882 TOOTH, H. H., M.B., 34, Harley-street, Cavendish-square, W.

1872 TOWNSEND, THOMAS SUTTON, 68, Queen's Gate, South Kensington.

1881 TREVES, FREDERICK, Assistant Surgeon to the London Hospital; 18, Gordon-square, W.C.

1851 TROTTER, JOHN W., Surgeon-Major, Coldstream Guards; Bossall Vicarage, York. (C. 1865-9.)

Elected

1859 TRUMAN, EDWIN THOMAS, Surgeon-Dentist in Ordinary to Her Majesty's Household; 23, Old Burlington-street, W.

1867 TUCKWELL, HENRY MATTHEWS, M.D., Physician to the Radcliffe Infirmary; 64, High-street, Oxford.

1858 TUDOR, JOHN, Dorchester, Dorset.

†1875 TURNER, FRANCIS CHARLEWOOD, M.D., Physician to the London Hospital; 15, Finsbury-square, E.C.

1882 TURNER, GEORGE ROBERTSON, Visiting Surgeon, Seamen's Hospital, Greenwich, and Joint Lecturer on Practical Surgery at St. George's Hospital; 49, Green-street, Park-lane.

1833 TURNER, JAMES SMITH, Consulting Dental Surgeon to the Middlesex Hospital; 12, George-street, Hanover-square, W.

1858 TURTLE, FREDERICK, Clifton Lodge, Woodford, Essex.

1878 TYRRELL, WALTER.

1880 TYSON, WILLIAM JOSEPH, M.D., Medical Officer of the Folkestone Infirmary; 10, Langhorne-gardens, Folkestone.

1854 VASEY, CHARLES, 5, Cavendish-place, Cavendish-square, W.

1867 VENNING, EDGCOMBE, 87, Sloane-street.

1868 VINCENT, OSMAN, Surgeon to the National Orthopædic Hospital; 45, Seymour-street, Portman-square, W.

†1867 WAGSTAFFE, WILLIAM WARWICK, B.A., Purleigh, St. John's-hill, Sevenoaks. (C. 1874, 1878-80. S. 1875-7.)

O.M. WAITE, CHARLES D., M.D., Senior Physician to the Westminster General Dispensary; 3, Old Burlington-street, W.

1881 WALLER, BRYAN CHARLES, M.D., 15, Lonsdale-terrace, Edinburgh.

1873 WALSHAM, WILLIAM JOHNSON, M.B., C.M. (C.), Assistant Surgeon to and Demonstrator of Practical and Orthopædic Surgery at St. Bartholomew's Hospital, Surgeon to the Metropolitan Free Hospital; 27, Weymouth-street, Portland-place. (C. 1881-3.)

1859 WALTERS, JOHN, M.B, Reigate, Surrey.

1847 WARD, T. OGIER, M.D. (C. 1851-3.)

1858 WARDELL, JOHN RICHARD, M.D., Calverley-park, Tunbridge Wells.

1877 WARNER, FRANCIS, M.D., Assistant Physician to the London Hospital and to the East London Hospital for Children; 24, Harley-street.

1877 WATERHOUSE, CHARLES, M.B., M.C. [Abroad.]

1879 WATERS, JOHN HENRY, M.D., 101, Jermyn-street, St. James's, S.W.

1878 WATNEY, HERBERT, M.D., 1, Wilton-crescent, S.W.

1880 WATTEVILLE, ARMAND DE, M.A., M.B., Medical Electrician to St. Mary's Hospital; 30, Welbeck-street, Cavendish-square, W.

1860 WAY, JOHN, M.D., 4, Eaton-square, S.W. (C. 1873-4.)

†1858 WEBER, HERMANN, M.D., Physician to the German Hospital; 10, Grosvenor-street, Grosvenor-square, W. (C. 1867-70. V.-P. 1878-80.)

1876 WEIR, ARCHIBALD, M.D., St. Mungho's, Great Malvern.

1864 WELCH, THOMAS DAVIES, M.D.

Elected

1853 WELLS, SIR THOMAS SPENCER, Bart., Surgeon to the Samaritan Free Hospital for Women and Children; 3, Upper Grosvenor-street, W. (C. 1865-8. V.-P. 1876-7.)

†1851 WEST, CHARLES, M.D., 29, Promenade des Anglais, Nice, Alpes Maritimes, France, and 2, Bolton-row, Mayfair, W. (C. 1856-7.)

1877 WEST, SAMUEL, M.D., Assistant Physician to the City of London Hospital for Diseases of the Chest, Victoria-park, Medical Registrar at St. Bartholomew's Hospital; 15, Wimpole-street, Cavendish-square, W.

1867 WHIPHAM, THOMAS TILLYER, M.B., Physician to, and Lecturer on Clinical Medicine at, St. George's Hospital; 11, Grosvenor-street Grosvenor-square, W. (C. 1880-2.)

1869 WHIPPLE, JOHN H. C., M.D., Assistant Surgeon, 1st Battalion Coldstream Guards, Hospital.

1877 WHITE, CHARLES HAYDON, 20, Shakespeare-street, Nottingham.

1881 WHITE, JOHN BRADSHAW, M.D., 14, Portland-place, Lower Clapton, E.

1881 WHITE, WILLIAM HALE, M.D., Demonstrator of Anatomy at Guy's Hospital; 4, St. Thomas's-street, S.E.

‡1868 WHITEHEAD, WALTER, 24, St. Ann's-square, Manchester.

1877 WHITMORE, WILLIAM TICKLE, 7, Arlington-street, S.W.

1870 WICKSTEED, FRANCIS WILLIAM, Chester House, Weston-super-Mare.

1879 WILCOX, HENRY, M.B., Hurst-villa, Lewisham High-road, S.E.

1867 WILCOX, RICHARD WILSON, Temple-square, Aylesbury, Bucks.

1869 WILKIN, JOHN F., M.D., M.C., New Beckenham, Kent.

1871 WILKINSON, J. SEBASTIAN, Late Surgeon to the Central London Ophthalmic Hospital; New Zealand.

1855 WILKS, SAMUEL, M.D., F.R.S., (V.-P.), Physician to, and Lecturer on Clinical Medicine at, Guy's Hospital; 72, Grosvenor-street, W. (C. 1857-60. V.-P. 1869-72, 1883. P. 1881-2.)

1879 WILLCOCKS, FREDERICK, M.D., Assistant Physician to Charing Cross Hospital, Physician to the Evelina Hospital for Sick Children; 14, Mandeville-place, Manchester-square.

1869 WILLIAMS, ALBERT, M.D., 60, Kirkdale, Sydenham, S.E.

O.M. WILLIAMS, C. J. B., M.D., F.R.S., Consulting Physician to the Hospital for Consumption and Diseases of the Chest, Brompton [47, Upper Brook-street, Grosvenor-square, W.]. (*Pres.* 1846-7. V.-P. 1848-52. C. 1853-5. V.-P. 1858-61.)

‡1858 WILLIAMS, CHARLES, Surgeon to the Norfolk and Norwich Hospital; 9, Prince of Wales-road, Norwich.

1866 WILLIAMS, CHARLES THEODORE, M.D., Physician to the Hospital for Consumption and Diseases of the Chest, Brompton; 47, Upper Brook-street, Grosvenor-square, W. (C. 1875-8.)

1881 WILLIAMS, DAWSON, M.D., B.S., 4, Oxford and Cambridge Mansions, Marylebone-road, N.W.

Elected.

1872 WILLIAMS, JOHN, M.D., Assistant Obstetric Physician to University College Hospital; 11, Queen Anne-street, Cavendish-square, W. (C. 1878-80.)

1881 WILLIAMS, W. ROGER, Surgical Registrar to the Middlesex Hospital; 1, Bentinck-street, Welbeck-street, W.

1864 WILLIAMS, W. RHYS, M.D., Commissioner in Lunacy, 19, Whitehall-place, S.W.

1876 WILLIAMSON, JAMES MANN, M.D., Ventnor, Isle of Wight.

1863 WILLIS, FRANCIS, M.D., Braceborough, Stamford.

1859 WILSON, EDWARD THOMAS, M.B., Montpelier-terrace, Cheltenham.

1859 WILSON, ROBERT JAMES, F.R.C.P. Ed., 7, Warrior-square, St. Leonards-on-Sea.

1863 WILTSHIRE, ALFRED, M.D., Joint Lecturer on Midwifery at St. Mary's Hospital; 57, Wimpole-street, Cavendish-square, W.

‡1861 WINDSOR, THOMAS, Consulting Surgeon to the Salford Royal Hospital; Woodcroft, Dudley-road, Manchester, S.W.

1874 WISEMAN, JOHN GREAVES, Dearden-street, Ossett, Yorkshire.

1865 WITHERBY, WILLIAM H., M.D., Pitt-place, Coombe, Croydon.

1850 WOOD, JOHN, F.R.S., Surgeon to, and Professor of Clinical Surgery at, King's College Hospital; 61, Wimpole-street, W. (C. 1857-9. V.-P. 1872-4.)

1854 WOOD, WILLIAM, M.D., Physician to St. Luke's Hospital; 99, Harley-street, W.

1876 WOOD, WILLIAM EDWARD RAMSDEN, M.A., M.B. Cantab., Bethlem Royal Hospital, St. George's-road, S.E.

1883 WOODHEAD, GERMAN SIMS, M.D., 6, Marchhall-crescent, Edinburgh.

1879 WOODWARD, G. P. M., M.D., Deputy Surgeon-General; Sydney, New South Wales.

1865 WORKMAN, CHARLES JOHN, M.D., Titherley, Teignmouth, Devon.

1863 WORLEY, WILLIAM CHARLES, 43, De Beauvoir-road, N.

1869 WYMAN, W. S., M.D., Westlands, Upper Richmond-road, Putney, S.W.

1869 YEO, J. BURNEY, M.D., Physician with Charge of Out-Patients to King's College Hospital, and Assistant Physician to the Brompton Hospital for Consumption; 44, Hertford-street, Mayfair, W.

1872 YOUNG, HENRY, M.B., Monte Video, South America.

ANNUAL REPORT OF COUNCIL,

1881-82.

PRESENTED AT THE ANNUAL MEETING, JANUARY 2ND, 1883.

THE Council is happy to be able to report the continued prosperity of the Society. Whether regard be paid to the total number of members, to the number and value of the specimens exhibited, to the average attendance at the meetings, or to the state of the finances, the Pathological Society of London was never more flourishing than now.

Twenty-seven new members have been added to the roll, 5 have resigned, and 9 have died. The actual total number of members at the present time is 650.

The death list consists of Mr. George H. Cowburn, Mr. Thomas Edwin Maclean (who died at Cairo in 1881), Dr. George Budd F.R.S, Dr. T. B. Peacock, Dr. Charles Morehead, Mr. R. W. Lyell, Mr. George Critchett, Dr. Edwards Crisp, and Sir Thomas Watson F.R.S.

Death has also removed Professor Theodor Schwann from the list of the Honorary Members of the Society.

Amidst the signs of prosperity the Council feels one source of regret, in which the whole Society will share. It is that the death list this year includes so many eminent men, who have in times past rendered valuable services to the Society, and whose names have shed lustre upon it.

Professor Schwann was for some years Professor of Physiology in the University of Liège. He was elected an Honorary Member of this Society in 1878. He has been called the creator of the cell doctrine, and was certainly one of the chief initiators of recent physiological progress. Amongst his many works may be mentioned his researches on muscular contraction, and his observations on the

dependence of the fermentative processes on the development of microscopic organisms. He died in the early part of 1882 in his seventy-second year.

First amongst the deceased members must be mentioned Thomas Bevill Peacock, one of the Founders of the Society. Dr. Peacock was President in the years 1865-66, and from the year 1846 to the time of his death, in June, 1882, he had almost continuously given his services to the Society. For six years he was a member of the Council, for two years Honorary Medical Secretary, for seven years a Vice-President, and for several years one of the Trustees. He was, besides, a very constant attendant at the ordinary meetings, and a very large and valued contributor to the 'Transactions.' Moreover, he conferred a lasting benefit, not only on the members of the Society, but upon every one wishing to consult the 'Transactions,' by the generosity which led him to bear the whole cost of publishing and issuing the general index to the volumes from 1864 to 1874 (*i. e.* volumes xvi—xxv).

Sir Thomas Watson was so distinguished a man, and held such a leading place in the profession, that it would be superfluous to attempt to add anything to the biographies which have been written of him. It ought, however, to be noted that he was a Vice-President of the Society from 1859 to 1863, and President in the years 1857 and 1858, and that his Presidency was graced by the professional learning and courteous bearing which were so well known to characterise him.

Mr. George Critchett, F.R.C.S., was Honorary Surgical Secretary in 1849, a Vice-President in 1866-67, and a member of the Council in 1851-58-59. By his death the profession has lost an eminent surgeon, of widely-extended reputation, and of a very genial and courteous disposition.

The early death of Mr. R. W. Lyell, M.D., F.R.C.S., has taken from amongst us one of unceasing industry and considerable knowledge, and whose career promised to be as useful as it had been upright and laborious.

Dr. Edwards Crisp was an original member of the Society, a member of Council in 1846-47, and a Vice-President from 1870-72. It is but fair to his memory—especially now that comparative pathology has been formally brought within the scope of the Society's work—to state that during a long course of years Dr. Crisp insisted on the advantage of studying the morbid anatomy of

animals; and he himself, since the year 1864, was continually exhibiting specimens which he had procured from the Zoological Gardens and elsewhere. These specimens were illustrative of very various as well as very important pathological changes in the lower animals, as a reference to the general index will show. Indeed, so far as the Society is concerned, Dr. Crisp may truly be called the pioneer of the study of comparative pathology, and it must have gratified him to witness the establishment by the Council, at the suggestion of Mr. J. Hutchinson, of a "Comparative Pathology Committee."

In connection with this subject the Council is happy to report that the "Comparative Pathology Committee" has commenced to work. Already several specimens have been brought to the meetings, and the abundant material at the Zoological Society's Gardens is being steadily utilised, especially by Mr. T. Bland Sutton.

The other Committee, appointed last year, also at the suggestion of Mr. J. Hutchinson, namely, the Committee to obtain information respecting the uncompleted cases in the 'Transactions,' has sent in its report. This has been already presented to the Society, and is in the possession of the members, bound up in the volume (thirty-third) of the 'Transactions,' just issued. To the members of that Committee the Council feels that the Society is deeply indebted for the time and pains they have bestowed on the work which the report necessarily entailed.

It will be remembered that at the end of the session 1881-82 the President expressed regret that, owing to the large number of specimens offered for exhibition a great many could not be received on account of the limit of time at the disposal of the Society. Indeed, the question whether an extra meeting should be added at the end of the session was considered by the Council, but it was decided in the negative.

With due consideration, however, for this fact, the Council, after much deliberation, has resolved upon setting aside one or more evenings in April of the present session for the exhibition and discussion of the morbid anatomy of organs in diabetes. The reason for so doing is that, though most of the larger and more general subjects of pathology have been discusssed on previous occasions, much has yet to be learned about some of the more limited subjects. It was thought that by giving a sufficiently long notice those who have the opportunities for research might be acquiring much valu-

able information respecting the morbid changes associated with a most important and, as yet, imperfectly understood disease such as diabetes.

The income of the Society has been £563 19s. 1d., and in addition to this there are the year's dividends on stock, which, owing to the death of Dr. Peacock, who used to receive them, have not yet been paid by the Bank of England.

The expenditure has been £502 3s. 4d., of which £341 8s. 7d. is the cost of 750 copies of the last volume of the 'Transactions.'

The balance at the bank is £201 0s. 10d. The sum invested remains the same as last year.

THE PATHOLOGICAL SOCIETY OF LONDON,

Cr. *In Account with the Treasurer*, GEORGE JOHNSON, M.D., F.R.S., *86th Session*, 1881–82. **Dr.**

	£	s.	d.	£	s.	d.
By *Balance* at Union Bank of London, Jan., 1st, 1882				139	5	1
Subscriptions:						
400 Annual Subscriptions, 1881-2	420	0	0			
2 Ditto, Arrears	2	2	0			
23 Admission Fees	24	3	0			
2 Composition Fees	31	10	0			
4 Ditto (Non-Resident)	8	8	0			
				486	3	0
Sale of Transactions:						
By the Society	12	1	4			
Messrs. Smith and Elder's Account	50	14	9			
				62	16	1
Mr. Harrison Cripps for Illustrations in Vol. XXXII	15	0	0			
				15	0	0
				£703	4	2

To *Meetings:*	£	s.	d.	£	s.	d.
Payment to Royal Medical and Chirurgical Society for use of Rooms, Gas, &c.	63	0	0			
Refreshments, Waiters, Management	36	15	0			
Richard Coldrey (Meetings, &c.)	7	10	0			
Microscopes and Lamps (Baker)	3	19	0			
				111	4	0
Transactions: Vol. XXXIII (750 copies):						
Printing, Binding, and Delivery (Adlard)	194	4	8			
Supplementary Report, 750 copies (Adlard)	17	19	3			
Lithography and Woodcuts (Noble Smith)	15	14	0			
Ditto (Burgess)	29	6	0			
Ditto (Huth)	19	15	0			
Ditto (Mintern Brothers)	27	0	0			
Ditto (West, Newman & Co.)	26	13	8			
Autotype Company	7	13	0			
Index (Wheatley)	3	3	0			
				341	8	7
Secretariat and Treasury:						
Assistance to Hon. Secs.	7	7	0			
Posting Ledgers (McDermott)	2	2	0			
Collecting Subscriptions (Wheatley)	16	16	0			
Petty Cash (Hon. Secretary)	1	9	0			
Ditto (Wheatley)	8	8	4			
				36	2	4
Stationery:						
Wodderspoon	12	6	8			
Odell & Sons	1	1	6			
				13	8	2
Postage (Union Bank)	0	0	3	0	0	3
				502	3	4
Balance				201	0	10
				£703	4	2

The arrangements rendered necessary by the death of Dr. Peacock, one of the Trustees, not having been completed in time to permit the receipt of the year's dividends on £1067 15s. 1d. consols, that amount will appear in next year's balance sheet.

Audited, compared with the Vouchers, and found correct, *Auditors* { DAVID W. FINLAY. / W. HARRISON CRIPPS.

Dec. 29th, 1882.

LIST OF SPECIMENS AND REPORTS

BROUGHT BEFORE THE SOCIETY DURING THE SESSION 1882-83.

I. DISEASES, ETC., OF THE NERVOUS SYSTEM.

PAGE

1. On the causes of holes in the brain, together with two cases of universal cystic degeneration [With Plate I] By G. H. SAVAGE, M.D., and W. HALE WHITE, M.D. 1
2. Case of arteritis with thrombosis of both middle cerebral arteries occurring during the secondary stage of syphilis [With fig. 1, Plate VII] By SEYMOUR J. SHARKEY, M.B. 10
3. Spinal nerves from three cases of infantile paralysis [With fig. 1, Plate II] By WALTER EDMUNDS, M.D. 15
4. Amputation changes in nerves [With figs. 2, 3, and 4, Plate II] By W. HALE WHITE, M.D., and WALTER EDMUNDS, M.D. 16
5. Encephalocele (Card specimen) [With Plate III] Exhibited by J. B. SUTTON 18

II. DISEASES, ETC., OF THE ORGANS OF RESPIRATION.

1. A lobulated lamellar fibroma on the pleura By F. CHARLEWOOD TURNER, M.D. 19
2. Larynx from an infant which had been the subject of a peculiar form of obstructed inspiration By DAVID B. LEES, M.D. 19
3. Case of laryngeal phthisis By B. G. MORISON, M.B. 21

PAGE

4. Ulceration of the larynx from a case of measles, and from a case of scarlet fever
By Norman Moore, M.D. 22
5. Lung with impacted foreign body
By Norman Moore, M.D. 23
6. Hydatid cyst in lung; empyema By J. Curnow, M.D. 24
7. The bacilli of tubercle found in contents of cavities and not in lung tissue By Samuel West, M.D. 26

III. DISEASES, ETC., OF THE ORGANS OF CIRCULATION.

1. Abnormal heart By Norman Moore, M.D. 29
2. Variety in the structure of the heart
By Norman Moore, M.D. 31
3. Malformed heart, consisting of two cavities
By F. Charlewood Turner, M.D. 32
4. A case of tricuspid stenosis
By Bedford Fenwick, M.D. 35
5. Stenosis of the mitral orifice; recent vegetations on the mitral, aortic, and tricuspid valves; a sacculated fibrinous coagulum loose in the left auricle
By F. Charlewood Turner, M.D. 36
6. Ulcerative endocarditis; infarcts in spleen and kidney; acute nephritis By Frederick Taylor, M.D. 38
7. Heart disease and subcutaneous fibrous nodules following rheumatism By John Cavafy, M.D. 41
8. Morbus cordis; adherent pericardium; rheumatic nodules
By Angel Money, M.D. 45
9. The analogy between rheumatic nodules and heart disease (Living specimen)
By F. G. Dawtrey Drewitt, M.D. 50
10. Endocarditis with miliary abscesses of the heart in a case of hip-joint disease By Norman Moore, M.D. 52
11. Syphilitic gumma of the heart
By George C. Henderson, M.D. 53

PAGE

12. Observations on morbid conditions of the cerebral arteries [With Plate IV]
By Samuel Wilks, M.D., for C. Handfield Jones, M.B. 55

13. Aneurysm of the middle part of the arch of the aorta; death from embolism of the aorta, detached from the left ventricle By Samuel West, M.D. 62

14. Aneurysm of the aorta, rupturing into the pulmonary artery By Samuel West, M.D. 64

15. Dissecting aneurysm of the first part of the arch of the aorta By Samuel West, M.D. 65

16. Complete obliteration of one coronary artery; sudden death; remarks upon the anastomosis of the coronary arteries By Samuel West, M.D. 66

17. Case of diffuse aneurysm of the abdominal aorta
By A. Quarry Silcock, M.D. 68

18. Aneurysms in children By Norman Moore, M.D. 71

19. Thrombosis of the pulmonary artery, para-vaginal and dermoid cysts By F. A. Mahomed, M.B. 72

20. Abnormal aortic valve (Card specimen)
Exhibited by W. A. Berridge 76

21. Vessels from a case of gangrene of the right leg caused by thrombosis of left common iliac artery, and detachment of a portion of the clot (Card specimen)
Exhibited by J. Kingston Fowler, M.D. 77

22. Aneurysm of aorta (Card specimen)
Exhibited by R. E. Carrington, M.D. 78

23. Congenital atresia of right ventricle, ductus arteriosus patent (Card specimen)
Exhibited by John Abercrombie, M.D. 78

IV.—DISEASES, ETC., OF THE ORGANS OF DIGESTION.

PAGE

1. Carcinoma of œsophagus By Norman Moore, M.D. 79
2. Cancer of œsophagus with perforation into the right lung, the upper lobes of which were converted into a cavity filled with decomposing food By Frederic S. Eve 80
3. A case of ruptured stomach By John R. Lunn 81
4. The stomach from a case of acute gastrorrhœa or acute dilatation of the stomach; death within forty hours of the onset of vomiting By Henry Morris 82
5. Notes of the cases of dilated stomach, not due to pyloric obstruction, observed in the post-mortem room of Guy's Hospital from 1875 to 1882 By James F. Goodhart, M.D. 88
6. Stomach exhibiting the condition known as phlegmonous gastritis [With Plate X, figs. 4 and 5] By A. Quarry Silcock, M.D. 90
7. Cases of gastric ulcer associated with general degeneration of the arteries By Norman Moore, M.D. 94
8. A case of sulphuric acid poisoning with intense inflammation of the transverse colon By W. Hale White, M.D. 96
9. Two cases of simple ulcer of the duodenum By Norman Moore, M.D. 98
10. Lympho-sarcoma invading the duodenum By Norman Moore, M.D. 99
11. Colloid cancer of the stomach, lymph-glands, and lungs By P. H. Pye-Smith, M.D. 100
12. Epithelioma of stomach with wide diffusion of secondary deposits in other viscera and throughout the integuments. [With Plate VIII and Plate IX, figs. 1 and 2] By David W. Finlay, M.D. 102
13. Polypus of the stomach By Norman Moore, M.D. 106
14. Intussusception caused by an intestinal polypus, and cured after sloughing of the strangulated bowel By A. A. Bowlby 106
15. Very large connective-tissue polypus of rectum By A. A. Bowlby 108

PAGE

16. Diffused polypoid growths of large intestine
By A. A. Bowlby 109
17. A case of double obturator hernia
By Anthony A. Bowlby 109
18. Stricture of intestine at the ileo-cæcal valve
By Norman Moore, M.D. 112
19. Cases of ulceration of vermiform appendix in typhoid fever By Norman Moore, M.D. 113
20. Typhoid fever; ulceration of large intestine with perforation By Samuel West, M.D. 114
21. Ulceration of large and small intestines in enteric fever
By J. Curnow, M.D. 116
22. Case of syphilitic perihepatitis [With Plate VII, fig. 2]
By Seymour J. Sharkey, M.B. 118
23. Acute atrophy of the liver By John Cavafy, M.D. 122
24. Cirrhosis and acute atrophy of the liver [With Plate V, fig. 1, Plate VI and Plate VII, fig. 3]
By W. Cayley, M.D. 127
25. Cirrhosis of the liver in a child of seven months from congenital absence of the common duct
By Heneage Gibbes, M.D. 129
26. Lardaceous disease of the liver, the infiltration appearing to follow the course of the capillaries within the lobules of the organ [With Plate IX, fig. 3]
By F. Charlewood Turner, M.D. 131
27. Case of visceral syphilis By Norman Moore, M.D. 133
28. Tubercle of the liver in an adult
By Norman Moore, M.D. 133
29. Tubercular ulcers of the tongue (Card specimen)
Exhibited by Stanley Boyd 134
30. Tubercular disease of the tongue (Card specimen) [With Plate V, fig. 2] Exhibited by W. B. Hadden, M.D. 135
31. Primary cancer of pancreas (Card specimen)
Exhibited by Percy Kidd, M.D. 136
32. Cirrhosis of liver (Card specimen)
Exhibited by Angel Money, M.D. 136
33. Deposit of lime salts in mucous membrane of hepatic ducts in an ox (Card specimen)
Exhibited by B. G. Morison, M.B. 137

PAGE

34. Intestinal obstruction resulting from adhesion of the ileum to the mesentery (Card specimen)
Exhibited by F. Taylor, M.D. 137

V. DISEASES, ETC., OF THE GENITO-URINARY ORGANS.

1. Renal calculus and abscess (traumatic?) ruptured into left pleural cavity By John R. Lunn 138
2. Alveolar sarcoma of the capsule of the right kidney By J. Knowsley Thornton, M.C. 141
3. Tests for albumen in urine By Charles Henry Ralfe, M.D. 143
4. Sarcoma of prostate and bladder, of very rapid development By Samuel West, M.D. 145
5. A sacculated bladder in a female By W. Hale White, M.D. 146
6. Large calculus with a nucleus formed of a mulberry calculus; removed from the bladder by lithotomy By George Lawson 148
7. Mucous polypus of the urinary bladder By Samuel G. Shattock 150
8. Sarcoma of a diverticulum of the bladder By W. Roger Williams 152
9. Villous sarcoma of the bladder By W. Roger Williams 156
10. Multiple growths in the bladder By John H. Morgan 157
11. Epithelioma of the bladder, from a case of hæmaturia By W. A. Berridge 161
12. Adeno-sarcoma of testis with secondary growths in the viscera, occurring in a case of cardiac malformation By Victor Horsley, B.S. 161
13. Case of testicle in the perinæum, with congenital inguinal hernia and acute hydrocele By W. Roger Williams 168
14. Incipient cystic disease of the parovarium and broad ligament [With Plate XI] By Alban Doran 169

PAGE

15. Pigmentation of the cervix uteri
By Robert Barnes, M.D. 176
16. Fibro-myoma of the uterus, becoming sarcomatous, with secondary growths in pleura, heart, and kidney [With Plate X, figs. 1, 2, and 3]
By David W. Finlay, M.D. 177
17. Extreme prolapse of uterus, bladder, and vagina, beneath the pubic arch; consequent obstruction, with dilatation of ureters and pelves of kidneys, producing structural changes in the latter By Arthur E. Barker 181
18. Double hydrosalpinx (Card specimen)
Exhibited by Norman Moore, M.D. 182
19. Primary cancer of the undescended testis; cancer of thymus; vacuolation of liver and kidneys (Card specimen) Exhibited by F. A. Mahomed, M.B. 182

VI. DISEASES, ETC., OF THE OSSEOUS SYSTEM.

1. Diaphragm in a case of rickets By Norman Moore, M.D. 185
2. Living specimen of hypertrophy of the left ramus of the lower jaw [With Plate XII]
By Christopher Heath 185
3. Hypertrophy of condyle of lower jaw
By Frederic S. Eve 187
4. Photographs of a case of osteitis deformans [With Plate XIII] By Henry Morris 188
5. Two cases of curvature of the femur, one due to osteitis deformans, the other to an injury followed by chronic inflammation By Anthony A. Bowlby 192
6. Extensive hyperostosis of skeleton, with bone softening and rickety changes, probably of syphilitic origin
By James F. Goodhart, M.D. 197
7. Extreme deformity from rachitic (?) osteomalacia
By Richard Barwell 202
8. Juvenile osteomalacia By Richard Barwell 205
9. Case of severe syphilitic disease of the facial bones and viscera.—Death from pyæmia
By Victor Horsley, B.S. 208

PAGE

10. Deep ulceration of cranium By Norman Moore, M.D. 209
11. A case of multiple exostoses
By Frederick Churchill 210
12. Alveolar sarcoma of skull; secondary growth of bladder
[With Plate XIV] By H. H. Clutton 212
13. Sarcomatous blood-cyst of spine, causing paraplegia
By W. H. Kesteven 216
14. A case of comminuted fracture of the tibia, with impaction of the anterior tibial vessels and nerve, followed by gangrene By F. Swinford Edwards 222
15. Fracture of sternum, with costo-chondral dislocation
[With Plate XV] By W. Arbuthnot Lane, B.S. 223
16. Elbow-joint from a case of scarlet fever
By Norman Moore, M.D. 225
17. Rheumatic arthritis from a Roman tomb
By Norman Moore, M.D. 226
18. Abnormality of bones and muscles near the shoulder-joint By C. B. Lockwood 227
19. A peculiar bony outgrowth from the fibula
By W. Hale White, M.D. 227
20. Congenital malformation of the skull (Card specimen)
Exhibited by Frederick Treves 228
21. Bossy calvaria (Card specimen)
Exhibited by D. B. Lees, M.D. 228
22. Dry caries of the knee-joint (Card specimen)
Exhibited by H. A. Lediard, M.D. 229

VII. DISEASES, ETC., OF THE ORGANS OF SPECIAL SENSE.

1. One-sided anophthalmos in an infant (living specimen)
By Rickman J. Godlee, M.S. 230
2. A piece of the petrous portion of left temporal bone, including part of external semi-circular canal and roof of external auditory meatus, which exfoliated from a girl aged 17 a year after the removal of a polypus (Card specimen) Exhibited by Waldemar J. Roeckel 232

VIII. MORBID GROWTHS AND TUMOURS.

PAGE

1. Mediastinal tumour; rapid growth; sudden death
By Samuel West, M.D. 233
2. A case of disseminated sarcoma
By W. B. Hadden, M.D. 236
3. A case of disseminated cancer By Percy Kidd, M.D. 240
4. Multiple ulcerating and sloughing sarcomata in various parts of the body, especially in the limbs
By Arthur E. Durham 243
5. Extensive sloughing of the neck, "nondescript," ? lympho-sarcomatous tumour [With Plate XVI, fig. 1]
By Arthur E. Durham 245
6. Sloughing lympho-sarcoma of the back, with other lesions of the skin, and internal organs [Plates XVI, fig. 2, XXIII, fig. 2] By Frederick Taylor, M.D. 247
7. Lympho-sarcoma of the back, accompanied by spreading ulceration [With Plates XVII, fig. 1, XVIII, figs. 1 and 2] By N. Davies-Colley, M.C. 258
8. Recurrent cartilaginous tumour of the head and neck
By George Lawson 261
9. Enormous osteo-sarcoma of the left femur in a boy
By Arthur E. Durham 265
10. Calcified round-celled sarcoma of the bones of the leg
By W. Roger Williams 267
11. Melanotic spindle-celled alveolar sarcoma and gland (Card specimen)
Exhibited by Henry A. Lediard, M.D. 269
12. Carcinoma of omentum (Card specimen)
Exhibited by Bedford Fenwick, M.D. 269

IX. DISEASES, ETC., OF SPLEEN, SUPRA-RENAL CAPSULES, AND THYROID.

1. Addison's disease without melasma causing death by syncope, apparently from seasickness
By James F. Goodhart, M.D., for W. Withers Greene 270

PAGE

2. Dissection of the abdominal sympathetic from a case of Addison's disease (Card specimen)
Exhibited by J. F. GOODHART, M.D. 271

X. DISEASES OF THE SKIN.

1. Bromide rash simulating erythema nodosum
By P. HORROCKS, M.D. 272
2. Unusual bromide rash (Living specimen)
By P. HORROCKS, M.D. 273
3. Case of keloid following lupus scraping and the subsequent development of keloid in other operation wounds
By H. H. CLUTTON 273
4. A case of so-called xanthoma tuberosum [With Plate XX, figs. 1 and 2] By MALCOLM MORRIS 278
5. Case of symmetrical gangrene [With Plate XXI]
By REGINALD SOUTHEY, M.D. 286
6. The bacilli of leprosy [With Plate XXII, figs. 1, 2, 3, and 4]
By GEORGE THIN, M.D., for J. D. HILLIS, M.D., of Demerara 289

XI. MISCELLANEOUS SPECIMENS.

1. Anthrax of face [With Plate XVII, fig. 2, Plate XVIII, fig. 3] By N. DAVIES-COLLEY, M.C. 291
2. A case of charbon, or malignant pustule [With Plate XVII, fig. 3, and Plate XIX] By THOMAS BRYANT 293
3. Micrococci in pyæmia By VICTOR HORSLEY, B.S. 298
4. Two specimens of congenital hypertrophy or giant-growth of limbs. 1. Congenital hypertrophy of the foot and leg, especially of the skin and subcutaneous tissue of the sole. 2. Congenital hypertrophy of the hand and forearm [With Plate XXII, fig. 5]
By FREDERIC S. EVE 298
5. Cysts containing clear fluid, probably dilated lymphatic spaces By ARTHUR E. BARKER 304

PAGE

6. Tænia elliptica (Card specimen)
Exhibited by F. Charlewood Turner, M.D. 306
7. Ascaris mystax *v.* Alata (Card specimen)
Exhibited by F. Charlewood Turner, M.D. 307

XII. DISEASES, ETC., OF THE LOWER ANIMALS.

1. The pathology of canine chorea
By W. B. Hadden, M.D. 308
2. Rickets in a baboon By J. B. Sutton 310
3. Rickets in a baboon (Cynocephalus porcarius), West Africa [With Plate XX, fig. 3] By J. B. Sutton 312
4. Bone disease in animals. By J. B. Sutton 315
5. Pyæmia in a male python (♂ Python sebæ). West Africa By J. B. Sutton 323
6. Two hundred abscesses in the liver of a kangaroo
By J. B. Sutton 325
7. A remarkable case of parasites (Card specimen)
Exhibited by J. B. Sutton 325
8. Retroflexion of the uterus in a baboon (Card specimen)
Exhibited by J. B. Sutton 326
9. Two specimens of urinary calculi from animals, composed of carbonate of lime (Card specimen)
Exhibited by Samuel G. Shattock 326

XIII. DISCUSSION UPON THE MORBID ANATOMY OF DIABETES. 328

REPORTS OF THE COMMITTEE ON MORBID GROWTHS.

PAGE

1. On Mr. Roger Williams's tumour in a diverticulum of the urinary bladder (J. F. Goodhart and H. T. Butlin) . 156
2. On Mr. H. H. Clutton's case of tumour of the skull (Marcus Beck and R. J. Godlee) . . . 215
3. On Mr. W. H. Kesteven's specimen of blood-cyst of the spinal column (Marcus Beck and R. J. Godlee) . 220
4. On Dr. W. B. Hadden's specimen of disseminated sarcoma (H. T. Butlin and Jas. F. Goodhart) . . 239
5. On Mr. George Lawson's case of recurrent cartilaginous tumour of the lower jaw (J. F. Goodhart and Henry T. Butlin) 264

REPORTS OF OTHER COMMITTEES.

1. On Dr. Norman Moore's specimen of fibrous structures resembling valves in the left ventricle of the heart (J. F. Payne, P. H. Pye-Smith, and S. Coupland) . 30
2. On Dr. Handfield Jones's specimens of obstruction of the cerebral vessels by atheroma (S. Coupland and J. F. Payne) 60
3. On Dr. Sharkey's specimen of syphilitic inflammation of the capsule of the liver (S. Coupland and J. F. Payne) 122
4. On Dr. J. F. Goodhart's specimen of extensive hyperostosis, with bone softening and rickety changes (C. Hilton Fagge, Warrington Haward, T. Barlow, and J. F. Goodhart) 201
5. On Mr. Malcolm Morris's case of so-called xanthoma in connection with diabetes (H. R. Crocker, A. Sangster, and Jonathan Hutchinson) . . . 284
6. Report of committee appointed to investigate the changes exhibited by specimens of the nervous centres in cases of diabetes submitted for examination by speakers in the discussion on the morbid anatomy of diabetes (Geo. H. Savage, W. R. Gowers, and J. F. Payne) . 397

LIST OF PLATES.

		PAGE
I.	Holes in the Brain. (Drs. SAVAGE and HALE WHITE.) (Page 1)	8
II.	Fig. 1. The Nerves of Infantile Paralysis. (Dr. W. EDMUNDS.) (Page 15) . .	16
	Figs. 2, 3, 4. Nerves after Amputation. (Dr. HALE WHITE.) (Page 16) . .	
III.	Encephalocele. (Mr. SUTTON.) (Page 18) .	18
IV.	Atheroma of the Cerebral Vessels. (Dr. WILKS for Dr. HANDFIELD JONES.) (Page 55) . .	56
V.	Fig. 1. Acute Yellow Atrophy of Liver. (Dr. CAYLEY.) (Page 127) . .	128
	Fig. 2. Tubercular Disease of Tongue. (Dr. HADDEN.) (Page 135) . .	
VI.	Acute Yellow Atrophy of Liver (Chromo-lithograph). (Dr. CAYLEY.) (Page 127) . . .	128
VII.	Fig. 1. Syphilitic Arteritis. (Dr. SHARKEY.) (Page 10) . . .	118
	Fig. 2. Syphilitic Perihepatitis. (Dr. SHARKEY.) (Page 118) . . .	
	Fig. 3. Acute Yellow Atrophy of Liver. (Dr. CAYLEY.) (Page 127) . .	
VIII.	Secondary Epitheliomatous Nodules in the Skin. (Dr. FINLAY.) (Page 102) . . .	102
IX.	Figs. 1 and 2. Columnar Epithelioma of Stomach. (Dr. FINLAY.) (Page 102). .	132
	Fig. 3. Lardaceous Liver. (Dr. CHARLEWOOD TURNER.) (Page 131) . .	
X.	Figs. 1 to 3. Malignant Myoma of the Uterus. (Dr. FINLAY.) (Page 177) . .	178
	Figs. 4 and 5. Phlegmonous Gastritis. (Dr. SILCOCK.) (Page 90) . . .	
XI.	Cysts of the Broad Ligament. (Mr. ALBAN DORAN.) (Page 169)	172
XII.	Hypertrophy of the Lower Jaw. (Mr. HEATH.) (Page 185)	186

		PAGE
XIII.	Photographs of Osteitis Deformans. (Mr. HENRY MORRIS.) (Page 188) . . .	188
XIV.	Alveolar Sarcoma of Skull. (Mr. CLUTTON.) (Page 212)	212
XV.	Fracture of the Sternum. (Mr. ARBUTHNOT LANE.) (Page 223)	224
XVI.	Fig. 1. Lympho-sarcomatous Ulceration of Neck (Chromo.). (Mr. ARTHUR DURHAM.) (Page 245) . . . . . Fig 2. Lympho-sarcomatous Ulceration of Back. (Chromo.). (Dr. FREDERICK TAYLOR.) (Page 247)	246
XVII.	Fig. 1. Lympho-sarcomatous Ulceration of Back (Chromo.). (Mr. DAVIES-COLLEY.) (Page 258) . . . . . Fig. 2. Anthrax of Face (Chromo.). (Mr. DAVIES-COLLEY.) (Page 291) . . . Fig. 3. Anthrax of Face (Chromo.). (Mr. BRYANT.) (Page 293) . . .	258
XVIII.	Figs. 1 and 2. Lympho-sarcomatous Ulceration of Back. (Mr. DAVIES-COLLEY.) (Page 258) . Fig. 3. Anthrax. (Mr. DAVIES-COLLEY.) (Page 291)	258
XIX.	Intestinal Anthrax (Chromo.). (Mr. T. BRYANT and Dr. MAHOMED.) (Page 294) . .	294
XX.	Figs. 1 and 2. Xanthoma Tuberosum. (Mr. MALCOLM MORRIS.) (Page 278) . Fig. 3. Rickets. (Mr. SUTTON.) (Page 312)	278
XXI.	Symmetrical Gangrene. (Dr. SOUTHEY.) (Page 286)	286
XXII.	Figs. 1 to 4. The Bacilli of Leprosy. (Dr. THIN for Dr. HILLIS.) (Page 289) . Fig. 5. The Skin of a Giant Limb. (Mr. EVE.) (Page 298) . . .	290
XXIII.	Fig. 1. Diabetic Kidney. (Dr. SEYMOUR TAYLOR.) (Page 366) . . . Fig. 2. Sarcomatous Ulceration of Back. (Dr. FREDERICK TAYLOR.) (Page 247) .	366
XXIV.	Diabetic Kidney. (Dr. STEPHEN MACKENZIE.) (Page 364)	366
XXV.	Charts Showing the Ages of Deaths from Diabetes. (Dr. DAWSON WILLIAMS.) (Page 385) .	384

WOODCUTS.

PAGE

1. Larynx from an infant the subject of obstructed inspiration (Dr. D. B. Lees) 20
2. } Double obturator hernia (Mr. A. A. Bowlby) 110—11
3. }
4. Large calculus, with a nucleus formed of a mulberry calculus (Mr. George Lawson) . . . 149
5. Adeno-sarcoma of the testis; tracings of the venous and radial pulse (Mr. Victor Horsley) . . . 149
6. Hypertrophy of the left ramus of the lower jaw (Mr. Christopher Heath) 186
7. Extreme deformity from rachitic osteomalacia (Mr. R. Barwell) 208
8. Sarcomatous blood-cyst of spine (Mr. W. H. Kesteven) . 218
9. Ditto microscopical structure of sarcoma (Mr. Godlee, for the Committee on Morbid Growths) . 220
10. Recurrent cartilaginous tumour of head and neck (Mr. George Lawson) 262
11. Ditto portion of lower jaw, with the tumour growing from the periosteum on its inner surface (Mr. George Lawson) 263
12. Rickets in a baboon: lower extremity of the femur of a baboon, showing enlarged epiphysial line, spongioid tissue, and cartilage islets (J. B. Sutton) . . 313
13. Section of lower end of the humerus of a lizard "Indian monitor," with two cartilage tumours springing from growing line (J. B. Sutton) . . . 316
14. Metatarsal bone of South American ostrich "Rhea Darwinii," with a cartilage tumour springing from epiphysial line (J. B. Sutton) . . . 317
15. Femur of Macaque monkey split longitudinally to show widened epiphysial cartilage and extension of medullary cavity to this cartilage (J. B. Sutton) . . 319
16. Diagram to show relation of veins in "Python sebæ" (J. B. Sutton) 323

REPORT.

SESSION 1882-83.

I. DISEASES, ETC., OF THE NERVOUS SYSTEM.

1. *On the causes of holes in the brain, together with two cases of universal cystic degeneration.*

By G. H. Savage, M.D., and W. Hale White, M.D.

[With Plate I.]

It will perhaps be better to begin this paper with an enumeration of all the conditions which, as far as we know, have been said to give rise to holes in the brain. They are as follows:

1. In general paralysis small processes of the thickened membranes may dip into the surface of the brain, and when pulled out give rise to slight depressions on the surface.

2. In the same disease the sclerosed neuroglia by its subsequent contraction has been described as giving rise to the formation of cavities.

3. Multiple hydatids in the brain.

4. Chronic congestion of the cerebral vessels gives rise to the "état criblé."

5. Shrinking of the cerebral convolutions is a frequent cause of cavities in the brain.

6. Miliary aneurysms by their pressure on the brain substance produce holes in it.

7. In some brains large single cavities are found, and the brain is called porencephalic.

8. The Gruyère cheese condition caused by dilatation of the perivascular lymph spaces.

9. General cystic degeneration affecting the brain, together with other viscera.

Of course in the above enumeration we have not included such

causes as cystic tumours, hæmorrhagic tumours, new growths breaking down, patches of softening, growths from the outside pressing on the brain and absorbing it, because these, as a rule, only produce a single hole, and they are sufficiently understood to require no further comment. The same remark applies to any cavities produced by injury.

We will now discuss these nine varieties *seriatim*.

First.—It is obvious that any cavities which may be produced by processes of the inflamed meninges dipping into the brain in general paralysis must be very small and of but slight importance. They are by no means constantly present in that disease and have been well described by Luys.[1]

Secondly.—The formation of cavities, owing to the contraction of sclerosed neuroglia in general paralysis, has been described by Durand Fardel,[2] who speaks of the formation of cavities "remplis par un liquide troublé, blanchâtre designé par M. Cruveilhier et M. Dechambre sous le nom de lait de chaux." Although we have examined a large number of brains from general paralytics, we have no knowledge of this condition, and are inclined to doubt its actual existence. Luys[3] speaks of depressions on the surface due to contraction of the neuroglia, which in general paralysis has become sclerosed, and the same author also describes what he calls an areolar appearance, the white and grey matter being pierced by a series of orifices as though with a punch, and he compares the result to canvas or muslin. Schüle[4] describes the same condition, and we have seen something like it, but it is more an appearance produced by fibres crossing at right angles than any real cavitation.

Thirdly.—Multiple hydatids in the brain in man are very rare, but it is common in sheep suffering from staggers for the whole brain to be full of hydatid cysts, and the walls of these have fallen out of the cavities they have excavated for themselves in the cerebral substance. The appearance produced is not at all unlike that of the Gruyère cheese brain to be mentioned later on. It is a strange fact that multiple hydatids of the brain in man are not more common, because the *Tænia echinococcus* which gives rise to human

[1] 'Traité clinique et pratique des maladies mentales,' par J. Luys, p. 532.

[2] 'Des maladies des vieillards. Maladies de l'encephale, ramollissement chronique.'

[3] Op. cit., p. 533.

[4] 'Allgemeine Zeitschrift für Psychiatrie,' Band 32, p. 581.

hydatids is the same animal that gives rise to the multiple cerebral hydatids of the sheep, and it is difficult to understand why in the one case the disease should so frequently affect the brain, and in the other hardly ever.

Fourthly.—The chronic, or for that matter acute, congestion of the cerebral vessels which one so often sees in death from obstructed right side of the heart, or from the body having lain with the head low, or as a result of opening the skull before the rest of the body, makes them very prominent, and if on cutting the brain the blood runs out of the distended vessels, or still more if in microscopic sections the whole vessel falls out, an appearance is produced as if the brain were riddled with pin holes. This Griesinger[1] calls the "état criblé." It is most important to bear in mind that this is of no pathological importance, because of late there has been so much said about different conditions of the vessels of the brain in various nervous diseases, and there can be but little doubt that many normal conditions have been set down as abnormal. Wilks and Moxon[2] are very emphatic on this point.

The term état criblé has been very loosely used; some authors, such as Arndt[3] apply the term to what we shall presently describe as the Gruyère cheese condition of brain. It would seem better to keep the two terms distinct, because the conditions are produced by such different processes.

Fifthly.—Shrinking of the convolutions is a cause of holes in the interior of the brain, and we are able this evening to show an excellent specimen of it. Unfortunately the history is imperfect, death taking place in a county asylum; there was insane inheritance, and the patient had had epileptic fits, and had become blind.

The brain was shown at the Pathological Society on a former occasion on account of symmetrical tumours which are present, one on either side of the medulla.

We are indebted to Dr. Strahan, of Berry Wood Asylum, Northampton, for the brain.

Sixthly.—Miliary aneurysms often give rise to small holes in the brain. Some of them may dip so far into the grey matter that

[1] 'Mental Diseases,' Syd. Soc. Trans., p. 425.

[2] 'Pathological Anatomy,' p. 222.

[3] 'Virchow's Archives,' Band 63, "Zur Pathologischen Anatomie der Centralorgane des Nervensystems, Ueber den État Criblé."

places like coarse-meshed gauze; at other points, however, these meshes were so widened that they presented absolute blanks, which when they occurred reminded one at first sight in their number and irregularity of Gruyère cheese." He, however, goes on to state that they were, he considers, produced by dilatation of the perivascular space of His.

There is a case recorded by Obersteiner, junr.,[1] in which there were cavities, some of which contained fine threads and spindle cells, and also some had peculiar contents, which either "für Myelin oder für Colloidkörperchen gehalten werden können." The patient, however, had a gumma of the brain, arising, as the author considered, from the endothelial lining of the lymph space, and hence the cavities, formed by dilatation of it, naturally contained tumours, products being in fact injected by them.

Other authors, such as Meckle,[2] speak of Gruyère cheese brain, but do not explain the pathology of it. Of the cause of the saccular dilatation of the perivascular lymphatic space we are in complete ignorance. Why should it dilate in a saccular manner? Is it, possibly, the same condition of things in the lymphatic space around the cerebral vessels as occurs in arteries in miliary aneurysms? For, as the dilatation is saccular, one can hardly imagine but that it must be due to local causes, for were the cause to be the blocking of some outflow for lymph the dilatation would be uniform. This consideration should make one cautious how one attempts to explain the matter by referring it back to the subarachnoid space, which, it must be borne in mind, communicates with the perivascular lymphatic spaces; in fact, these may be looked upon as mere diverticula of the subarachnoid space accompanying the cerebral vessels.

Another anatomical fact to be remembered is that in addition to the space of His around the vessel there is the Virchow-Robin lymphatic space between the middle and external coats of a cerebral artery, and that it is quite possible for the dilatation to take place in that and not in the space of His.

Coming now to the symptoms, unfortunately in this case nothing can be said about them. The brain was taken from a patient on whom a *post mortem* had been made, but the entire brain was put in a jar of spirit with many others for anatomical purposes, and it

[1] 'Virchow's Archives,' Band 55, "Ueber Ectasien der Lymphgefässe des Gehirns," p. 318.

[2] 'General Paralysis of the Insane.'

is impossible to say now from which subject this one was taken. Considering the extensive vacuolation in such important parts as the medulla, it would be of the highest interest for the future to try and connect the symptoms with the regions in which vacuolation is found; it is to be observed, however, that the vacuolation diminishes as important centres are neared, being quite absent in the lower part of the medulla.

Ninthly.—There have come under our notice two general paralytics, Coare and Cresswell, in both of whom there has been cystic degeneration of the kidneys, liver, lungs, muscular fibre of the heart, and the brain, producing in the latter organ cavities, very like the Gruyère cheese condition last mentioned. These cases are, as far as we are aware, the only ones of their kind that have been recorded. Dr. Pye-Smith[1] has lately given such an exhaustive account of those rare examples in which cysts of the kidney and liver are associated, that it is needless for us to refer in any way to those cases; but he has informed us, that in his researches in the literature of the subject he came across nothing like our two examples of universal cystic change.

Taking first the kidney, sections appear to show that in our cases, as in Dr. Pye-Smith's, the cystic change is due to dilatation of either the Malpighian capsules or cortical tubules. And in the liver also our specimens agree with his, because the cysts appear to be due to small vacuoles in the hepatic cells, which we have proved not to be fatty by their refusal to stain with osmic acid. The several vacuoles in the same cell, by increase in size, run together to form one that occupies nearly all the cell, which, being so distended, bursts. The vacuoles of adjacent cells thus coming together, soon form one large cyst. This is very well shown in one of the figures. By this process in parts of the liver the cysts produced are so numerous that the whole organ has the appearance of a sponge; this is very well shown on holding up one of the microscopic slides. The presence of the cysts exerts pressure on the surrounding liver cells, which have a look that at once suggests that they have undergone pressure. We do not think that these hepatic cysts have any true wall, but the appearance of one is often produced by the cyst in the course of its enlargement coming in contact with some fibrous tissue, which it stretches and pushes before it, so that at last it appears to have a

[1] 'Path. Trans.,' 1881.

thin lining membrane. There is, of course, the possibility that the cysts are due to dilatation of the ducts; such a mode of formation is mentioned by various authors who have written about the liver; the only point in favour of this view to explain our cases is, that in one or two of the cysts a small quantity of yellowish amorphous material may be found; but even if this is bile pigment we do not think it goes for much when we consider that these cysts arose by a breaking of the very cells that secrete the pigment, and that in the course of their enlargement they are very likely to come across a duct and open it. Then again we should, if they were due to dilatations of the ducts, expect to find some interstitial hepatitis to account for the compression of the ducts, and also we should expect that the cysts would have a distinct lining derived from these ducts. Probably, however, this material seen in some of the cysts is not connected with bile at all, for a similar material may be found in the renal cysts.

Turning now to the lungs we are here in a great difficulty, and, although we have examined many sections, feel quite unable to say how the cysts arose. The cavities are mostly circular, and not connected with bronchial tubes; they contain no true lining membrane, although sometimes looking as though they possessed one, but this is owing to the surrounding lung tissue having become condensed at the margin of the cyst. They have a tendency to occur in groups, and seem to be situated indiscriminately among the air-cells, from which they are distinguished by their regular shape and by their containing no granular epithelial *débris* which, owing to the lung having undergone some slight chronic pneumonic change, fills the air-cells, but in many cases the cysts have in their interior a peculiar amorphous matter which takes the logwood stain with great brilliancy. Most of the cysts in the lung and brain contain this material, and in one of the cut bronchial tubes masses of something very like it are to be seen, the only difference being that in the tubes it does not stain so deeply with logwood. In some sections it looks as though some of this matter lay in the alveoli, but it is not always easy to decide whether we are not dealing with a cyst cut in some peculiar direction. It is obvious how difficult it must be to determine the origin of cysts in the lung; that organ being naturally a mass of cysts containing air. The only point to be made out with certainty is, that the larger cysts are due to the coalescence of several smaller ones.

DESCRIPTION OF PLATE I,

Illustrating the paper by Dr. Savage and Dr. Hale White, on the Causes of Holes in the Brain, together with two cases of Universal Cystic Degeneration. (Page 1.)

From drawings by Dr. Hale White.

FIG. 1.—A miliary aneurism depressing the surface of the brain. As the distended vessel grows deeper into the brain the depression will at last become a hole immediately under the surface of the brain. (Hartnack, oc. 3, obj. 3.)

FIG. 2 shows the naked eye appearance of a section of a Gruyère cheese brain. It will be seen that many of the cavities have an elongated shape suggesting that they have been formed around vessels.

FIG. 3 shows a hole in the brain from one of the cases of universal cystic degeneration. It has no lining membrane, but the shaded contents indicate a substance that took the logwood stain deeply. (Hartnack, oc. 3, obj. 7.)

FIG. 4.—Some hepatic cells from one of the cases of universal cystic degeneration; it shows how the larger cysts are formed by the running together of several smaller ones. (Hartnack oc. 3, obj. 8.)

FIG. 5.—Two cysts in the lung containing deeply staining material, the air-cells are filled with granular débris. (Hartnack, oc. 3, obj. 7.)

Fig II

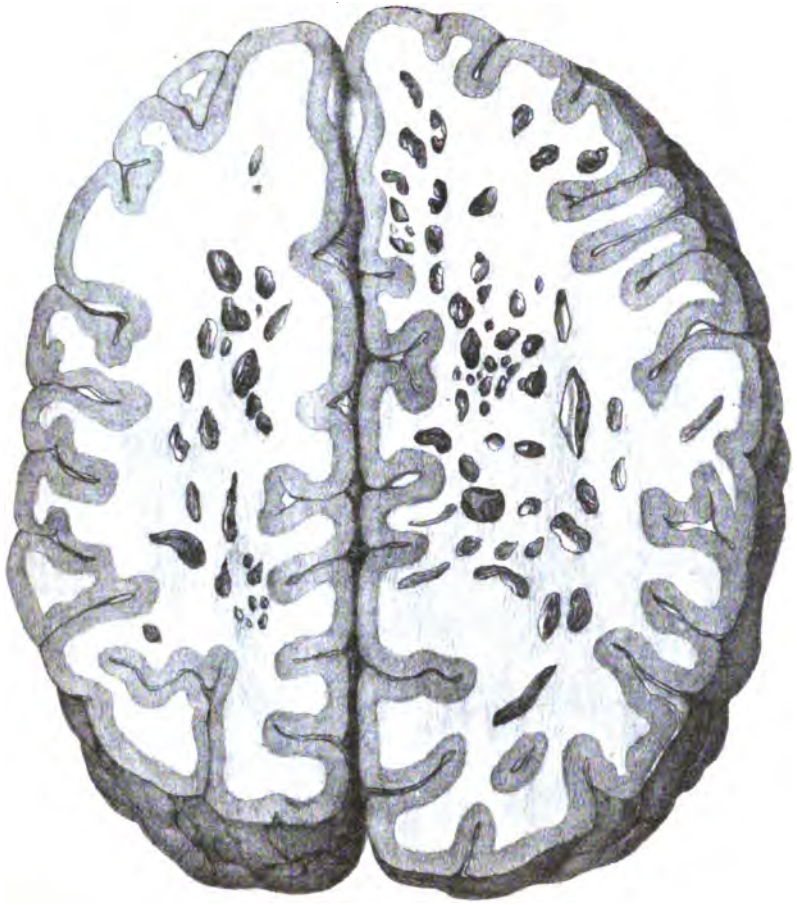

Fig I

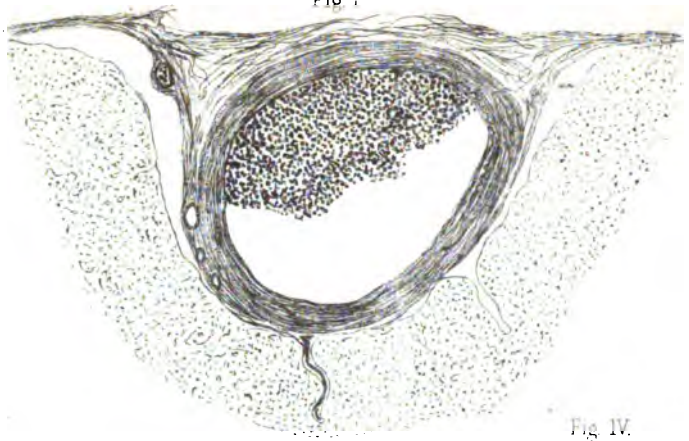

Fig IV.

Fig III



Fig V

The cysts in the heart were not numerous; they contained no lining membrane, and were regular in shape, being circular or oval.

In the brain there are many cavities in shape like those already described in the Gruyère cheese brain; in fact, probably many pathologists would take the brains from these two cases to be examples of that condition, but for many reasons we prefer to separate them.

Thus we have been able to account to a certain extent for the holes in the Gruyère cheese brain, but here we cannot do so satisfactorily. Then again these examples occurred in cases in which there were cysts in other organs, and those in the brain showed their similarity to these by containing the same deeply-staining substance. These cerebral cysts were cleanly punched out; they contained no lining membrane, and, as has just been mentioned, several had within them the same deeply-staining substance we have just seen to be present in the lung. What, then, can be the cause of these cysts? Are they due to the contraction of the hypertrophied neuroglia? We think not, for, in the first place, the increase of neuroglia is slight, not more than sufficient to make it seem about as prominent as that in the cord usually is; secondly, because some of the cavities contain this deeply-staining material; and thirdly, they are too regular in shape.

Next, there is the hypothesis that contracting neuroglia has at intervals pressed upon the lymph space around the vessels, and thus caused a varicose dilatation of the lymphatic space; but the objection to that view is that the cysts contain that deeply-staining fluid, and also that the lymphatic spaces are not dilated.

There is yet one more suggestion, namely, that some sort of degeneration has gone on in the nerve-cells (possibly similar to that in the hepatic cells) which has resulted in the disintegration of the cell and the formation of a cavity in its place. This is borne out by the fact that some of the nerve-cells certainly seem small, little but the nucleus remaining, and round such as these there is a larger space than usual. A somewhat similar process has been described by Popoff[1] in an article in which he says that blood-cells wander out of the vessels, eat their way into the nerve-cells, and, finally, the latter disappear and a hole is left. But this explanation, by

[1] 'Virchow's Archives,' Band 63, "Ueber Veränderungen im Gehirn bei Abdominaltyphus und traumatischer Entzündung."

which it is assumed that the processes begin in the cells, fails to explain the presence of the deeply-staining fluid, and also how the spaces become so big, for, after the nerve-cell is destroyed, there seems no obvious reason why the holes should run together. We are, then, forced to confess that the origin of this condition of brain is by no means clear. *May 15th*, 1883.

---

2. *Case of arteritis with thrombosis of both middle cerebral arteries occurring during the secondary stage of syphilis.*

By Seymour J. Sharkey, M.B.

[With fig. 1, Plate VII.]

E. C—, aged 36, came under the care of Mr. Nettleship on August 11th, 1881, owing to some defect in the sight of the right eye. He had at this time a syphilitic eruption on the forehead and bends of the elbows, and on being questioned he stated that he had had a chancre three months previously.

Mr. Nettleship, finding no positive changes in the eye, wrote on the out-patient ticket, "? Commencing retinitis." A fortnight later there were symptoms resembling iritis, accompanied by diminished tension. The fact that the iritis did not develop, and that the tension was rather diminished, pointed, Mr. Nettleship thought, to the attack being probably one of incipient cyclitis or choroiditis, such as may take the place of iritis in secondary syphilis. During September he hardly came to the hospital, as the eye was getting better, though still painful. He also had some pain in the head about this time, which disappeared as the eye got well.

On October 17th the eye was well, but the patient was suffering from pain in the right side of the head. This got worse, and giddiness likewise occurred, and Mr. Nettleship transferred the case to Dr. Payne's care.

The ophthalmoscope revealed no morbid changes in the eye.

While attending Mr. Nettleship during August (for he absented himself during the greater part of September) he was treated with small doses of blue pill (three grains) three times a day, and with iodide of potash, which was given first in five- and then in ten-grain doses.

Dr. Payne first saw the patient on November 8th, 1881, and

wrote down that he was suffering from headache and a syphilitic eruption.

A few days after this the patient was found by his friends in a semi-comatose condition, with convulsions of all the limbs, and he remained in this condition until he was admitted into the hospital under the care of Dr. Payne on November the 17th.

As far as could be ascertained, the patient had been a healthy man until he contracted syphilis about May, 1881, after which he suffered in the way already described.

About five weeks before admission into the hospital he was said to have fallen down, and remained insensible for two hours.

On admission he was described as a badly nourished man, of miserable appearance, with countenance sullen and somewhat fatuous, and with nearly complete loss of power in the right arm, and partial loss of power in the left leg. All over the body, face, and back were coffee-coloured maculæ, the relics of a previous eruption, and on each nipple there were scabs. Mental power was at a very low ebb, the patient being unable to answer questions or to understand what was said to him, and constantly making attempts to get out of bed.

There appeared to be slight facial paralysis on the right side, as the eyelid drooped, and the left angle of the mouth was drawn up. The tongue was protruded straight, but the left pupil was smaller than the right, and both acted badly to light. Speech was very thick and slow. The right arm fell heavily when raised, and the patient could not stand alone. When assisted he walked in a tottering manner and dragged the left leg.

There was no loss of sensation detected anywhere. The patellar reflex was rather increased in both legs, and there was no ankle clonus.

Chest and abdomen were natural; pulse 90, respirations 24; the tongue moist and slightly coated; bowels open; appetite good; temperature on admission 97·6°.

Urine 1030, acid, much albumen present, and a deposit of lithates.

November 19th.—The patient said to be much in the same condition, except that the tongue was thickly coated.

21st.—Much more drowsy and stupid; slight internal strabismus of right eye; left pupil much smaller than right; breathing heavily. Temp. 97°, pulse 96.

23rd.—In a comatose condition; motions passed unconsciously; difficulty in swallowing; breathing somewhat stertorous. Pulse 128, temp. 100·8.°

24th.—Still comatose. Temp. 102°, pulse 160. Breathing somewhat of the "Cheyne-Stokes" variety, a series of energetic respirations alternating with a series of quieter ones. The eyes are sometimes turned to the right, sometimes straight forward. The left hand and right leg drop heavily when raised; the right hand and left leg are rigid.

After a succession of short convulsive fits, each accompanied by complete rigidity of all the limbs, and lasting about one minute, he died, the temperature rising just before death to 107°.

On *post-mortem* examination I found the body moderately well nourished. There were copper-coloured stains of old eruptions on the arms and trunk. Both nipples were occupied by thin scabs, like those of eczema.

Lungs were somewhat collapsed and œdematous, and dotted with small hæmorrhages. The pleuræ were healthy.

The heart was normal.

The kidneys had slightly adherent capsules, and on removing the latter the surface of the organs was finely granular.

Liver and spleen were healthy.

Brain.—Dura mater was thick and somewhat adherent to the vertex of the skull. Pacchionian bodies very large. A good deal of subarachnoid fluid present. The arachnoid at the base was slightly opaque, but there was no meningitis to be seen anywhere.

The middle cerebral artery on the left side was blocked (but not completely, a narrow channel still remaining open) by a thrombus, which was hard, white, and somewhat adherent to the walls of the vessel. This extended some distance into the posterior communicating artery of the same side. There was no evident softening of the convolutions on that side, but the anterior and external portion of the extra-ventricular nucleus of the corpus striatum was broken-down into a red, semi-fluid mass.

On the right side the middle cerebral artery appeared to be completely occluded by a thrombus, which was much more recent than that on the left. It was dark coloured, except near the wall of the vessel, where it was paler. It was firm, but not nearly so firm as that on the left.

The convolutions of the frontal lobe on the right were all decidedly

softened, and the whole lobe was smaller than its fellow of the opposite side. The extra-ventricular nucleus of the right corpus striatum was softened much in the same way, and in the same region as that on the left side.

The ventricles of the brain were moderately distended with serum.

Except for the pathological changes mentioned the brain appeared to be healthy.

Microscopical examination of the middle cerebral arteries showed changes some of which were due to chronic, some to recent disease. The older affection consisted of a fibroid thickening of the sub-endothelial connective tissue of the intima, occurring in patches and not uniformly round the vessels. The most striking alterations, however, were of an acute character, and affected most intensely the external coat of the arteries. In some parts of the vessel the adventitia alone was infiltrated with young cells, which accumulated around and in the coats of the greatly distended vasa vasorum, and dissected out the bundles of connective tissue found naturally in the external coat of large arteries. In other places this round-celled infiltration passed inwards through the muscular coat, invading the whole thickness of the vessel as far as the internal elastic lamina, and forcing the muscular fibres apart. Everywhere, however, it was clear that the brunt of the disease fell upon the external coat and had commenced in it (Plate VI, Fig. 1).

In the right middle cerebral artery the clot was quite recent, red in colour, and consisted of ordinary coagulum; but on the left side it was in an advanced stage of organisation except in the centre, and towards one side of the vessel, where a small space was occupied by recent clot.

In the case of the middle cerebral artery of the right side, in which there was a recent clot, only the external coat of the artery seemed to be infiltrated, while on the left side, where the thrombus was much older, both the external and middle coats were in an advanced stage of disease.

In one of the sections of this vessel there was a large nodular swelling of the external coat seen with the microscope, which consisted of a small round-celled infiltration, and was in fact a gumma in an early stage of development. In another part of the same vessel a similar growth in the muscular coat below the internal elastic lamina had undergone softening and granular degeneration.

While the vasa vasorum in both the middle and external coats were enormously distended, there was little if any evidence of disease of the internal coats of these nutrient vessels, although such changes have been described, and do occur, in some cases of syphilitic new growths.

The special points of interest in this case are—

1. The very early stage of syphilis at which the arterial disease occurred, proving fatal in the seventh month after the primary chancre.

2. The symmetrical distribution of the disease, which affected the middle cerebral artery on both sides.

3. The fact that the external coat of the vessels was the starting point of the pathological changes, and that the intima was unaffected.

As regards the first point, observation has led us to consider arterial disease as one of the later results of syphilis, and I do not know of any recorded case in which death took place from this cause at so early a period as the seventh month. It is interesting to note too that the disease in this case not only occurred during the presence of the secondary eruption, but that it also presented the symmetry which is more usual during this than during the tertiary stage of syphilis.

In the greater number of cases hitherto reported the disease seems to have originated in the intima, producing a concentric narrowing of the vessel. In the present instance it evidently attacked the external coat and spread inwards. Other cases are recorded where the changes appeared to have similarly commenced in the adventitia; and it is not at all improbable that where many vessels are affected in the same individual some have the primary changes in the internal, some in the external coat.

For the greater part of the clinical history of this case I am indebted to my friends Dr. Payne and Mr. Nettleship.

January 16th, 1883.

3. *Spinal nerves from three cases of infantile paralysis.*

By WALTER EDMUNDS, M.D.

[With fig. 1, Plate II.]

THE three patients from whom these specimens were obtained had each suffered in early life from infantile paralysis affecting one leg.

At about the age of fifteen or sixteen the limb, being completely useless, was removed as an encumbrance.

The specimens are transverse sections of the internal popliteal nerves of these limbs.

The specimens show some healthy nerve-fibres, others which are much smaller and in which the axis cylinder is much wasted or degenerated. Traversing the various nerve bundles are seen strands of connective tissue formed by an hypertrophy of the endo-neurium.

The peri-neurium is but slightly if at all increased.

The vessels in the nerve show some inflammation of their coats, with proliferation of their endothelium. It is supposed that the healthy nerve-fibres are the sensory fibres, and the degenerated the motor fibres.

The specimens being from long-standing cases throw no light on the condition of the nerves in the early stages of the disease.

Similar changes in the nerves have been described by Déjerine[1] and Schultze.[2] As to the vessels, Dr. Turner has found them much affected in the spinal cord from an early case of anterior polio-myelitis.[3] *Dec.* 19*th*, 1882.

---

[1] 'Arch. de Physiologie,' 1875.

[2] 'Virchow's Arch.,' vol. 68 (1876).

[3] 'Path. Soc. Transactions,' vol. xxx (1879).

4. *Amputation changes in nerves.*

By W. Hale White, M.D., and Walter Edmunds, M.D.

[With figs. 2, 3, and 4, Plate II.]

A series of neuromata having lately come under our observation, we thought that some account of them might be of value as but very few are recorded in the Society's 'Transactions,' and also because there are one or two points to which we wish to call attention.

In the first place we show several specimens of neuromata at the end of amputation or the proximal end of cut nerves. They consist of a large number of nerve-fibres coiled up in masses, which are held together to form one tumour by a large amount of fibrous tissue. In nearly all the specimens the coiled nerves have undergone such degeneration that they are little more than masses of connective tissue derived probably from the peri-neurium, and of a finer kind than that in which they are embedded. In the specimen taken from a case in which the limb had been amputated six years previously, the degeneration shows itself so extreme that the nerve consists of a granular and fatty mass (fig. 2), whilst in one in which amputation had only been done one year previously there is as yet no fatty change, but a large multiplication of nuclei together with an ingrowth of peri-neurium (fig. 3). The reason why these coiled fibres degenerate is doubtless because they have no use. It thus appears that in the adult of the higher vertebrata the only tissue of a limb that can reproduce itself after amputation is the nervous, but as no other parts grow there are no muscles and skin for the nerves to supply, consequently they coil up and subsequently degenerate.

In the fœtus the case is different, for Sir James Simpson gives instances in which after amputation of limbs *in utero* by bands a rudimentary hand or foot has grown upon the stump ('Monthly Journal of Medical Science,' Edinburgh, 1848, new series, vol. ii, p. 890), whilst in amphibia and other lower animals there are numerous instances of regeneration (Darwin, 'Animals and Plants under Domestication,' vol. ii, p. 15).

Dreschfeld ('Journal Anat. and Physiol.,' vol. xiv), in his sum-

DESCRIPTION OF PLATE II.

FIG. 1. To illustrate Dr. Edmunds's paper upon the Nerves of Infantile Paralysis. (Page 15.) Magnified 333 diameters.

From a drawing by Mr. C. Stewart.

FIGS. 2, 3 and 4. To illustrate Dr. Edmunds's and Dr. Hale White's paper on Amputation Changes in Nerves. From drawings by Dr. Hale White. (Page 16.)

FIG. 2.—Tumour at the end of an amputated sciatic nerve. Six years intervened between the operation and death. Nerve bundles which have undergone fatty degeneration are lying in masses of fibrous tissue. (Hartnack, obj. 7, oc. 3.)

FIG. 3.—Fibrous tumour in the stump of a median nerve. The only trace of the nerve structure that remains is the occasional presence of an axis cylinder.



Fig 1.

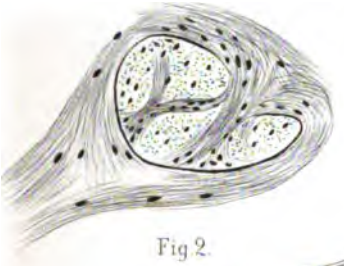

Fig 2.

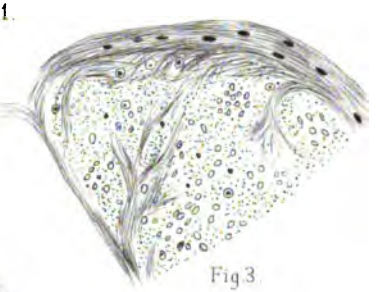

Fig 3.

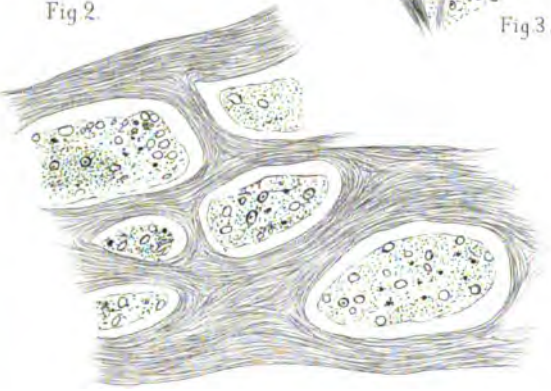

Fig 4

mary of the literature concerning the condition of the cord after amputation of the limb, says, "Changes in the trunks of the large peripheric nerves are recorded in only one case of Dickinson's. Vulpian and others, and amongst them myself, have not detected any changes in the peripheric nerves." Our sections, however, show that degeneration takes place in the nerve, which is what one *a priori* would expect, seeing that the muscles to which and the skin from which it used to convey impressions have been removed. Thus, in the case of a girl who died some years after amputation through the thigh, the great sciatic nerve shows an increase of connective tissue between the nerve-fibres, which has in many cases so invaded them as to cause their complete obliteration; and in some few instances the axis cylinder has disappeared leaving the white substance of Schwann surrounded by connective tissue (fig. 3). It will be noticed on reference to fig. 3 that the sciatic nerve does not show the same amount of fatty degeneration as the curled nerve bundles of the neuroma from the same case (fig. 2), and furthermore, the neuroma from the nerve of a limb which was not amputated so long before death shows little or no fatty change. This would seem to point to the fact that the first process was a sclerotic one beginning in the nerve tumour and spreading up the nerve, but that even this sclerosed tissue in time undergoes fatty degeneration. This view is borne out by Hayem ('Arch. de Physiol.,' 1873, p. 511), who, after tearing out the sciatic nerve of rabbits, found sclerosis of the posterior nerve roots. In some sections of this sclerosed sciatic nerve healthy nerve bundles are to be seen, but they are in all probability connected with parts functionally active seated above the amputation, and if sections were made progressively higher and higher up the nerve it would doubtless be found that [illegible] of such healthy bundles increased proportionately. U[illegible] the lumbar spinal cord was lost, but authors seem [illegible] as to the atrophic changes in the cells of the lumbar [illegible]edio-lateralis, that this misfortune is not to be re[illegible]ch as if the nature of the changes were still unsettled. [illegible] dorsal cord was perfectly healthy. Other sections [illegible]edian nerve just below a spot where it had been [illegible]e time previously; the ends had not grown to[illegible] The piece from which the section is taken terminated in [illegible]t, there being no coiled tumour on the lower end, and, as might [illegible]expected, the fibres are completely replaced by connective

tissue, all of them, both afferent and efferent, being functionally inactive.

The last specimen we bring before the Society is the end of a digital nerve, from a case in which the finger had been amputated two or three years previously for a tumour. The section shows nerve bundles which are undergoing the same degeneration as in the neuromata already described, but they are surrounded by a mass of round-celled sarcoma, making it extremely probable that this was the nature of the tumour for which the finger was amputated.

December 19*th*, 1882.

---

5. *Encephalocele.* (*Card Specimen.*)

Exhibited by J. B. SUTTON.

[With Plate III.]

FOR the history of the case I am indebted to Mr. P. Bentlif and Mr. Faunce, who attended the mother in her confinement.

The child was delivered after a lingering labour of about thirty-six hours. The tumour was delivered first, the head following.

The tumour was translucent and fluctuating. On pressing it with the hand it became smaller and caused the child to be slightly convulsed. The infant was perfectly formed, and could take the breast immediately after delivery.

It lived six weeks; three days before its death it became comatose, and remained so to the end.

The cyst, which is larger than the head of the child, is formed by a dilatation of the fourth ventricle; it contains a portion of choroid plexus hanging freely in its cavity. The square-shaped mass of brain substance lying behind the occipital bone represents the corpora quadrigemina, and the fourth nerve could be distinctly traced to it. The cerebellum is rudimentary.

May 15*th*, 1883.

DESCRIPTION OF PLATE III.

To illustrate Mr. Sutton's Case of Encephalocele. (Page 18.)

Side of cyst, portion of occipital and parietal bones, and half the cerebrum removed. The fourth nerve is seen passing backwards to the corpora quadrigemina, situated on the posterior aspect of the occipital bone. The arrow lies in the *iter a tertio ad quartum ventriculum*.

ENCEPHALOCELE.

T. Huth. Lith. Edin.

II. DISEASES ETC., OF THE ORGANS OF RESPIRATION.

1. *A lobulated lamellar fibroma on the pleura.*

By F. Charlewood Turner, M.D.

The specimen consists of a portion of the base of a lung, to which is attached, near its inferior border, a pedunculated body of lobulated form, somewhat resembling that of a piece of coral. It is of a firm elastic consistence and of white colour, resembling cartilage. Thin sections examined under the microscope show a laminated structure like that of laminated blood clot.

There were fibroid changes, with puckering of the apices of the lungs, and some loose fibrous pleuritic adhesions of old date, but not in the neighbourhood of the pedunculated body.

January 2nd, 1883.

---

2. *Larynx from an infant which had been the subject of a peculiar form of obstructed inspiration.*

By David B. Lees, M.D.

The larynx now exhibited to the Society was taken from an infant of a year old, which had, during its whole life, manifested a peculiar noisy respiration. Each inspiration was accompanied by a croaking sound, whilst expiration was much less affected (indeed, usually entirely free), and the cry-sound was quite clear. About a month before the child's death a laryngoscopic examination was made, and it was then seen that the upper aperture of the larynx was in the form of a narrow median slit, extending from above downwards, the epiglottis being folded on itself, so that the posterior surfaces of its lateral halves were almost in contact, and the ary-epiglottic folds close together and almost overlapping. A second

examination was attempted a month later, when it was observed that a small white diphtheritic patch was present on each tonsil. The child died three days after this. The drawing shows the condition of the larynx as seen about two days after death.

The epiglottis is much curled inwards, even more than it usually is in infants. The aryteno-epiglottic folds are in close proximity (Woodcut 1); indeed, they seem to be in actual contact. They were quite thin and not at all œdematous when the specimen was obtained. Above them, below the centre of the folded epiglottis, is an opening of the size of a pinhole; and below them, between the arytenoid cartilages, a second and rather larger opening. The vocal cords and the rest of the interior of the larynx were healthy. The trachea was lined with diphtheritic membrane.

I have seen four cases in which this peculiar croaking inspiration was present. All four were girls. In all the condition

Woodcut 1.

appeared to be congenital, and in all fairly constant, except that occasionally exacerbations seemed to be caused by exposure to cold and by flatulence. The croak is of a lower pitch than the crow of laryngismus. It continues, though less loud, during sleep, and after the administration of chloroform. There is usually some recession above the sternum during inspiration, and slightly also at the base of the thorax; but as a rule sufficient air seems to enter the chest.

In at least one of the cases the symptom entirely passed away as the child grew. This is, I believe, the first time that the cause of obstruction has been ascertained either by the laryngoscope or by *post-mortem* examination. *December 5th*, 1882.

3. *Case of laryngeal phthisis.*

By B. G. Morrison, M.B.

K. L—, female, aged 36, married eleven years. Husband healthy. No consumption in her family nor in her husband's. Her husband's first wife (patient being the second) died of consumption, and came of a strongly consumptive family. Patient has had five children, about two years between each. Her cough dates from three years ago. For three months previous to this, while pregnant with second youngest child, she had lost her voice and suffered from suffocative attacks. Before the aphonia came on she suffered from chronic nasal colds. The loss of voice was permanent. About the time her illness began, and for four years previously, she lived on the ground floor of a house with unhealthy drainage and the cistern of which was apt to get foul.

Symptoms.—Well-marked signs of consolidation with cavity formation in upper halves of both lungs. Hæmoptysis apparently from right lung about four months ago.

Larynx.—No pain or dyspnœa. Examination with the laryngoscope showed congestion of the epiglottis, posterior and lateral upper boundaries of the larynx. The vocal cords (true and false indistinguishable) were thickened, white, with the inner edges rounded and bulged inward, and well apart in ordinary respiration, each of them slightly excavated in the posterior half. At the sound of Ee the cords met anteriorly but were separated by a triangular chink posteriorly. The sound was not pronounced but only imitated in a whisper.

The examination caused no irritation whatever. No tubercle was distinguished.

The general condition of the patient did not suggest complications.

Post-mortem examination.—Lungs.—Apices of both hard and irregular and contain cavities, as a rule of rather small size, but with one large one in the left about twice or three times the size of a walnut. Both lungs crowded with tubercles (miliary to naked eye) from base to apex, the left apex crammed and hard with them. These blend here and there but in a great degree tend to remain distinct. Both lungs show acute congestion. Pleuræ adherent, no tubercles seen in them.

Larynx and trachea. — Mucous membrane of trachea brightly congested. On careful scrutiny it is seen to be closely dotted with minute white points (like minute tubercles) enclosed in it. Mucous membrane similarly dotted, but pale and rather puffy, lines the larynx; the base of the epiglottis particularly puffy and swollen looking. The ventricular orifices are wide and irregular. True vocal cords: the left in fair preservation but hidden by irregular swollen mucous membrane, the right nearly destroyed and similarly hidden.

Ulcers. — Besides the general roughening, deep ulcers exist beneath the root of the epiglottis; around the ventricular orifices, over the vocal cords; and two symmetrical oval ones each a little larger than a pea at the front of the upper part of the trachea at either side of the middle line.

Remarks.—The history and pathological appearances lead me to think that this is a true case of pulmonary phthisis induced by a pre-existing lesion, inflammatory or tubercular, in the larynx. The abundance of miliary tubercles in the lungs and their persistence in that form give support to this theory of infection. Scrapings from the laryngeal ulcers and from a cavity in the lung treated by the Weigert-Ehrlich method showed tubercle-bacilli, and micrococci. *April 17th*, 1883.

---

4. *Ulceration of the larynx from a case of measles, and from a case of scarlet fever.*

By Norman Moore, M.D.

In the case of measles the child was a boy aged 5 years, who died of abscess of the brain six weeks after he was first taken ill. The larynx shows ulceration of the cords and of the base of the epiglottis. There is no false membrane.

In the case of scarlet fever the ulceration is more extensive. A considerable tract of epithelium is destroyed, but when fresh no false membrane could be detected. There was a deep ulceration of the fauces without false membrane. The patient was a boy aged

five years, and was the third case of well marked scarlet fever occurring in a house in the course of three months.

He died in St. Bartholomew's.

These cases are of interest in relation to the remark of Barthez and Rilliet, that laryngitis is more frequent in measles than in scarlet fever.

It is certainly rare to find ulceration of the larynx in *post mortems* of either one or other in London, and the frequently observed symptoms of laryngitis in measles are rarely severe enough to suggest ulceration. *May 15th*, 1883.

---

5. *Lung with impacted foreign body.*

By NORMAN MOORE, M.D.

THE right lung of a girl, aged 12, who died of typhoid fever. The lung was partly collapsed, and in its lowest lobe were several reddened patches. In one of these, near the pleural surface, was fixed a spicule of bone one third of an inch long. On following the main bronchus of the lowest lobe downwards its lining membrane was seen to be much reddened, and to have several large ecchymosed patches. Sticking through one of these into the lung, and approaching but not reaching the pleural surface, was the piece of bone. There was no gangrene or other sign of the injury having been recent. Four years earlier the child had suddenly been seized with pleurisy. The pleura was tapped in St. Bartholomew's Hospital, and pus let out; and as the wound continued to discharge a drainage-tube was put in. The child attended with this as an out-patient, and at length the wound was closed. The scar was distinct; the lung was firmly adherent to the chest-wall. The spicule of bone, having passed deep into the lung, probably set up a pneumonia, which was followed by the empyema. The empyema was recovered from, but the bone remained fixed in the lung—a very exceptional circumstance. *November 7th*, 1882.

6. *Hydatid cyst in lung; empyema.*

By J. Curnow, M.D.

The history of the patient from whom these specimens were obtained is shortly as follows:

John G—, aged 30, an able seaman, was admitted into the Seamen's Hospital under my care on the 16th October, 1882. He had suffered from a cough for four months, had been losing flesh, though not to a marked extent, and had frequently suffered from hæmoptysis, which was occasionally very severe.

On examining the chest there was some impairment of resonance and of movement in the upper part of the left chest in front, and very marked deficiency of breath sounds and of vocal fremitus and resonance over the same region, both in front and behind. There was no bulging nor fluctuation. The sputa were copious, frothy, and mixed with bright blood. There was no fever nor local distress, and no evidence of any affection of any other organ. His symptoms varied but little, except that his sputa contained more blood, and he had two attacks of profuse hæmoptysis. Early in January, 1883, he suddenly expectorated about two pints of a colourless, slightly opalescent fluid, and this was followed by a profuse hæmoptysis, which lasted several hours. Two weeks later he spat up, after considerable difficulty, a large piece of white membrane, which was recognised to be a ruptured hydatid cyst. He was much weaker, and had considerable dyspnœa and some hectic. It was now for the first time ascertained that he had been for some months a shepherd in Australia.

Physical examination now showed a hyper-resonant note on percussion under the left clavicle, with "whiffing" breathing and whispering pectoriloquy; lower down the breath and voice sounds were absent. On examining the back the dulness was marked from apex to base; at the upper part the breath and voice sounds were deficient, but were accompanied by some moist râles, whilst the fremitus was normal. In the lower part there was a complete absence of voice and breath sounds and of vocal fremitus.

On the 4th February he expectorated another large piece of membrane, and again had profuse hæmoptysis, and on the 6th he died from exhaustion.

On making a *post-mortem* examination it was found that the upper part of the left pleural sac was obliterated by dense thick adhesions, whilst the lower part contained from three to four pints of pus. In the upper lobe of the left lung was a large rounded cavity, lined by a thin smooth membrane, into which several small air-tubes, and one of large-size, freely opened. The cavity was very extensive, easily holding the closed fist, and was occupied by a loose hydatid cyst as large as a Tangerine orange, and from four to five ounces of blood-stained fluid.

No communication could be found between the cavity and the empyema, although this was most carefully looked for. The hydatid cyst contained fluid of the ordinary character, and many secondary cysts can be seen growing from the section of it which I now show. Some of these secondary cysts have been examined, and numerous echinococci hooklets found. The tissue of the left lung was compressed and airless. The other lung was quite healthy. No other hydatid cysts were found in the body.

This I believe is the only case recorded in the 'Transactions,' of hydatids in the lung only proving fatal in this country, and although one or two other cases are found in the medical journals, these only show how very seldom the affection is met with in Great Britain.

For the symptoms and treatment of the disease we must turn to the papers of Drs. MacGillivray and Bird in the various numbers of the 'Australian Medical Journal.'

Our difficulties in diagnosis in the early stages are greatly increased by the frequency and variety of the cases of phthisis, pleurisy, and pneumonia which are so common in this country. Even after the first piece of hydatid membrane was expectorated, and the nature of the affection shown, there was great doubt as to the exact locality of the cavity in this case, and this was further increased by the signs of fluid in the lower part of the pleural cavity, and the comparative infrequency of hydatids in the upper lobe of the lung. The man was now so ill that no operative procedure could be undertaken to determine the exact site of the cyst.

May 15th, 1883.

7. *The bacilli of tubercle found in contents of cavities and not in lung tissue.*

By SAMUEL WEST, M.D.

THE cases which I bring forward to-night are of some interest as bearing upon the question of the relation of the bacilli to tubercle. They show the grouping of the bacilli together in masses of a size which is not often met with—a size large enough in one instance to be seen with the naked eye. I have placed them under the microscope under a very low power.

The specimens were obtained in both cases from the contents of cavities, which were treated in the same way as sputum. One of the cases ran a very rapid course; in one it terminated in only ten weeks from the first commencement of symptoms. The case was in a healthy policeman, aged 33, who was taken ill in the station, having been up to that time on active duty. In general features the case resembled one of typhoid fever; there was high fever, great prostration, but in addition chest symptoms in abundant crepitation over both lungs, and some slight percussion dulness at both apices.

The other case was a labourer aged 30, who had also been in perfect health and active work until seven months before his death. The case presented somewhat more physical signs at the apices.

In both the temperature throughout the time they were under observation was high, 102—103°. Both were in much the same nervous condition, and both died rapidly of exhaustion.

The *post-mortem* appearances in both were closely similar, viz. numerous small patches of caseous consolidation scattered throughout the lungs, most numerous and confluent at the apices, where they had in several places softened to form small cavities. It was from the contents of these cavities that the preparations came.

In the first case numerous sections of the lungs were made, with the result of finding no bacilli present in the tissue, although the usual characteristic changes in phthisis were conspicuous. The bacilli were found in large numbers and in masses at the edges of the cavities, and there only.

Before referring more particularly to the importance of this fact,

I desire to state the conclusions at which I have arrived after some months' work upon the sputum in phthisical cases. I have examined a considerable number of cases; I cannot give the exact number, but it is not less than fifty, and in all of them I have found without exception the bacilli present; they were not always easy to find, for in some cases they existed in such small numbers that they were only demonstrated after careful and repeated examination. Bacilli, then, appear to be constant in the expectorations of phthisis.

I have not directed my observations to determine whether they were absent in other diseases, but in the few cases which I have examined other than phthisis, such as the expectoration of an empyema, which was discharging through the lung, chronic bronchitis, &c., I have failed to detect them.

As regards their number, speaking generally, it appears that they are more numerous in those cases which are rapidly progressing. I have observed them increase with the progress of the disease, and lessen with improvement in the general condition, so that they may be taken, with certain allowances, as evidence of the severity of the case.

They occur isolated, in groups or in masses, and if isolated, their number will be evidence, I think, of the amount of lung destruction. If it be a fact that the bacilli exist in largest numbers in the caseous lining of cavities, they will be found in largest numbers and in groups or masses where there is most rapid breaking down of the lungs and expectoration of the contents.

Hence they will be a measure rather of the progress of the disease than a test of the existence of phthisis. They show active destruction. If there is rapid excavation there will be many bacilli, if slow, fewer; or if the phthisis be of that peculiar kind in which death occurs before excavation has taken place, there will, of course, be no bacilli in the expectoration. We must, therefore, expect to have then early cases recorded soon in which bacilli have been absent throughout. Groups and masses are, I believe, only found where there is rapid excavation going on.

It has been stated that their size varies, and that the bacilli are smaller and less developed in the rapid cases. This my observation has not hitherto confirmed. In many of the acute cases the bacilli contain bright bodies which have been called spores. In some of these cases similar bright bodies appear to be free in the prepara-

tion. Whether they are really free spores or not I cannot say, but I do not recollect to have seen the fact previously observed.

I show the present preparation to-night because I think it gives a part explanation of these variations which have been observed in the number and massing of the bacilli in different cases, and as providing probably the real indication of the value of these variations.

This fact, if it be established, that the bacilli are most numerous in the caseous contents of cavities rather than in the true tissue of the lung, is not necessarily inconsistent with the results of inoculation experiments. The bacilli may be the true cause of the pathological changes we recognise in phthisis, and they may find their most suitable nidus for rapid development in the walls or contents of the cavities. They may develop in any part of the lung, and only most rapidly where excavation has commenced.

February 6th, 1883.

III. DISEASES, ETC., OF THE ORGANS OF CIRCULATION.

1. *Abnormal heart.*

By Norman Moore, M.D.

The heart and aorta from a man aged 18 years, who died in St. Bartholomew's Hospital with Bright's disease and pericardial effusion.

The right side of the heart is normal.

The aortic valves are free from disease and of the usual form, and did not permit regurgitation when fluid was poured into the aorta. When depressed in this way by fluid the aortic valves approached a fibrous ring with the tissue of which their bases are continuous.

Looked at from the ventricle this abnormal structure appears as a circular ridge attached to the uppermost part of the ventricular septum and to the mitral valve. The part attached to the ventricular septum may be divided into two parts. The posterior and lesser crosses the bare spot two thirds of the way up, and projects about half a line downwards into the ventricle. At the anterior boundary of the bare spot a very slight spur or puckering projects one line downwards on the surface of the septum ventriculorum. The anterior part of the ridge increases in downward projection as it extends forwards till it reaches the depth of one line. This it does at a point one fifth of an inch from the projection of the anterior wall of the ventricle from the septum ventriculorum. At this point there is another spur from the ring extending one third of an inch on to the septum.

The opposite part of the ring is continuous with the tissue of the mitral valve, and extends half a line downwards from it into the ventricle. All the cords of the mitral valve and the whole of its edge are quite natural, and show no thickening nor even opacity of any kind.

Above the aortic valves the aorta is quite healthy till the large orifice of the aneurysm, described later on, is reached.

The absence of any signs of endocarditis or degeneration on the mitral and aortic valves seems in favour of the hypothesis, that this ring is not due to any degeneration or inflammation occurring after birth.

The microscopic structure of the ring is opposed to its being of an inflammatory or degenerative origin of any period.

Its structure is entirely natural, and shows no traces of any inflammatory process. The free edge is covered by a layer of endothelial cells placed upon connective tissue. This latter is mainly arranged in laminæ parallel to the surface, but radiating also in different directions until it is continuous with the layers of unstriped muscle tissue beneath. The connective-tissue cells and nuclei of the muscle fibres are not increased in number, and the contour of the fibres is clear and sharp. The arrangement of the different constituents of the tissue is entirely different from the confused appearance of any newly-formed inflammatory tissue.

The ring seems, therefore, to be a variety in cardiac structure, and was most likely later in date than the closure of the ventricular septum.

In this case there was an aneurysm of the aorta of which the opening was just below the origin of the innominate artery.

The aneurysm had dissected between the layers of the pericardium, and the fibrin filling it had formed a firm mass at the base of the pericardium. The pericardium was distended to the size of a man's head with almost clear fluid, and the effusion seemed due to the pressure of this fibrin upon the pericardial veins. The aorta was elsewhere healthy. *October 17th*, 1882.

Report of the Committee appointed to examine Dr. Norman Moore's specimen of fibrous structures resembling valves in the left ventricle of the heart.—We have carefully and repeatedly examined this remarkable specimen, and agree with the preceding description by Dr. Moore.

We have not been able to find an example of a similar condition, and do not see any conclusive evidence to decide whether this specimen is due to a fœtal malformation or to inflammation in later life.

It is, however, we think, clear that the narrowing of the left

ventricle is of later date than the formation of the valves, and than the complete growth of the septum of the heart.

On the other hand, the smoothness and thinness of the mitral curtain which bears part of the constriction, prove that the fibrous ring must have been of much earlier origin than the aneurysm of the arch of the aorta. Moreover, the microscopic characters of the constriction are completely free from appearances of inflammation.

We are, therefore, inclined to refer the origin of the fibrous ring to the later period of intra-uterine life, and hence to regard the condition as due to a malformation rather than to a (post-uterine) inflammation.

With this would agree the absence of dilatation or hypertrophy of the left ventricle.

J. F. PAYNE.
P. H. PYE-SMITH.
S. COUPLAND.

---

2. *Variety in the structure of the heart.*

By NORMAN MOORE, M.D.

THE heart of a woman, aged 33, who died in St. Bartholomew's Hospital, under the care of Dr. Church, of tuberculosis. All the cavities were somewhat hypertrophied and dilated. The aortic valves were thickened and incompetent. The cords and edge of the mitral valves were thickened, and the flaps adherent to one another. The edge of the tricuspid valve and some of its cords were thickened. There was a considerable narrowing of the mitral orifice and a slight degree of tricuspid stenosis. The left auricle was very capacious and its endocardium thickened and puckered in several parts. The septum of the auricle was complete, and the fossa ovalis less distinct than usual. The part of the right auricle near the septum was divided into two by an oblique transverse partition, which stretched one inch into the auricle. It began just below the fossa ovalis and stretched from the septum of the auricles near the orifice of the inferior vena cava and ended in the posterior wall of the auricle. This partition was of the same

structure as the walls of the auricle. The anterior half was twice as thick as the posterior. The valve of the coronary sinus was of the usual form and quite free from this projection. I have described a similar case in a male in the 'St. Bartholomew's Hospital Reports,' vol. xvii (where for left, read right auricle, p. 226), and have met with one other example. The projection seems produced in connection with the Eustachian valve.

December 5th, 1882.

---

3. *Malformed heart, consisting of two cavities.*

By F. Charlewood Turner, M.D.

This specimen consists of an auricular cavity with two appendices, which receives the inferior vena cava, and a right and a left superior vena cava, the last vessel having received the blood from the pulmonary veins; and a ventricle communicating with the auricle by an orifice guarded by a valve of tricuspid form, from which arises the aorta, the arch of which is directed to the right, passing over the root of the right lung, and gives off the coronary arteries, and the three arterial trunks of the neck in the usual order,[1] and supplies the pulmonary circulation by an arterial branch to each lung through an open ductus arteriosus.

Behind the aorta, which arises from the front of the ventricle, is a fibrous cord, traceable from the roof of the ventricle to the left pulmonary arterial branch near its point of junction with the ductus arteriosus. This is evidently the contracted and closed pulmonary artery, a transposition of the main arterial trunks having occurred coincidently with their development from the right branchial arches.

On the left side of the ventricle, where its wall is very thick, an imperfect septum is formed by the incomplete coalescence of a number of thick muscular columns. A probe introduced through a chink between them at the upper part enters a space in which it can be passed downwards to the apex, and upwards to the floor of the auricle, through which its point can be felt. It can also be

[1] *i. e.* a left innominate and right carotid and subclavian arteries.

passed back into the cavity of the ventricle between the muscular columns near the apex. This would appear to be a very rudimentary and undeveloped left ventricle, without communication with the auricle, of which there appears to be no trace.

The ventricle is capacious and of a somewhat quadrangular form, as it has been described in similar cases, the base of the heart meeting the wall on the right side at a projecting angle, and the apex being rounded.

The auricle is also capacious, and remarkable in the great development of the muscular columns in its walls. The auricular appendices appear on each side of the aorta at its commencement. The right appendix is wide, the left small. Above them are seen the right and left superior venæ cavæ. The former, the larger of the two, descends in front of the arch of the aorta, and opens into the summit of the auricle, directly above the right appendix. The left descends behind the aorta and opens into the auricle at its base posteriorly, its orifice being contiguous to the left auricular appendices. The opening of the inferior vena cava is at some distance to the right of that of left superior cava; it is also at the back and close to the floor of the auricle. Just to the left of the orifice of the inferior cava is the valvular orifice of the coronary sinus, the mouth of which directly faces that of the vena cava. Below them both, and extending across the posterior wall of the auricle near its base to a muscular column, which rises from the floor of the auricle and projects between the mouth of left superior vena cava and the left auricular appendix, is a membranous fold, the Eustachian valve, which is about one third of an inch wide at its broadest part. The wall of the auricle above this fold is quite smooth; below it the muscular ridges are prominent. Behind and in front of the orifice of the right superior vena cava thick and prominent muscular columns ascend from the floor of the auricle, separating this venous trunk from the left and right auricular appendices respectively. Commencing from the posterior column a narrow crescentic membranous fold arches over the opening into the left auricular appendix. This appears to be the rudiment of the inter-auricular septum, the left auricle being represented by the small appendix only.

The pulmonary veins in four trunks, two from each lung, meet behind the pulmonary arteries at the bifurcation of the trachea. From their point of union a vessel passes upwards and forwards

over the left bronchus and joins the left superior vena cava about three quarters of an inch from its termination in the auricle. Lower down, the left superior vena cava receives a smaller branch, which passes backwards over the left bronchus to the œsophagus.

The specimen also shows the right vagus nerve descending in front of the arch of the aorta, and giving off its recurrent branch below it.

This specimen, for obtaining which I am indebted to Mr. J. Poland, lately Registrar at the North-Eastern Hospital for Children, is from the body of a male infant aged 15 months, who was brought to me as an out-patient there for bronchitis in February last. No cyanosis had been observed by the friends, and it was not very noticeable until the child's last attendance, which was a few days before its death, in May. The child was very small and wasted. It had been born at full time, and then was well nourished, and appeared healthy, but did not thrive. The mother had had no illness during pregnancy, and had never suffered from rheumatism, beyond slight rheumatic pains.

There had been two miscarriages and seven other children, of whom two were stated to have died from whooping-cough and three from convulsions.

In this case the malformation of the heart is referable to an arrest of development at a very early period of intra-uterine life.

The discharge of the blood from the pulmonary veins into the vena cava is interesting from the apparent rarity of its occurrence. In only two of the cases of malformation of the heart mentioned by Dr. Peacock in his work, was an irregularity of this nature recorded. The persistence of the left superior vena cava is less rare. The independent communication of this vessel and of the coronary sinus with the auricle is not in accordance with the arrangement usually observed in such cases. The situation of the orifice of the coronary sinus immediately contiguous to that of the inferior vena cava, above instead of below the Eustachian valve, is also abnormal.

The age of the child at its death, fifteen months, is notable. In the eleven cases of biloculate heart collected by Dr. Peacock the longest duration of life was ten and a half months. In only three of the cases was it over three weeks. *Dec. 5th*, 1882.

4. *A case of tricuspid stenosis.*

By Bedford Fenwick, M.D.

This specimen was obtained from the body of a married female aged 30, who died in the London Hospital on August 4th, 1882. She was admitted on the previous day, under the care of Dr. Samuel Fenwick, in a moribund condition. She was semi-comatose. The respiration was rapid (32), drawn, and laboured. There was considerable distension of the jugulars, and much œdema of the limbs, but no marked cyanosis. The pulse was quick (120), small, and compressible. The apex of the heart was found to beat half an inch external to the nipple line in the fifth interspace. On percussion the cardiac dulness extended to the right of the sternum. At the ensiform cartilage and above it, over a space about three inches square, a presystolic thrill could be felt, and over this area a distinct roughness, presystolic in time, followed by a soft systolic murmur, was audible. At the point of impulse of the left ventricle, and over a small area contiguous thereto, a distinct presystolic bruit and thrill were evident, followed by a short systolic murmur. The second sound over the pulmonary artery was accentuated. The liver dulness was increased, and on pressure over the organ below the ribs pain seemed to be caused and distinct pulsation could be felt.

The patient was reported to have suffered from rheumatic fever when young. Five brothers and four sisters had died from scarlet fever, and one sister from "heart disease and swelling of the abdomen." Her father had died of "bronchitis," her mother with "swelling of the legs." She had always had a very easy life and a comfortable home. Had married at 20, and had had three children and one miscarriage. Had been subject to winter coughs for the last fifteen years, but otherwise had enjoyed fairly good health till February 20th of this year. Then, after a slight cold, she developed pulmonary symptoms, then œdema of the legs, then symptoms of gastric catarrh, and so progressed from bad to worse till her admission and death. From the physical signs above detailed tricuspid and mitral stenosis were diagnosed. The *post-mortem* examination was made twenty-six hours after death. The body was well nourished and well developed. All the organs were greatly con-

gested, especially the liver and the spleen. The heart weighed 12 oz. The right auricle was much dilated and hypertrophied; the left auricle, also hypertrophied, was dilated to a less extent. The ventricles in comparison seemed small. The cardiac muscle was healthy and well contracted. On opening the cavities it was found that the tricuspid valves were much thickened and adherent to one another, forming a nearly circular opening, with hard fibrous edges measuring $2\frac{1}{8}$ inches in circumference. The chordæ tendineæ were much thickened and shortened. The endocardium was opaque and thickened. The mitral valves had undergone even more advanced changes. Greatly thickened and firmly adherent by their edges, only a narrow slit of communication remained patent between the left cavities, which with difficulty admitted the passage of a paper knife $\frac{1}{8}$ inch broad by $\frac{1}{8}$ inch thick. The pulmonary valves were quite healthy and competent. The aortic valves were thickened and roughened, but neither stenosed nor incompetent.

Remarks.—Some two years ago I brought the question of tricuspid stenosis before the Society, and by an analysis of 46 cases endeavoured to point out certain new and interesting facts. Since then I have obtained records of 24 more cases. I will not here weary the Society by recounting them, but I may say that in every particular they confirm the results before arrived at. For example:

Age.—The average age in women was 31, in men 35 years at death.

Sex.—Of the 24 cases, 21 were females and only 3 were males. In every case where noted at all the previous health had been good, and no other evidence of congenital disease was forthcoming. In every case the mitral orifice was also stenosed. In about half the number of cases the aortic valves were also diseased.

October 18*th*, 1882.

---

5. *Stenosis of the mitral orifice; recent vegetations on the mitral, aortic, and tricuspid valves; a sacculated fibrinous coagulum loose in the left auricle.*

By F. Charlewood Turner, M.D.

The preparation exhibited is that of a heart in which is seen a high degree of stenosis of the mitral orifice, with fibrous thickening and calcareous infiltration of the valvular curtains.

There are vegetations of recent formation along their lines of contact, and on the adjacent part of the wall of the left auricle, and upon the aortic valve, which is also thickened; there are also a few vegetations upon the tricuspid valve. There is great dilatation of both auricles, more especially of the left, the walls of which are much thickened. Above is suspended a sacculated fibrinous coagulum, of ovoid form, and about the size of a hen's egg, which was found lying loose in the left auricle, and resting upon the mitral orifice. Its surface is quite smooth over a great part; in part it is roughened. It was quite decolorised, and had evidently been formed some time before death. At one end is a large aperture, through which its contents had escaped. There is an adherent coagulum, filling up the auricular appendix, the exposed surface of which is rough and broken, and of a size corresponding with the aperture in the wall of the sac, which was probably detached from it, though the two did not seem to correspond when placed in apposition at the autopsy.

The appearances presented when the left auricle was laid open much resembled that figured in Plate I of vol. xiv of the Society's 'Transactions,' which represents a specimen exhibited by Dr. Ogle, in which a fibrinous concretion of spherical form was found loose in the left auricle, in contact with the stenosed mitral orifice.

The specimen now shown was obtained from the body of a woman, aged 34, who died a few hours after her admission into the London Hospital in February last. It was stated that she had had an attack of acute rheumatism two or three years previously, but no similar attack lately. She had been ill in bed for a month with much cough and expectoration, and great weakness and loss of flesh. Her illness commenced with a shivering fit and pain in the umbilical region.

When she was admitted there was evidence of much dilatation of the heart; a double bruit was heard at the apex of the heart, which was much displaced to the left, and a doubtful diastolic bruit down the left border of the sternum. Râles and rhonchi were heard all over the front of the chest. The liver was enlarged; there was also œdema of the lower parts, with wasting of the body generally.

At the autopsy the heart was found much enlarged, weighing 20 oz., and presenting the characters above described. There were several hæmorrhagic infarcts in the lungs. Two of those in the

right lung had softened down. Over one of these, at the lower part of the lung, the pleura had been perforated, and pleurisy had been set up with much fibrinous deposit over the base of the lung, which was in a state of pneumonic consolidation. There was an infarct also in the spleen, which was enlarged, congested, and firm. The liver was firm and congested, and granular on the surface. The kidneys were much enlarged, with depressions on their surfaces. The kidneys weighed 17 oz.; the liver 3 lbs. 5 oz.

June 2nd, 1883.

---

6. *Ulcerative endocarditis; infarcts in spleen and kidney; acute nephritis.*

By Frederick Taylor, M.D.

George T—, aged 26, a plumber, was admitted into Guy's Hospital, on October 16th, 1883, under Dr. Pavy's care.

At the age of 15 he had a severe attack of acute rheumatism, which laid him up in bed for three weeks. He remembers no pain at the heart. He went down to the seaside for two weeks, and came back feeling well, but was advised by a physician to go to the Middlesex Hospital, and there his heart was examined and a large blister was applied. He attended as an out-patient for a fortnight. After this attack he got rapidly fat, and continued rather stout till the present illness. He says he has not been a great drinker.

Four months ago he "took a violent cold," became very weak, and lost flesh rapidly; his breath became short and catching, and the heart began to beat violently. He went to Ramsgate for six weeks, and while there had an attack of rheumatic pains in the knees, ankles, and hips, but the pains were not severe. A short time before this he had noticed a little swelling of the feet and ankles at night.

He is very pale, with blue eyes, and fair hair; height 5 feet 5 inches; weight 9½ stone. Præcordial dulness normal; impulse in the fourth space one inch below the nipple, and a little to its inner side. There is also pulsation at the epigastrium. There is a soft localised to-and-fro murmur at the junction of the third right costal

cartilage with the sternum. At the apex the first sound is loud, harsh, prolonged, with no murmur; second sound clear and sharp. Pulse feeble, compressible, 104. Chest resonant, and lung sounds normal. Tongue slightly coated, red at the centre, white along the edges. Bowels regular; appetite bad; occasional sickness.

Urine, sp. gr. 1016, pale, clear, giving a precipitate with heat and nitric acid; the quantity passed is considerable. He perspires freely at night, and expectorates a good deal in the morning.

Ordered digitalis and iron. Fish diet.

October 22nd.—Slight pain and stiffness about the joints. A rigor this morning.

25th.—Tenderness and pain over the spleen. The pulse is fully dicrotic; the temperature rises to 103° or 104° in the evening, falls to 100° in the morning.

26th.—Ordered quinine in 3-grain doses every four hours.

November 3rd.—Expectorated some blood-tinged mucus, but his lungs appear normal. He is much weaker, with increasing anæmia; pulse somewhat splashing in character, though showing a dicrotic wave. He speaks with difficulty, stopping for breath often. The urine is albuminous, of sp. gr. 1012, and 74 ounces have been passed in twenty-four hours.

He continued in much the same condition till his death on November 19th, being febrile, anæmic, drowsy, short of breath, expectorating blood-tinged mucus, and passing large quantities of albuminous urine of sp. gr. 1010—1015. The urine passed from November 5th to November 14th inclusive showed a mean daily amount of 3½ pints. The temperature oscillated between 100° and 104° from October 23rd to October 28th, and after that was more irregular and mostly between 99° and 102°, the evening record being always the higher.

On November 14th there was some œdema over the sternum and at the ankles.

On the 19th he was taken rather suddenly with severe dyspnœa and died in a few hours.

The *post-mortem* examination was made on the following day, twenty-nine hours after death. The body was fairly nourished, but very anæmic, and there was slight dropsy of the legs.

The head was not examined.

There was a good deal of fluid on both sides of the chest, and the upper lobes of both lungs were solid from œdema.

Heart.—The pericardium was adherent over the front of the heart. The organ itself weighed 20½ oz., and the front was formed for the most part by the right ventricle, though the left ventricle was also much hypertrophied. The muscular tissue was very pale and fatty. The aortic valves were excessively diseased; the posterior and left anterior valves being merged into one ulcerating, fungating mass which blocked the opening very considerably. The other valve was thickened and rigid from old disease. The ulceration extended through the ventricular flap of the mitral, and an ulcer was obvious on the auricular face of this cusp. The ventricular surface of the mitral flap was covered with vegetations, and the chordæ tendineæ were much thickened from old disease. The mitral orifice was not contracted.

The spleen weighed 18½ oz., was very much enlarged, and presented much recent peritonitis on its capsule. It contained several infarcts of greyish-yellow colour. One of these was of triangular shape, about 3 inches long from the base at the surface of the spleen to its apex in the centre of the organ.

The capsules of the kidneys were adherent; the organs were of large size, mottled yellow and white like those of chronic tubal nephritis. One of them contained a small yellow infarct. The liver was healthy.

Remarks.—The heart, spleen, and kidneys from the above case were exhibited fresh, as unusually good illustrations of a typical case of ulcerative endocarditis. The ulcerative process was clearly grafted upon old valvular disease, as shown by the size of the heart and the condition of its cavities, as well as by the previous history of the case. Unfortunately the specimens were mislaid after the meeting at which they were exhibited, and I am unable to give any account of the minute anatomy of the cardiac vegetations or of the kidneys. *November* 21*st*, 1882.

7. *Heart disease and subcutaneous fibrous nodules following rheumatism.*

By JOHN CAVAFY, M.D.

THE specimens shown are the heart, plaster casts of the right hand and elbow (for which I am indebted to Dr. Drewitt), and microscopic sections of two nodules, from the following case:

Albert C—, aged nearly 18, was admitted into St. George's Hospital under my care on January 19th, 1883. There was no inheritance of rheumatism, but in 1876 the patient suffered from this disease severely, and had ever since been troubled with short breath and frequent palpitation, but there had been no recurrence of articular pain and swelling. About a year before admission he first noticed small nodules on the backs of his hands; these had since grown slowly, and others had made their appearance over the elbows and near the knees. He stated that they had never disappeared to be followed by a fresh crop, but had remained stationary, so far as he could judge, since their first development. Beyond slight aching at night they caused him no inconvenience. For three months before his admission there had been increasing distress from cough, dyspnœa, and palpitation, and a month before he came in the legs swelled for the first time; for the last two days the sputa had been streaked with blood.

On admission he was very ill with extreme dyspnœa, congested lips, and dusky venous tint of face; the skin was cold and damp; he had a wearied expression, and took little notice of anything. The heart was acting with tumultuous violence, and on inspection there was visible impulse from the second right to the sixth left intercostal space, about one inch external to the nipple line; over this wide area the wave of cardiac contraction could be seen passing downwards, and it was noticed that the intercostal spaces were drawn somewhat inwards in systole, except the fifth and sixth, which became slightly prominent. A loud and rough systolic murmur was audible over the whole cardiac area and in the neck, the point of greatest intensity being just external to the apex beat. The pulse was frequent, but fairly strong and regular. Over both lungs the breathing was harsh throughout, with occasional rhonchus, and there was some dulness on percussion over the right base; the

sputa were frothy and blood-streaked; the urine was of sp. gr. 1020, brownish orange, loaded with urates, and containing a considerable quantity of albumen.

Over the backs of both hands the dorso-lateral aspect of the phalangeal joints of the fingers and over both elbows were numerous nodules, symmetrically placed, and one near the lower margin of each patella; the total number of nodules was sixteen; the cranial bones, clavicles, scapulæ, spine, ankles, and backs of feet and toes were carefully examined, and found to be free. The nodules were placed with almost exact symmetry, and were all subcutaneous and non-adherent to the skin, which was freely movable over them, and of normal colour and consistence; they varied in size from a hempseed to a split pea, or a little larger, and were rounded or oval in shape, some of those over the elbows appearing bluntly pointed, especially when the forearms were flexed. The nodules differed somewhat in consistence, the smaller ones being decidedly tougher than the larger, which could be easily compressed and flattened to some extent between the fingers, returning at once to their previous size on ceasing the pressure; the majority were slightly movable from side to side, and none of them were tender on being handled.

The dyspnœa and distress increased after admission, and on the following day there was considerable hæmoptysis, and a small, painful, raised, hæmorrhagic patch subsequently appeared over the left olecranon; the temperature was slightly raised, ranging from 99° to 101·2°, and sinking rapidly before his death, which took place on January 24th.

Post-mortem examination twenty-five hours after death.—Body well nourished; marked rigor mortis; general anasarca; there were a few old adhesions in each pleura. The left lung was small, being much compressed and displaced by the large heart; its tissue was congested and œdematous, and contained three small patches of old pulmonary apoplexy; the right lung was much larger, very œdematous, and congested, and there was a large block of recent hæmorrhage near its posterior border, occupying a portion of the upper and a greater part of the lower lobes; the bronchial tubes in both lungs contained much mucus, and their mucous membrane was very congested.

The heart was much enlarged, weighing 19 oz.; there was much external fat, and the visceral and parietal layers of the pericardium

were closely adherent throughout; all the cavities were dilated, especially the left ventricle, but hypertrophy was not marked; the aortic valves and neighbouring endocardium were much thickened, and a row of minute rough vegetations occupied the free margin of each valve; the mitral orifice was contracted, admitting one finger only, and the curtains of the valve were much thickened; a ring of minute rough vegetations surrounded the auricular surface of the orifice; both these and the similar ones on the aortic valves could be almost completely picked off without much difficulty.

The liver weighed 3 lbs. 7 oz., and was much congested. Spleen hard and dark, weighing 6 oz.

The kidneys weighed (together) 19 oz.; the right was hard and congested, but otherwise macroscopically normal; the left was converted into a thick-walled sacculated cyst, mere traces of normal structure being left; there was no calculus, and the corresponding ureter was not blocked or otherwise obstructed, but its calibre was very much narrowed near its origin.

Microscopic examination.—Sections were prepared of two nodules removed from the elbow, a small one, a little bigger than a hempseed, and a larger one, about the size of a small bean. Both were oval in shape, and closely connected with the triceps tendon; they were not encapsuled, nor sharply marked off from the subcutaneous areolar tissue, as a little fatty tissue was found included in the substance of each nodule; they both consist of fibrous tissue, but this is somewhat different in the two; in the smaller nodule it presents the ordinary characters of young fibrous tissue, being rich in cells of the usual type, but there is much intercellular fibrous substance, a parallel arrangement obtaining throughout, and the whole structure is comparatively dense and compact. In the larger nodule, although a similar condition is here and there met with, the greater part is of a much looser texture; the irregularly disposed, but, on the whole, parallel bands of fibrous tissue, being in many places widely separated from each other, remaining connected only by delicate bridging fibres at irregular intervals; this condition is, no doubt, due to œdema of the nodule; the larger nodule is also much more richly infiltrated with lymphoid or inflammatory cells, and in many places these appear to be arranged along the walls of capillaries or venules; in others, again, they occupy interfascicular lymphatic channels, or are more loosely packed in large lacunar spaces, which appear to be due to œdematous distension.

In many parts of the larger nodule there are tracts of a homogeneous material, staining strongly with colouring matters, and with a peculiar arrangement; it forms eroded, sheet-like expansions, varying in breadth, and terminating by a sharply-defined, larger or smaller crescentic margin, and in this arrangement is met with chiefly in the neghbourhood of blood-vessels; when it occurs in œdematous spaces or among inflammatory cells it often forms a coarse reticulum, of which the meshes are rectangular, and very unlike any physiological tissue; the substance does not appear to be continuous with the proper tissue of the nodule at any point, but is rather superimposed or interspersed, and bears all the characters of an infiltration. As it is found chiefly in the neighbourhood of blood-vessels, and in those parts in which inflammatory processes are most active, and in which the œdema is most marked, it is most probably a coagulation product composed of fibrin or some derivative of fibrin; this view is further supported by the fact that a similar material, staining in a precisely similar manner, occurs in the interior of many blood-vessels. Mere traces of the same substance are to be found here and there in the smaller nodule, in which an active inflammatory condition is much less marked. There is evidence of regressive changes in many places of the larger nodule, in which the tissue is blurred and indistinct, probably owing to a mucoid degeneration. Both nodules are very vascular, and the arteries in both are decidedly abnormal, there being again differences in the two nodules. In the smaller one there is great thickening of the intima, in many places so extreme as to cause practically complete occlusion of the vessel; this thickening is due to an overgrowth of the subendothelial fibrous tissue, the endothelium itself appearing normal; the middle coat is perhaps a little thickened, and the adventitia is fused with and indistinguishable from the fibrous substance of the nodule.

In the larger nodule the majority of the arteries show proliferation of the endothelium, which is much swollen, and frequently gives rise to bud-like projections into the lumen of the vessel. Both the middle coat and adventitia are œdematous, and infiltrated with lymphoid cells and the fibrinous substance above described. There seems, therefore, to be an endarteritis, probably of rheumatic origin, chronic in the small dense nodule, and acute in the larger one, in which all inflammatory processes are more active.

The case is a good example of the curious affection to which Drs.

Barlow and Warner drew attention at the International Medical Congress in 1881, and is of interest from the sex of the patient (most cases occur in girls), from his comparatively advanced age, and from the apparent permanence of the nodules after their first development. *March 20th*, 1883.

---

8. *Morbus cordis; adherent pericardium; rheumatic nodules.*

By ANGEL MONEY, M.D.

HISTORY.—Louisa B—, aged 10½ years, was admitted into the Hospital for Sick Children, on September 28th, 1882, under the care of Dr. Dickinson, to whom I am indebted for permission to make use of the case. Three years ago she had had scarlet fever, which was followed by rheumatism; since then there has been complaint of pain at the chest and shortness of breath; the feet have swollen when the patient has walked; she has had rheumatism off and on ever since the first attack. Six weeks ago a fresh attack set in. Neither the memory of the patient nor that of her mother was available for a more accurate account than the one given. On close questioning it appeared that the patient had suffered from twitchings for six months after the first attack of rheumatism. She had had measles and hooping-cough when very young.

There were eight children, but no miscarriages; the patient was the sixth child; there were no deaths. The father had suffered from rheumatic fever four times. The fifth child had had chorea; the second child had chronic cervical abscesses after scarlet fever, and again six months ago. There was no history of rickets or congenital syphilis.

CASE.—Present state, September 28th, 1882:

Heart.—Apex beat not localisable; the impulse is diffuse; there is a thrill of doubtful time; there is a murmur heard in front and back, probably systolic; the præcordia is full; there is no dulness in second left space; the right limit of cardiac dulness extends as far as the nipple line. The chest is somewhat pigeon-breasted.

Lungs.—Coarse breathing is heard everywhere; no râles; the percussion yields no definite signs of disease. The lower edge of the liver is felt on a level with the navel.

The face is pale; the jugulars are full and pulsate, but do not fill from below. The pulse is 132, small, and regular; the urine is free from albumen; there is no fever.

There are rheumatic nodules on elbows and patella. Two small ones on the outer border of right patella. Those on the elbow are arranged thus:

Five nodules arranged in a circular fashion corresponding to the lower part of the rounded outline of the external condyle of the humerus; the largest of these is two millimètres in diameter, the smallest one millimètre. Two more are situated above these, and are each about one millimètre in diameter. Another about three millimètres in its longest diameter and oval in shape, is situate at the outer aspect and posterior part of the olecranon.

There are two nodules on the external condyle of left humerus; the posterior is shaped like a grain of wheat and nearly as large; the anterior is rounded and about a millimètre and a half in diameter.

October 2nd.—Headache and pains in legs and feet complained of. Urine is acid, contains an excess of phosphates, but no albumen. The temperature is 102·4°.

3rd.—No fever; she still complains of pains in the feet, but otherwise is better. The pulse is 132, and regular.

8th.—Both feet are still painful and a little swollen; there is no fever. The patient has vomited occasionally. The urine was acid, and contained a trace of albumen on the 6th.

13th.—Œdema of both feet is present. There are some coarse râles at the bases of both lungs behind; the note on percussion is not definitely altered. There is no fever. The rheumatic nodules are still marked; a fresh one has appeared, the size of a split pea, on the right patella.

19th.—There is still a little œdema of the feet; there is no pain, or only occasionally. There are some adventitious sounds at the left base behind.

21st.—Drawing of nodules made by Dr. Westmacott.

25th.—Complaint of pains in the shoulders, but no swelling; the feet are still œdematous.

26th.—Complaint of pains at knees and across chest; no swelling.

28th.—The pains have continued at knees, feet, and shoulders; the patient is very thirsty and miserable; the salicylate is being pushed. No fever. The condition of the heart is as on entry.

31st.—The patient became very ill rather suddenly last night; the

sister said she became very faint and the lips turned blue. To-day there is no fever; the cardiac dulness still extends two fingers' breadth to right of parasternal line. There is certainly not a large amount of ascites. There are coarse crepitations at the bases of both the lungs, but no bronchial breathing. There is œdema (with pitting) of the legs, feet, and back of both thighs, as well as in sacral region. The lips are bluish, the face pale and puffy-looking, but does not pit on pressure. Both the external jugulars are full and pulsating, but not filling from below. There is extreme orthopnœa. The liver reaches as low as the navel. The pulse is 132, and fairly regular; the breathing 48 per minute; there has been vomiting.

November 1st.—The urine contains a trace of albumen. The temperature is 99°. The œdema has increased; the patient is put on the "dropsy pill" three times a day.

℞ Hydrarg. subchl., gr. j;
Pulv. Scillæ, gr. ss;
Pulv. Digitalis, gr. ¼.
To each pill.

6th.—The patient has rallied somewhat; there is less œdema, but still pitting on both legs and sacral region. Crepitations are heard at both bases, but especially on the left side. The temperature was 101° on the nights of the 2nd and 3rd; there is no fever now. Vomiting occurred five times yesterday; the bowels acted four times. The quantity of water excreted is about 500 cc. per diem. Yesterday the quantity was over 800 cc; the day before yesterday caffeine had been prescribed.

11th.—The œdema is much less; there is pitting only in the sacral region; there is no vomiting now.

15th.—There is no œdema anywhere; the patient is very thin; the legs look like mere sticks. The pulse is 124, and regular; there is no return of the pain.

December 1st.—The patient has been up on the couch for a week past. There is no œdema; the general health is much improved.

6th.—At 11 p.m. last night she became suddenly bad, complained of agonising pain across the chest; the lips were blue, the breathing not apparently so much disturbed. To-day, 3 p.m., the patient has blue lips and dusky face; there is scarcely any radial pulse; the apex beat of the heart is in the fifth space, rather outside the nipple line; the impulse is fairly good; there is no thrill; the murmur is unaltered; there is no friction. She still complains of

pain only across the chest. There is no œdema of the feet. By accident at 3.30 p.m. the nurse went to her and found her very pale, with dilated pupils. I was called, and found the patient gasping with risus sardonicus; this about six times; then no breathing; there was no pulse, the heart was heard to beat once or twice after the breathing had ceased. Death.

Post-mortem examination twenty hours after death.—Weight of body 39 lbs.

The somewhat pigeon-shaped breast was probably due to the diseased heart.

There was no evidence of rickets or syphilis anywhere.

The brain, meninges, vessels, and sinuses of head were natural. There was no optic neuritis and no tubercles in the choroids; the middle ears were healthy.

The heart was very large, and weighed, with clots and adherent pericardium, 28 oz.; the cavities were dilated, and the walls hypertrophied; the right side was very full, and contained much *yellow* soft clot, probably formed *post mortem*. The heart substance was somewhat tough; its colour was reddish brown.

The pericardium was adherent all over, though not very firmly so; both opposed surfaces when separated exhibited a dark purplish colour. Apparently in the heart wall were to be felt a number of nodules, none as large as a split pea, of very hard consistence, and with a white fibrous appearance on section; they were only detected in the front wall of the heart, over the right ventricle.

Some of the chordæ tendineæ of the mitral valve were thickened and shortened, and some of the musculi papillares were hypertrophied; the valve when laid open measured 3½ inches; regurgitation took place when water was injected into left ventricle from the aortic orifice.

The aortic valves were competent; their attached margins were a little thickened; the pulmonary valves were in the same state.

The tricuspid valve when laid open measured 4 inches; there was a little thickening of the free edges at parts only. No calcification was discovered anywhere. The aorta was fairly healthy, and free from obvious atheroma.

Unquestionably the chief change to be noted was in the pericardium, and makes one suggest the question whether the whole of the other changes found might not be secondary in time and nature to the pericardial disease.

Both pleuræ were adherent to the outer surface of the adherent pericardium. The pleuræ were universally adherent, but not very firmly, except at the posterior base. The right and left lower lobes were in a state of partial collapse and congestion, the consistence being a trifle increased. Right lung weighed 11¼, left 9¼ oz. Nothing else of note.

Bronchi contained some reddish mucus.

Bronchial glands were a little congested, not big, none cheesy.

Stomach showed much vascular injection, a purple colour being present from the cardiac end up to the pylorus; some black stuff in stomach, but nothing further observed.

The fauces and many parts of the intestines were of the same purple colour.

There were no signs of embolism in the lungs, spleen, kidneys, or elsewhere.

There was a trifling amount of ascites, about 3 oz. of yellow fluid, and a piece of gelatinous fibrin.

The liver was large and displaced downwards, partly by gravity and partly by enlarged heart; the weight was 57¼ oz., the measurement 9½″ from side to side, 7 from before back, 3½ greatest depth.

The surface on section was of fairly marked nutmeg appearance; there was much blood in the vessels; the consistence was certainly not increased.

The mesenteric glands were congested, none cheesy.

The spleen weighed 3¼ oz., consistence not increased; nothing more special was noted.

Kidneys each weighed 3¼ oz.; the cortex had a confused look; the consistence was diminished, there was congestion.

All other organs, except the spinal cord, were examined, but no pathological changes were detected.

Microscopical characters of a rheumatic nodule removed from the back of the right elbow, and of a nodule in the pericardium, together with the myocardium.—A section of the first nodule stained with carmine or logwood, and examined with the naked eye, showed a curious corrugated marking, roughly resembling the configuration of a "corpus dentatum."

Under a high power there are two kinds of tissue discernible: the one is composed of large cells with large nuclei, the other is a highly refracting network of fibrous tissue not unlike the cellulose of a

vegetable cell-wall in appearance, of that variety which some pathologists have called membranous (of this the corrugated marking was chiefly composed); in the holes of this fenestrated membrane, or in the meshes of this network, soft cells may be detected quite like the large cells previously mentioned; in addition to the above a few small spindle-shaped figures may be discovered. My interpretation of these microscopical characters is that we have to do with a fibro-cartilaginous tissue; in many places there is nothing more than the closely-aggregated large cells, with little or no matrix. This may be likened to the cartilage of the notochord, or of that of the head of the cephalopod, and has been called "parenchymatous cartilage" by Rollett.

Sections of the nodule in the pericardium show many small cells of oval, round, or spindle shape, with a delicate groundwork of connective tissue faintly fibrillated. In the rest of the pericardium there are abundant minute vessels full of blood, with scattered connective-tissue corpuscles, and many more or less mature bundles of connective tissue. The connective tissue of the myocardium is also increased in a diffuse fashion. The nodules in the pericardium are quite outside the heart muscle, which, however, may be seen to recede or be atrophied in a bay-like fashion at the site of the nodule. *March 20th*, 1883.

---

9. *The analogy between rheumatic nodules of children and heart disease.* (*Living specimen.*)

By F. Dawtrey Drewitt, M.D.

The boy is 8 years of age. He had scarlatinal rheumatism three months ago. Six weeks ago he was brought to the Victoria Hospital for Children for "lumps on his knees and elbows," which were said to be getting larger.

On his patellæ, elbows, and occiput there were subcutaneous nodules—some as large as a coffee nib. The plaster casts of his knees and elbows show their size a month ago.

There was also a loud harsh systolic apex murmur, but no dyspnœa on exertion, nor cardiac hypertrophy.

The treatment consisted simply of a tonic containing the ammonio-citrate of iron.

The nodules have now completely disappeared (the mother, who is present this evening, says that she has not seen one for a fortnight), and, what is of more importance, the murmur is only just audible.

The attention of the medical profession in England was first called to these bodies in a paper read before the International Medical Congress by Drs. Barlow and Warner on 'Subcutaneous nodules occurring in children, the subjects of chorea and rheumatism.' Dr. Barlow considered these nodules indicative of rheumatism, and made one statement which seems to me to be a very important one, viz. that these bodies are "in their nature probably homologous with the exudation which forms the basis of a vegetation on a cardiac valve." But they are, I consider, not only homologous in their nature, but the fact of their being deposited in two such different parts, as the surface of the body and the endocardium, I believe to be due to the same cause. First, in all the recorded cases of subcutaneous nodules in children, and in all those I have myself seen, there has been heart disease. Secondly, these nodules occur over all those bony prominences of the body which are the most exposed to friction, and on their most elevated points. It is quite extraordinary, if one thinks of it, how universally this is the case. They are found on the knees, elbows, knuckles, backs of the hands, spines of the vertebræ, crest of the ileum, all of them points which are the most rubbed against by clothes and other external things. Of the internal parts of the body, the valves of the heart are perhaps more exposed to continuous friction than any other structure; friction from the blood current, and, when inflamed, friction from each other; and here it is we find the cardiac rheumatic nodules, the "vegetations," and on the most prominent parts of the valves. But it might with justice be said that the pericardium, especially when inflamed by rheumatism, is almost as much exposed to friction as the valves; and here too nodules have been found, connecting links if any were wanted, between subcutaneous nodules and vegetations of the endocardium. Thirdly, nodules and vegetations rise and fall together. In the case of the boy I have brought to the Society, a loud harsh mitral murmur has almost disappeared as the crop of nodules subsided. From which I think we may conclude that these apparently unim-

portant bodies may have a very important bearing upon the prognosis, and may possibly guide us in the treatment of disease of the mitral valve.

Four years ago, when my attention was first called to them, they seemed of but little importance; they were so small and painless that the patient was generally not aware of their existence; but it now seems impossible to doubt that they might have an important bearing on the diagnosis, prognosis, and treatment of heart disease.

March 20th, 1883.

---

10. *Endocarditis with miliary abscesses of the heart in a case of hip-joint disease.*

By Norman Moore, M.D.

The hip-joint showed denudation on both surfaces and the ligamentum teres was detached from the femur. The joint was full of pus, and so was the right sterno-clavicular joint. The heart showed growths on the aortic valves, destruction of their substance, and one large endocardial ulcer on the upper part of the ventricular wall. Both ventricles showed white specks, looking like tubercles, and there were similar specks on the pericardium and in the liver and mucous membrane of the small intestine; on the surface of the brain were similar specks surrounded by injected patches. The spleen, kidney, and right lung contained softened infarcts, and pleurisy, pericarditis, and peritonitis were present. The little specks were not tubercles; they had no reticulum and no giant cells, and yielded (on Ehrlich's method) no bacilli; they consisted of contiguous leucocytes, and were, in fact, very small and early abscesses.

The patient was a boy, aged 16. He had a fall on November 11th, which was followed by fever. Two days before his death he became hemiplegic, with symptoms pointing towards tubercular meningitis. Probably the hip-joint disease was of long standing, and the fall set up acute inflammation; this was followed by ulcerative endocarditis and its consequences. *Jan. 2nd*, 1883.

---

11. *Syphilitic gumma of the heart.*

By GEORGE C. HENDERSON, M.D.

J. C—, aged 30, a labourer, was brought to St. Mary's Hospital on the morning of October 31st, 1882, in a moribund state, and expired before he could be removed into the ward.

His companions stated that he had been formerly a sailor, that he was married, but had no children, and that he seemed in good health till about a fortnight previously, when he began to complain of pain, followed by a sensation of faintness, in the left mammary region.

When on his way to work he suddenly staggered and fell into the road, groaned, and put his hand to his heart, but did not speak or show any sign of consciousness from that moment till his death.

At the *post-mortem* examination, made twenty hours after death, on November 1st, the skin and mucous membrane were noticed to be blanched.

The *brain*, *lungs*, and *kidneys* were normal.

The *spleen*, weighing 12 oz., was enlarged, congested, firm, and adhered in many places to the parietes.

The *liver*, weighing 62 oz., showed a depressed fibroid scar on the anterior margin of the right lobe, close to the falciform ligament; this cicatrix sends a small process into the hepatic tissue beneath. No gummata were seen. Substance of normal consistency.

Heart weighs 13½ oz. The visceral layer of the pericardium, especially the portion covering the left ventricle, shows congestion of the medium and smaller-sized vessels, and is studded with several pale yellowish-white elevations, projecting slightly above the surface. One or two similar spots are seen at the base of the right ventricle, near the anterior border of the septum. Valves normal. On opening the left ventricle from below, the endocardium of anterior wall is studded with straw-coloured nodules, similar to those on the exterior. On cutting along the septum a mass of fibroid tissue, nearly a quarter of an inch thick, is seen extending from the endocardium into the muscular substance, with which it gradually blends. On making a section through the affected portion of the anterior wall of the left ventricle the change is found to extend through from endo-

cardium to epicardium; it is here a pinkish grey, moderately firm mass, showing here and there paler, more firm nodules, round which, especially on the septum, numerous vessels ramify. The mass measures 1½″ in length, 2″ in width, and ⅛″ at the spot of greatest thickness; there is no dilatation of the heart's cavity opposite it, nor does it show any deposit of lymph or fibrin.

Microscopically examined, the superficial part of the nodule is seen to consist of richly-nucleated fibrous tissue, the bundles of which run parallel to the surface, and contain large thin-walled vessels filled with red corpuscles. In the deeper portions the muscular bundles and fibrils are separated and surrounded by connective tissue, in places fibrillar and somewhat dense, in others looser and more like areolar tissue; while near the endocardium several collections of small round cells, with hardly any stroma, can be seen. The connective tissue everywhere contains numerous small cells, some of which are round or oval, while others aré oat-shaped or fusiform. The branching and interlacement of the isolated muscular fibrils is well seen in places, and the fibres, though in many cases very thin, still preserve their striation, and show no signs of fatty degeneration.

There are no caseous spots in the sections examined.

The lumen of the smaller arterioles was much narrowed by thickening of the intima, which showed several nuclei arranged concentrically in a fibrillated matrix.

Remarks.—The appearances met with in this specimen seem to form the connecting link between cases similar to that of Dr. Burney Yeo, recorded in vol. xxvi of this Society's 'Transactions,' and those of fibroid degeneration of the heart, of which eleven cases were described by Dr. Hilton Fagge in vol. xxv, and nineteen others referred to. In Dr. Yeo's case the growth affected mainly the right papillary muscle, but was not sharply limited, shading off gradually into the muscular wall of the left ventricle; and though its structure was less fibrous than in the specimen now shown, the infiltrating nature of the growth and the mode of distribution of the small round cells composing it between the muscular fibres is almost the same in the sections shown under the microscope as in the drawings of Dr. Yeo's case. One of the cases alluded to by Dr. Fagge, and which seems to have been considered due to syphilis, appears to have presented similar appearances, though the development of fibrous tissue in it was more advanced.

In the absence of definite history of syphilis I have been led to assign that disease as the cause, from the structure of the growth, mixed small cell (granulation) tissue, and richly nucleated fibrous tissue, and the condition of endarteritis deformans seen in some of the vessels; as well as from the collateral evidence of indurated nodular glands in both groins and posterior triangles, the presence of a pigmented scar in the right groin, and of a depressed cicatricial patch sending prolongations into the interior upon the surface of the liver.

I could get no satisfactory evidence whether the attacks of precordial pain, of which the patient had complained, were of anginal nature or not, and can only offer a hypothesis as to how the sudden termination in this instance, as in most of the recorded cases of fibroid disease of the heart, was produced.

As the experiments of von Bezold and Samuelson have shown, obstruction of a medium-sized branch of one of the coronary arteries has at first no visible effect on the heart's action. After the lapse of some ninety seconds the beats become somewhat irregular and slower than normal, but there is no change in the blood pressure till, quite suddenly, both ventricles stop in diastole. In man a similar stoppage of the heart has been noticed in cases where blocking of the coronary arteries was found *post mortem*, and though I could find no clot in the vessels when I examined them it is possible that the stenosis of minute branches from endarteritis, as seen in the sections, may have impaired the nutrition of the cardiac substance and ganglia sufficiently to cause a sudden failure of their action. *November* 21*st*, 1882.

---

12. *Observations on morbid conditions of the cerebral arteries.*

By Samuel Wilks, M.D., for C. Handfield Jones, M.B.

(With Plate IV.)

The following is a summary of the results of numerous observations made on about twenty-five individuals taken indifferently during the last eight or nine months, with the exception of

one, which was noted more than six years ago. They are in some measure, the writer believes, novel, or at least not devoid of interest.

Atheroma affecting the cerebral arterioles affects two principal forms, viz. the *localised*, or massive, and the *diffuse*. These, though often occurring separately, are linked together by numerous intermediate conditions. The first is characterised by the presence of large or medium-sized oil drops or fat masses often made up of small drops grouped together, which, beyond any doubt, are contained in the interior of the vascular channel, and are commonly seen resting on or adhering to the intima. Their form is mostly globular, but not unfrequently is much elongated, when they lie like a long streak stretching along the side of the vessel. They may accumulate so greatly as to form a large mass, distending the vessel to perhaps twice its normal diameter, or forming a bulging at one side. These dilatations very much resemble aneurysms, but differ essentially in having no pervious channel, and consequently in not containing blood or clot. They are filled with fatty matter and glistening corpuscles, and often contain micrococci in swarms. Something like tablets of cholesterine are occasionally seen in the atheromatous accumulations. The wall of the vessel where dilated is usually thinned and altered in texture, and is often permeated by escaping oil drops. The pressure of the covering slip of glass is very apt to flatten the globular enlargement, and press its contents onwards either into the contiguous part of the channel, or out of it altogether when its cut end is near. This of course alters the original appearance materially. More frequently atheroma forms flattish patches, of greater or less extent, sometimes quite limited. These can be well studied in specimens mounted in glycerine, either when the arterial wall is so thin as to be translucent, or when a larger vessel is cut open and spread out with its inner surface uppermost. In the latter the fatty matters can be distinctly seen lying most superficially, and by altering the focus, one can bring into view successively the intima and the subjacent muscular layer. When the atheromatous patch is examined in an unopened vessel it may be seen to be limited by the inner margin of the wall, on which it does not encroach. In small vessels $\frac{1}{300}$ to $\frac{1}{500}$ inch diam. the oil drops can be seen distinctly lying on the intima, which appears quite healthy. Oil drops, however, are often seen in the substance of the wall, as in the muscular layer

DESCRIPTION OF PLATE IV.

Illustrating Dr. Handfield Jones's paper on Atheroma of the Cerebral Vessels as a Cause of Obstruction. (Page 56.)

FIG. 1.—Cerebral artery $\frac{1}{125}$ inch, blocked by fatty matter. (120 diam.)

FIG. 2.—Cerebral artery $\frac{1}{325}$ inch diam., obstructed by fatty matter. (120 diam.)

FIG. 3.—Cerebral artery $\frac{1}{400}$ inch diam. containing oil drops. Coats fairly healthy. (400 diam.)

FIG. 4.—Portion of an artery in a state of corpuscular degeneration; (a) channel; (b $b.'$) thickened wall. Diam. of (a) = $\frac{1}{81}$ inch, of (b) = $\frac{1}{81}$ inch, of (b') $\frac{1}{325}$ inch.

FIG. 5.—Portion of a degenerated cerebral artery, normal structure quite lost. Diam. $\frac{1}{81}$ inch.)

From drawings by Dr. Handfield Jones.

Fig 1.

Fig. 2.

Fig. 3.

Fig 4.

Fig 5.

Lebon & Co

Occasionally atheromatous deposits take place in the adventitia or adjacent connective tissue without encroaching on the inner coats. The oil drops are often seen lying in the midst of opaque finely molecular matter, which is probably of the same nature, as it appears white by direct light, and is produced evidently under the same circumstances as the oily, and seems to be affected by osmic acid in the same way. In some instances the presence of the opaque matter constitutes the sole change in the part, few or no oil drops being visible, only the wall for a distance of some length —in one case $\frac{1}{11}$ inch—appears darkly shaded. Much pains were taken to discover whether any corpuscles were present in the atheromatous patches, which by degeneration generated the oil. None such were found in most of them, but in large dilatations, and in some places where the wall of a vessel was extensively diseased, corpuscles were present abundantly. It was clear that they were not essential to the formation of fatty masses. In diffuse atheroma, as will be said, corpuscles are frequently present in the substance of the wall, but do not seem to produce fatty masses. The nature of the deposits was clearly shown by the action of osmic acid, which changed their glistening aspect to a dead black. The patches were often singularly local. Thus a trunk would break up into numerous branches, and these again into smaller vessels, all of which, with the exception of one or two, might be quite healthy. But in these the deposits might be of considerable size. The question of course presents itself as to whether the oily matter was laid down *in loco*, or whether it was carried from pre-existing foci in large vessels, and arrested in the small ones after the manner of an embolus. The former seems to have been by far the most frequent occurrence. For, on the embolic view, it would be difficult to account for so many branches of a trunk remaining healthy, or for the presence of finely molecular matter in a tract of some length, or for the accumulation of fatty matter at one spot sufficient to distend and block up the artery. The healthy state of the coats of the artery in very many places where fat was deposited in quantity, and the frequent absence of corpuscles (albuminous), and the comparative rarity of clot, disincline me very much to regard the process as chronic inflammation. Neither do I think it is fatty degeneration, at least invariably, but more often a true deposition of oil from the passing blood. I have never seen any fatty degeneration of endothelial fragments, which are often present.

In the diffuse form a vessel of large size, say $\frac{1}{100}$ inch, with numerous branches, appears more opaque, often much more opaque than usual, of a brownish-red colour, with more or less numerous minute oil drops here and there, and occasionally larger amounts. The several layers of the wall, and the contained channel, are not well seen. Osmic acid darkens the colour of the vessel decidedly, while liq. potassæ makes it much more translucent. In some instances the opacity of the wall is evidently due to the presence of multitudes of minute oil drops closely crowded together. This condition seems to me nearly identical with that above described, where finely molecular matter is blended with distinct oil drops. It often prevails very extensively, affecting many vessels. It is now and then associated with a seemingly opposite state, where the wall of a vessel appears abnormally translucent, with its channel clear and glistening. The vessel looks as if filled with some refractive colloidal or oily matter, and in some instances I think actually is. In one of my preparations a branch in this state passes off from a larger one, which is markedly affected with diffuse atheroma, and the transition from the reddish-brown opacity of the one to the translucency and glistening of the other is quite abrupt. Diffuse atheroma in minor degrees is very frequent, much more so than the local massive deposits. Both forms probably are detrimental to cerebral activity by impeding the flow of blood in the organ.

Another morbid condition of the cerebral arterioles occurs also very frequently. I term it "corpuscular degeneration," but it is evidently the same change which Cornil and Ranvier describe as *end-* and *peri-*arteritis, and regard as truly inflammatory. In a well-marked example before me the whole diameter of the vessel equals $\frac{1}{75}$ inch, while the channel measures only $\frac{1}{675}$ inch. The wall, therefore, is prodigiously thickened in consequence of a massive growth of corpuscles, but its normal tissues have almost completely disappeared. The layer of corpuscles is much thicker at some places than at others. In one of my preparations an otherwise healthy artery shows at one margin three low hillock-like elevations arising from the adventitia, with two similar but smaller on the opposite side. These consist of the same indifferent nucleated corpuscles as are present in the first specimen, and constitute, I believe, an early stage of the same process. In other specimens similar corpuscles are developed more or less abundantly from the inner surface of the vessel, the outer layers remaining unaffected. In some vessels

treated with acetic acid the whole structure broke down under the weight of the covering glass; all appearance of a tube was lost, and all that was left was a granulous tract thick-set with nuclei and leucocytes. In vessels where the corpuscular growth proceeds from the inner surface long tracts of quasi-coagula are often seen occupying more or less of the channel, thick-set with corpuscles like leucocytes, and full of micrococci. Besides these, vessels are very often found in which all trace of normal structure has disappeared, as well as of corpuscular growth, and the artery is reduced to a mere strip of fibroid and granular stuff without any apparent canal. In one of my preparations a peculiar coagulum occupies the former channel at one end for some distance, while the greater part of the vessel is in the condition just described. I am much disposed to regard these conditions as later results of corpuscular overgrowth, the process terminating in destruction of the artery. Whether this be so or not there is no question of the great frequency of these lesions. They are met with in persons dying from the most different diseases, in the young as well as in the middle-aged. That they are produced by inflammation seems to me very doubtful. It is true that yellow corpuscles or granules are often present on the outer surface of the atrophied vessels, but they are not present on those where the corpuscular hyperplasia is in full activity, and the same are often met with on the surface of vessels which show no trace of degeneration. Besides, the process seems to go on silently and without symptoms, and it is difficult to conceive of active inflammation being limited to a minute vessel here and there. I imagine the process to be somewhat of the same nature as gives rise to Pacchionian glands and fibroid outgrowths from the arachnoid. Another argument against their inflammatory origin is that, in a case of scrofulous meningitis, where the pia mater was crowded with corpuscles, the walls of the vessels preserved for the most part their normal structure, and were not at all, or but slightly, infiltrated with the inflammatory growth.

Micrococci, or objects closely resembling them, are present, as stated, in many clots, and corpuscular coagula, in aneurismatoid bulgings and in fatty masses. They may also be present, I am inclined to believe, in otherwise healthy arteries; but on this point and as regards their pathogenic faculties, I would speak very doubtfully, and hope to make further observations.

April 17th, 1883.

Report on Dr. Handfield Jones's specimens of obstruction of the cerebral vessels by atheroma.—We have carefully examined Dr. Handfield Jones's specimens of cerebral arteries, and agree generally with his descriptions of the appearances seen. We have had submitted to us preparations in glycerine.

The vessels show in all or nearly all cases fatty degeneration, either of the inner or middle coat, the tissues containing oil-globules and granular matter. In a few instances granules of yellow pigment are seen on the outside of the vessels.

Besides these changes there are seen in many places masses of fatty or oily matter either in the form of oil-globules or of larger accumulations, which in some cases completely fill the lumen of the vessel. There are also in some places similar fatty masses, larger and smaller, free, outside the vessels, which have escaped from their cut ends after the preparation of the specimens, possibly displaced by the pressure of the cover-glass.

The walls of the vessels are in some cases degenerated at the spots where the fatty masses are found within the vessels, in other cases they are unchanged or nearly so at those spots.

Masses composed of granular matter, not obviously fatty, are also found in some cases filling up the vessels.

There are aneurysmal dilatations of some small arteries.

With respect to the origin of the fatty and granular masses thus found filling up the vessels, two hypotheses might be made. (1) It might be supposed that these masses had been transported from a distance to the small vessels which they block; in other words, that they were embolic; (2) or that these masses had resulted from fatty degeneration or atheroma of the vessels in which they were found, being formed of fatty molecules, &c., which had become detached and fallen into the cavity of the vessel, where they coalesced into larger drops. This process might occur during life or might conceivably occur after the preparations were put up by diffusion in glycerine, it being well known that diffusion of fat frequently occurs in fatty preparations put up in this fluid.

(1) With regard to the first supposition we are not disposed to think that a process of fatty embolism played a large part in the production of the masses here seen. Since the masses are not found, as embolic masses are specially, at the bifurcation of vessels, or in a group of smaller branches lying beyond a bifurcation, as is sometimes the case with fatty embolisms. However, some of the

masses have apparently been dislodged, and moved a short distance from the spot at which they were formed.

(2) Supposing the fatty masses to have been formed, according to the second hypothesis, by the detachment and diffusion of fatty molecules or drops out of the walls at the spot, it remains to consider whether this occurred during life or after death, and even after the preparations were put up.

We observe that the *post-mortem* process has evidently occurred in some instances where the fat in large or small drops is found actually outside the vessels, and has possibly occurred in other instances where the fatty masses are found in vessels whose walls are quite unaltered. Another reason for thinking that this is in some instances the explanation is that the vessels beyond a point of occlusion are often found empty and unchanged, and in no case have we observed any secondary thrombosis of such vessels.

It is therefore possible that a certain part of the phenomena observed are due to this *post-mortem* diffusion.

There is, however, nothing in the appearances to contradict Dr. Handfield Jones's supposition that the vessels were at least partially blocked by fatty matter during life.

We therefore agree with Dr. Handfield Jones that the fatty masses found blocking the small arteries were in all probability derived from fattily degenerated portions of the inner coat of the vessels in which they are found; though we do not regard it as absolutely determined by the specimens shown whether the process took place wholly during life, or whether it was not partly due to the *post-mortem* changes which occur in fatty tissues preserved in glycerine.

It has been suggested (though not positively demonstrated) by Wagner, and possibly by other pathologists, that atheromatous matter detached from the inner surfaces of larger arteries may be carried on by the blood so as to block up smaller arteries and capillaries. However, the only parallel to Dr. Handfield Jones's observations which we have met with is a notice by H. Müller of extreme fatty degeneration of the intima of cerebral arteries in a case of alcoholism with fatal pneumonia, leading to detachment of endothelium and partial blocking of the vessels[1] with degenerated endothelial cells and with fat, and also with a coagulated hyaline material. Similar changes were seen in the ciliary arteries. The

[1] 'Würzburger medic. Zeitschrift,' 1864, vol. v, p. 73.

importance of these changes in relation to delirium and other cerebral disturbances in cases of chronic alcoholism or Bright's disease is evident; and we think that Dr. Handfield Jones has done great service by calling attention to them in his valuable observations.

S. COUPLAND.

June 5th, 1881. J. F. PAYNE.

Postscript to the Report of the Committee.—Since the above report was written and presented we have been favoured by Dr. Handfield Jones with the sight of some specimens of arteries mounted in carbolic solution. They show appearances precisely similar to those seen in the glycerine specimens, viz. oil drops and masses in the walls and the lumen of arteries. This would tend to prove that the influence of glycerine in producing the changes seen was not so great as we thought it might have been. At the same time we desire to express a very guarded opinion as to the amount of detachment of fat masses, and consequent blocking of the vessels, which had taken place during life.

---

13. *Aneurysm of the middle part of the arch of the aorta; death from embolism of the aorta, detached from the left ventricle.*

By SAMUEL WEST, M.D.

WM. F—, aged 37, a labourer, gave the following history: He had been quite well up to seven months ago; he then caught cold, had some difficulty in swallowing, some cough and dyspnœa. These symptoms gradually got worse, and for the month before admission he had been confined to bed.

The physical signs pointed to the existence of a small aneurysm of the arch of the aorta.

The patient had several very severe paroxysms of dyspnœa from time to time, so that his life was many times in danger. In one of these he suddenly jumped out of bed and fell back dead.

The *post-mortem examination.*—Rigor mortis well marked.

Lungs, liver and kidneys congested.

Heart.—Fat; left ventricle slightly hypertrophied. An aneu-

rysm had formed exactly in the middle of the transverse arch and dissected upwards, reaching to 2½ inches from the cricoid cartilage. It descended slightly over the aorta and round the carotids, chiefly the left, this lying in a deep depression between two pouches, one in front and the other behind it. The right pneumogastric and recurrent laryngeal nerves were free of the tumour; the left was immediately upon the posterior wall, and so firmly adherent that it could not be dissected off. The veins all appeared to be free. The trachea on the left side, about ½ an inch above the bifurcation, was blood-stained and thinned, and the aneurysm was pointing here, but had not perforated. Aorta extremely atheromatous; valves healthy. The left coronary sinus was so much pouched as to form a small aneurysm; the whole of the upper wall of the aorta between the right and left carotids was wanting, and formed the mouth of the aneurysm. The left carotid from within seemed slightly constricted at its mouth. The cavity of the aneurysm was pouched in several places, and was large enough to contain a swan's egg. It contained several decolorised clots. The walls, everywhere thin, appearing to measure ⅛ inch in thickness. Lying folded up at the mouth of the aneurysm was a decolorised clot measuring about 5 inches in length, nearly 1 inch in width. This could be readily placed *in situ* in the left ventricle, where it had clearly formed. It was quite decolorised, laminated, flattened, as *ante-mortem* clots always are in the ventricles, and showed two projections, one of which corresponded with that part of the ventricle which led behind the mitral valve to the left auricle, and the other passed in front of the mitral valve into the aorta.

Clots in the heart are very common in cases of gradual death, as in the course of phthisis and morbus cordis. They are large, flat, decolorised, and of the shape of that exhibited, and occur with almost equal frequency on both sides of the heart. Their shape is an exact cast of the ventricular cavity at the end of systole, which on section is a long slit or chink.

On account of their extension behind the columnæ carneæ they can only be detached, as a rule, by some violence; hence the extreme rarity of such a case as the present, where death was produced by the detachment of such a clot *en masse*.

February 20th, 1883.

14. *Aneurysm of the aorta, rupturing into the pulmonary artery.*

By Samuel West, M.D.

Wm. F—, aged 38, groom, was in good health until ten weeks before admission into the hospital. He was then taken ill suddenly during one night with severe pain in the front of the chest, cough, and dyspnœa. He had done no work since that time, and had been getting steadily worse. The cardiac dulness was increased in all directions, the apex being two inches outside the nipple in the fifth space, and the right border being well to the right of the sternum. Heaving was felt over the whole præcordium and in the epigastrium. A coarse thrill was felt in the third and fourth spaces to the left of the sternum. A loud double murmur was heard everywhere, but loudest at apex and at left base, not conducted loudly along the vessels though audible behind. The murmur seemed to commence during the latter part of diastole, and to extend through the whole of systole.

Heart weighed 19 oz. Right ventricle dilated and filled with recent clots. Left ventricle hypertrophied, $\frac{1}{4}$ inch thick; cavity dilated; both sides, right and left, extremely fatty.

No manifest disease visible from the surface, but on opening the right side a hole was found nearly $\frac{1}{8}''$ in diameter, immediately above the septal cusp of the pulmonary valve. This hole was circular, with smooth, clean-cut edges, and situated just above the level of the valve. The pulmonary artery was a good deal thinned for about $\frac{1}{8}''$ all round the hole. The valves were perfectly healthy, except that about a quarter of an inch of the one mentioned was continuous with the margin of the hole.

The aorta was opened from behind, and it was then found that the hole led into an aneurysm of the aorta about the size of a hen's egg, somewhat sacculated, and the walls very thin in places. It had dissected partly between the septum behind the pulmonary valve in the usual direction.

The rest of the aorta was slightly atheromatous in places, but was not otherwise diseased.

The upper margin of the mouth of the aneurysm formed a prominent sharp ridge, in colour and texture like the rest of the aorta.

Other organs slightly congested, but not otherwise diseased, except that the kidneys had one or two simple cysts, but were not fibroid. *February 20th*, 1883.

---

15. *Dissecting aneurysm of the first part of the arch of the aorta.*

By Samuel West, M.D.

Post-mortem examination.—On opening the abdomen the liver was found displaced and twisted, so that the notch was completely hidden by the left costal arch, and the whole upper border of the right lobe exposed below the ribs, the diaphragm on the right side being convex towards the abdomen, and visible from the front. The stomach was much distended and occupied the remaining part of the front of the abdomen, reaching down as far as the pubes.

On opening the thorax the right pleural cavity was found distended with blood-stained serous fluid, and several pounds of recent clot. The heart was displaced far to the left and adherent to the ribs. Occupying the whole anterior mediastinum and extending on both sides of the sternum, though chiefly on the left, was the sac of an aneurysm, nearly globular in shape, and measuring about 4 inches in diameter. It was closely adherent to the under surface of the sternum, which was eroded for a space of about 2 inches in length from the second costal cartilage downwards, and pitted in places by small sac-like pouches from the aneurysm. One pouch of larger size formed a soft spongy swelling in the second right intercostal space. The walls were nowhere more than about $\frac{1}{8}$ of an inch thick, except where they were covered with some layers of old adherent clot. Towards the right side, close under the sternum, the walls had become much thinner, and here was found the aperture where the aneurysm had ruptured. Further back was another thin spot, but this was adherent to the right lung, and had not given way.

The aorta formed a projecting buttress in its left wall, and communicated with the sac of the aneurysm by an almost circular aperture in its walls, on the outer side immediately above the valve; it seemed as though a circular piece had been cut out of the aorta on the right and anterior side. The lower edge was formed by one of the valves, and its sinus of Valsalva; the upper was sharp, thickened, and slightly puckered. Traces of the coats of the aorta could be followed a short distance only from the aorta, the main part of the sac being of adventitious growth.

The pericardium was universally adherent, but the valves and muscle substance were healthy.

The kidneys were markedly granular and very firm on section, and the capsules strongly adherent.

The liver was congested; the other organs healthy.

This case illustrates what I believe to be the rule in large aneurysms springing from the first part of the arch of the aorta, viz. that they originate in small pouches only from the walls, usually on the right side of the vessel, and that it is only when these pouches have ruptured and false aneurysms have formed that large tumours appear. I have met with one case in which a pulsating tumour as large as a swan's egg developed in the front of the chest in an hour, and in a week had reached a very considerable size. After death the true aneurysm was found to be a pouch not larger than a medium-sized Tangerine orange, although the whole tumour was as large as a child's head. *October* 18*th*, 1882.

---

16. *Complete obliteration of one coronary artery; sudden death; remarks upon the anastomosis of the coronary arteries.*

By Samuel West, M.D.

Robert C—, about 40, was an in-patient with morbus cordis. He died quite suddenly after a short stay in the hospital.

Beyond congestion of the various organs no pathological change was discovered, except in the heart and aorta. The aorta was extremely atheromatous, even down to the iliacs.

The heart was considerably dilated and very fatty; the valves healthy, except for a little thickening at the free margin of the aortic valves, but this change did not affect their competency.

The part of the aorta immediately above the valves was in a condition of extreme atheroma and calcification. The right coronary artery was large, but its mouth considerably narrowed by atheroma. The mouth of the left coronary artery could not be found, and on tracing the left coronary up to its origin it was found to be obstructed by a calcareous plate, which covered it completely. The vessel was, however, pervious and of normal size right up to this obstruction.

It is difficult to understand how in this case the nutrition of the heart can have been maintained, if Hyrtl's statement be true, that the branches of the coronary arteries do not anastomose.

The fact that the obstructed artery was of normal size right up to its origin from the aorta shows, in this case at any rate, that the anastomosis must have been free. With the view of determining the question of the anastomosis of the coronary arteries, I injected a series of hearts with gelatine and carmine, sometimes from one coronary artery and sometimes from the other. In all cases alike the whole of the heart was minutely and beautifully injected. The anastomosis is, indeed, so free that on injecting from one coronary artery a stream of injection flows out of the mouth of the other, and the most successful injection can only be made when the other coronary artery is ligatured or compressed. Microscopical examination showed that the injection had travelled even into the minutest vessels.

The hearts which I used for injection were human, which had been macerated for two or three days in water, and before injecting they were placed in warm water. This previous maceration, in order to soften and dissolve any clots present is important, for the only failure I experienced was in a case which I injected immediately after removal from the body, and this may possibly be the secret of Hyrtl's failure. *May 15th*, 1883.

17. *Case of diffuse aneurysm of the abdominal aorta.*

By A. Quarry Silcock, M.D.

The patient, a labourer, æt. 40, was admitted into St. Mary's Hospital, under the care of Dr. Sieveking, on October 25th, 1882. Two years previously, up to which time he had been in good health, he had an attack of rheumatism in the left hip and leg, lasting a week or two; twelve months later he had another attack, lasting a month. Two months before admission the pain recurred, and, becoming continuous, was the cause of his admission to the hospital, and the burden of his complaint until he died. He described the pain as being of a "burning kind," affecting the whole of the left lower extremity. Various local remedies were from time to time applied, but without success. On December 15th, 1882, it was noted that the pain had extended to the right hip across the small of the back, and that there was great tympanitic distension of the abdomen. On January 2nd, 1883, the abdomen, still distended, became generally tender, but there was no evidence that it contained any fluid; in the right hypochondrium there was found for the first time a distinct tumour, which the autopsy showed to be the kidney displaced forwards. Both legs were œdematous, and the patellar reflexes were absent on both sides. His temperature varied at this time from 1° to 2° above normal. He remained much in the same condition until January 4th, when he died somewhat suddenly. During his illness he had become much emaciated, especially during his stay in the hospital. Though carefully sought for, no abnormal pulsation was discoverable in the abdomen from first to last.

A depressed scar on the glans penis, and indurated lymphatic glands in both groins (without any scar of a bubo), rendered it probable that he might have contracted syphilis.

Post-mortem.—On opening the abdomen 400 c.c. of clear serum were removed. The whole of the viscera were evidently displaced forwards by a tumour (which was afterwards found to be blood-clot) situated behind the peritoneum. Both kidneys were flattened out on the mass, especially the right, and firmly adherent to the subjacent parts. The right ureter was constricted by old adhesions near the brim of the pelvis, above which point it was considerably dilated. The under surface of the liver was extensively

adherent, but no obstruction to the portal veins could be made out. Both aorta and vena cava lay anteriorly and were firmly adherent to the mass, but there was no obvious obstruction to either; 7 lbs. of clot were turned out, for the most part laminated, and evidently deposited weeks or months previously; and other portions were fresh, evidently *post-mortem*. The effusion extended upwards as high as the tenth dorsal, and as low as the intervertebral cartilage between the third and fourth lumbar vertebræ; laterally as far as the outer border of the quadratus lumborum on either side; limiting it in front were the thickened peritoneum and subperitoneal tissues, with layers of old laminated clot attached thereto. On this cushion of blood, so to speak, lay the liver, spleen, kidneys, great vessels, and intestines. The effusion had evidently been derived from the rupture of a sacculated aneurysm of the aorta, which sprung from the posterior wall of the vessel, opposite the superior mesenteric. The opening from the aorta into the cavity of the aneurysm was the size of a florin, but the true arterial coats could be traced but a short distance (a radius of two inches) around it into the walls of the sac. The bodies of the twelfth dorsal and first and second lumbar vertebræ were extensively eroded, the corresponding intervertebral cartilages being intact with the exception of that between the first and second lumbar, which was to a great extent absorbed, a considerable amount of rotatory movement being permissible in this joint. The left transverse processes of the first two lumbar vertebræ were also much eroded, together with the corresponding pedicles, the spinal canal being thus opened up and the dura mater exposed over a surface as large as a kidney-bean. From the front of the body of the second lumbar vertebra projected a sharp bony spicule, about the size and somewhat the shape of a thumb-nail, probably an eroded osteophyte, several of such growths being attached to the spine in the dorsal region. The effusion in its downward course had distended the sheath of each psoas magnus muscle; on the left side the muscle was almost totally disorganised, its sheath containing fluid detritus of muscle-fibre and blood-clot, thus laying bare the cords of the lumbar plexus, and forming a fluctuating tumour, which passed beneath Poupart's ligament in the position of and simulating an ordinary psoas abscess. The sheath of the right psoas was also distended, but the muscle was only partially destroyed, and the effusion did not extend below Poupart's ligament; just above this point, how-

ever, it had burst through the sheath, forming a large recent extravasation in the anterior abdominal walls as high as the ninth rib, beneath the transversalis muscle. Both external iliac veins were involved in old adhesions and compressed by the effusion. The whole of the aorta was generally atheromatous, especially opposite the fourth lumbar vertebra, where there was a large atheromatous ulcer beset with calcareous plates, and about the origin of the great vessels of the neck. An inch and a half above the sinuses of Valsalva was a commencing sacculated aneurysm springing from the great sinus of the aorta, as large as half a walnut. The whole of the ascending aorta was dilated, the remaining portion more or less so. The aortic valves were thickened but perfectly competent; the sinuses of Valsalva greatly dilated and atheromatous, the orifices of the coronary arteries being involved. The heart was fatty and fibroid; its valves and cavities not affected in any marked degree. The liver, spleen, and kidneys were fibroid, the latter containing old infarcts.

Remarks.—The chief features of interest in connection with this case would seem to be the magnitude of the effusion and the extreme erosion of the spine, in contrast with the few symptoms and physical signs present which could guide one to a correct diagnosis. In vol. xxi of the Pathological Society's 'Transactions' Dr. Murchison records a case, accompanied with chronic peritonitis and liquid effusion, bearing some resemblance to this one; in vol. xix another is detailed, which was very similar to it. In the latter the blood followed the course of the psoas muscles, giving rise to a pulsating tumour in the upper third of the thigh, and Sir William Fergusson ligatured the femoral artery. Other cases are known which, a bend having arisen in the spine consequent upon its erosion by an aneurysm, with gravitation of effused blood to the iliac fossæ, were mistaken for caries of the vertebræ with abscess, and treated accordingly. In the absence of pulsation in the tumour, as in the present instance, the idea of retroperitoneal malignant disease would probably suggest itself, and it is not easy to see how such an error could have been avoided. It may be remarked that the ascending portion and that between the pillars of the diaphragm are the most usual positions of an aneurysm of the thoracic and abdominal aorta respectively; that the seats of the aneurysms were not those of the most extensive or advanced atheroma; and that the aortic valves being competent and un-

affected there was no hypertrophy of the heart, as frequently is asserted to be the case as a result of aneurysm.

February 20th, 1883.

---

18. *Aneurysms in children.*

By NORMAN MOORE, M.D.

1. A GIRL, aged 7 years, who died suddenly in the out-patient room of St. Bartholomew's Hospital. She had been very ill for six weeks, and had previously had acute rheumatism. A loud double murmur had been heard at the base, and a systolic murmur at the apex. She had well-marked clubbing of both fingers and toes, and general anasarca. The heart was hypertrophied. The valves of the right side were normal. On the mitral valve there were several small growths, and on the aortic valves some large and partly calcified growths. The aorta itself was normal. On the right common iliac artery there was an aneurysm as large as a hazel nut. The sac was filled with laminated fibrin, leaving a passage down the vessel which admitted a fine horsehair. A microscopic section of the aorta showed that it was perfectly normal, and a section of the wall of the aneurysm showed a normal condition of the coats, with the exception of a very slight cellular infiltration immediately beneath the endothelium. There were no projections from the surface of the endothelium, or other evidence of acute internal inflammation of the artery. Nor was there any sign of degeneration or other chronic change. The left iliac and other large arteries were normal.

In this case it seems probable that the aneurysm was due to a plugging of the artery by an embolus carried off from the aortic valves in the way first described by Dr. J. W. Ogle, and of which Mr. G. W. Callender recorded some instances in the pulmonary artery.

2. A girl, aged 5 years, who died of tubercular meningitis in St. Bartholomew's Hospital, under the care of Dr. Andrew. Her heart showed growths on the tricuspid, mitral, and aortic valves; those upon the aortic valves being very large. Above the valves there

was a shallow aneurysmal pouch on the posterior wall of the aorta. In the pouch were several small endarterial growths which, like those on the aortic valves, were capped with a thin layer of loosely-attached fibrin. The aneurysm in this case was probably due to an acute endarterial inflammation contemporaneous with the endocarditis in which the growths on the valves had originated.

Thus the two specimens illustrate two distinct methods in which aneurysm may be produced in a young and undegenerate artery, viz. (1) by distension occasioned by an embolus; and (2) by acute inflammation of the inner coat of the vessel.

October 17*th*, 1882.

---

19. *Thrombosis of the pulmonary artery (para-vaginal and dermoid cysts).*

By F. A. Mahomed, M.B.

When we hear or read accounts of clots moulded to the cavities of the heart or large vessels, and said to have been formed during life, the position we usually take up is one of profound scepticism. This is one of the things we require to see before we can believe. It is exceedingly difficult to conceive that any considerable amount of clot can be laid down in the course of a rapidly flowing blood stream, and on the normally smooth surface of the endocardium. We are all familiar with *ante-mortem* coagula in the ventricles or auricles adherent to vegetations, or atheromatous ulcers on valves or on walls of large vessels, or occurring in the remote corners of greatly dilated cavities. It is the large, well-moulded, smooth, juicy clots which are said by some to occur just preceding deaths which are sudden, and of which they are believed to be the cause, which are regarded with so much scepticism. These are found completely filling either the pulmonary artery, the aorta, or one of the large cavities, and are supposed to be deposited owing to some chemical or vital defect in the blood. These were described some thirty years ago by Dr. Richardson, and he still believes in their frequent occurrence. Recently Sir Joseph Fayrer has recalled observations made by himself nearly twenty years ago, and has added to them others, in which he believes that such coagulations

of blood caused death after operations, especially when there has been septicæmia or a taint of malarious poison in the blood. But all observations on these clots require more lengthy descriptions of the clots themselves, of their physical characters, of the conditions of the blood in the other vessels, and especially of the relative positions of the black and white clots in various parts of the body. Many of these details are lacking in the cases that have hitherto been recorded in which these clots are believed to have caused death. They are conspicuously absent in a paper in the 'Journal of Anatomy and Physiology' of January, 1883, on "Fibrinous Coagulations in the Left Ventricle." In this paper, during a possible period of seven years' observations, extending over a somewhat limited field, the observer thinks he has seen twenty such cases, that is, nearly three in each year! The details given concerning these clots are very imperfect, and some of the characters that are mentioned are well explained by their *post-mortem* formation.

The clots I bring before the Society are, I believe, the first of this kind that I have ever seen in which I considered there was good evidence of their *ante-mortem* formation. In this case the clot filled the pulmonary artery in all its branches, but at the same time it has the usual appearance of an *ante-mortem* clot. It is not, I think, one of those which have been described by the observers already mentioned, but it is as near to such a clot as I can conceive possible.

C. H—, a female, aged 49, was admitted, under the care of Mr. Howse, on November 29th, 1882, for epithelioma of the cheek. Her death occurred on December 25th, 1882. She was married and had had six children, two boys and four girls; two miscarriages, the first at seven weeks, the second at four months. For my present purpose I need not give the details of the surgical aspect of her case. The growth was successfully removed from her cheek on December 8th, and the wound healed rapidly. On December 22nd a second small operation was performed for the removal of an enlarged gland near the right angle of the lower jaw. She was doing perfectly well till the afternoon of December 25th. The note in the report for this day is as follows:

"At 12.30 temperature 99·2°.

"At 1.30 she had her dinner, consisting of a little beef tea, gravy, some fish with the bones removed, and custard pudding. She ate but little, and shortly afterwards, about 2.30, she lay back

in her bed, saying she felt faint; her face became ashy white and her lips blue. She recovered from this condition, and then passed a motion, and as she had frequently been in an exhausted condition when passing her motions previously the fact of her fainting was not thought of much account. At 3 o'clock she passed another motion; this was rather loose, but the former had been perfectly normal. At 4 o'clock she again became faint; her face was white and she had no pulse. The house surgeon was sent for, and he administered brandy and nitrite of amyl, but these remedies had no effect in restoring the pulse; there was no dyspnœa; the patient sank and died quietly at 4.30."

At the *post-mortem* examination, made forty-eight hours afterwards by myself, there was little if any sign of decomposition; the rigor mortis was severe. *Brain* healthy; the vessels contained no *ante-mortem* clot, but a little imperfectly coagulated black clot. The growth had been completely removed, but there was one gland in the neck, below the tonsil, which was slightly infiltrated by the growth. *Pleuræ* non-adherent; there were slight subpleural hæmorrhages near the bases of both lungs; there were two patches of pulmonary apoplexy at the right base, neither larger than a walnut; there was a good deal of œdema of the lungs, which, with the exception of one small cicatricial nodule, were otherwise healthy; the bronchial glands were normal. *Heart* weighed 9½ oz.; the muscular fibre was good; the left side was empty except for a small shred of quite soft black clot; the auricle also contained a little clot but there was no *ante-mortem* clot; the valves were healthy; the right ventricle was empty; the valves were normal. The clot exhibited was found accurately moulded to the pulmonary artery and ramifying through all its branches; it was of a dark red colour and covered by a very thin layer of perfectly white fibrin. My first impression, from the dryness and density of this clot, was that it was *ante-mortem*. On finding that it extended into and was moulded to every large branch of the pulmonary artery in both lungs I thought it must be *post-mortem*, but on making a section through it I found that it contained a central clot which was of the same dark red colour, and was firm and crisp, and had a thin layer of fibrin around it, this inner clot could be squeezed out of the outer clot like a finger from a glove; the outer clot was about half an inch in diameter, and the inner clot, in the main trunk of the artery, was three eighths of an inch in diameter. Both clots were

remarkably dense, dry and firm, especially the inner one. Most of the large vessels, both arteries and veins, were examined but no similar clot could be found in them. The clots in other parts of the body were black and soft, presenting the usual characteristics. The *liver* weighed 52 oz., it looked rather fatty and was somewhat deformed by tight corsets. The *spleen*, 7 oz., was healthy. The *kidneys*, 7½ oz., peeled well and were healthy. The other organs were all healthy with the exception of the pelvic viscera which are also exhibited this evening. The left ovary contained a large pear shaped cyst 4½ × 3 inches with shiny, smooth wall. The cyst contained a mass of the ordinary butter-like material, consisting of epithelial débris, in which were found several short hairs but no teeth or bones. Attached to the cyst were the shrivelled remains of the ovary; and several short hairs sprouted from the ovary into the cyst. The right ovary and both the Fallopian tubes were normal. A still more interesting cyst was found between the vagina and rectum; this formed an egg-shaped tumour; it measured 7½ × 5½ inches at its broadest part; its walls were thin and did not infiltrate or thicken either the rectum or vagina or peritoneum above it; it contained 2 pints 6 oz. of sweet pus and a large number of yellow cheesy bodies, much resembling blackberries in size and shape and of putty-like consistency. The inside of the sac was perfectly smooth at all points; crossing the lower part of the cavity, on its left side was a band three inches in length ending in an indurated nodule in its posterior wall, of cartilaginous consistency, which on being dissected out was like a small wedge-shaped nodule of cartilage ½ × ⅛ inch, the band was neither Fallopian tube, round ligament nor ureter. The posterior wall of the vagina was much stretched and its rugæ were completely smoothed out, the os was drawn downwards and flattened out showing no projecting lips, the tumour being placed behind the neck of the uterus and the upper two thirds of vagina. The lower five inches of the rectum presented a large number of greatly distended veins, evidently owing to impeded blood return through the superior and middle hæmorrhoidal veins. This probably belongs to the para-vaginal cysts developed according to Coblentz (Virch. 'Archives,' band lxxxii—lxxxiv) from the lower part of Gaertner's duct. This was of course the cause of her straining and faintness when the bowels acted. It is remarkable that notwithstanding this she should have borne a family of six children.

The hypothesis I would suggest concerning the formation of the clot is that a small thrombus formed in the hæmorrhoidal veins, had been carried through the systemic circulation to the lungs and formed an embolus, giving rise to the pulmonary apoplexies at the base of the right lung. To the small clot formed in one of the peripheral branches of the pulmonary artery accretions may have been gradually added, till the clot had spread into nearly all the branches of the vessel. From the chief branches a clot may have projected into the main trunk, but not completely occluded it, and at the time of death the right ventricle contracted and discharged its contents, which coagulated around the projecting clot which had formed previous to death; but I must confess that though it would be possible to satisfactorily explain a clot occupying the artery of one lung in this manner, it is somewhat difficult to conceive how it could have spread to the artery of the opposite lung.

I contribute the case as a possible link between the ordinary *ante-mortem* clots and those more rapidly formed and alluded to in the commencement of this paper, and I would express a hope that any member of the Society who meets with these doubtful *ante-mortem* clots in future would bring them before us for examination.

Note.—Since reading this paper I have carefully examined the contents of the pulmonary artery in many cases, and have been surprised at the large number of branches which are found occluded by *ante-mortem* clot in cases in which it has clearly commenced at a point of disease in the lung, at which coagulation has taken place in the peripheral branches and has extended backwards towards the main trunk. *February 6th*, 1883.

---

20. *Abnormal aortic valve.* (*Card specimen.*)

Exhibited by W. A. Berridge.

From a young man, aged 22, who fell down dead. He had never been ill in his life, or in bed a day. In the early morning he had been at work on the roof of a house, and walked home to breakfast a quarter of a mile. Just as he reached the house on his return he fell with his face into a puddle of clay, was picked up within two minutes, but was quite dead.

When seen by me half an hour afterwards he was much cyanosed. His nostrils were blocked with wet clay, and there was some dirt in

his mouth. He had had an attack of syncope, had fallen into clay and water with his face, and died suffocated. I have known him four years.

His mother suffers from valvular disease of heart. I attended his aunt, who died last year from heart disease and ascites; and I am now attending another aunt with the same diseases. Last year I also attended a cousin who died of heart disease.

The left ventricle was hypertrophied. There was no other disease. *January 16th*, 1883.

21. *Vessels from a case of gangrene of the right leg caused by thrombosis of left common iliac artery, and detachment of a portion of the clot.* (*Card specimen.*)

Exhibited by J. KINGSTON FOWLER, M.D.

THE abdominal aorta and large vessels of the lower extremities containing numerous thrombi. (The vessels have been opened on their posterior aspect.) There is extensive atheromatous disease of the vessels in an early stage. The *left* common iliac artery is completely blocked at its origin by a thrombus, which is connected with another situated just above its division into external and internal iliac; the latter artery is normal but contracted. The *right* iliac and femoral arteries are free up to within an inch of the origin of the profunda, where a branched clot occludes both trunks. The femoral from the lower end of this thrombus to within 4 inches from the point where amputation was performed, was obliterated by adhesion of its walls around a small clot. The lower part contains a buff-coloured thrombus firmly adherent to the tunica intima. The vein was ligatured and contains a clot 3 inches long.

Taken from a man, aged 42, under Mr. Hulke's care in the Middlesex Hospital, who died after amputation of the right thigh for gangrene.

Three weeks before admission he was seized with a sudden pain in the right foot, followed by coldness, formation of bullæ, and gangrene, which on admission extended upwards to within 2 inches of the tibial tubercle. There was a gangrenous patch over the inner tuberosity of the right femur. Femoral artery could be felt pulsating to Poupart's ligament. The right thigh was amputated in the lower third. The popliteal was found to be plugged, and for a short distance all its main branches also. There was extreme stenosis of the mitral valve, but no vegetations or roughness. Possibly the thrombus in the left common iliac was first formed, and a portion of this may have been swept into the right femoral and lodged in one of the vessels of the foot. This probably caused secondary thrombosis. The anastomosis must have been from the internal iliac of one side to that of the other. *November 21st*, 1882.

22. *Aneurism of aorta.* (*Card specimen.*)

Exhibited by R. E. Carrington, M.D.

George P—, aged 55, admitted into Guy's November 20th, 1882, died February 19th, 1883.

The specimen shows two aneurysms of the aorta. One, the size of a pigeon's egg, rising from the anterior part of the arch. This bulged the chest wall opposite the left second and third costal cartilages, close to the sternum. The other extended from the back and upper part of the thoracic aorta, eroding the bodies of the fourth, fifth, and sixth dorsal vertebræ. The sac communicated by two openings with the vessel. It pressed upon and occluded the left bronchus, causing ulceration of the opposed surfaces and the death of the patient. Both sacs were filled with firm laminated clot, and were apparently well advanced towards spontaneous cure, yet they were both extending.

February 20th, 1883.

23. *Congenital atresia of right ventricle, ductus arteriosus patent.* (*Card specimen.*)

Exhibited by John Abercrombie, M.D.

This heart was taken from the body of a female infant aged 5 months. During life it was observed that she was cyanotic, and that the fingers were slightly clubbed. There was no murmur with the heart sounds. It will be seen that the left ventricle is much dilated and hypertrophied, forming by far the greater part of the bulk of the heart. The mitral and aortic valves are natural. The right auricle is greatly dilated and somewhat hypertrophied, and communicates with the left auricle (which is considerably smaller) by a widely patent foramen ovale, which measures one third of an inch across. The tricuspid orifice is found to be no bigger than the diameter of a hemp-seed, and is completely obliterated by a fleshy-looking mass, so that it leads nowhere. The aorta is dilated and hypertrophied (?). The pulmonary artery is exceedingly small, especially just above the base of the heart; it widens out further on. On slitting down the pulmonary artery its orifice is found to be completely obliterated, and the cusps are seen as small fleshy granulations. On continuing the incision through the obliterated pulmonary orifice into the heart wall, no trace of a ventricular cavity can be made out, the right ventricle being represented by a bundle of muscular fibres appended to the base of the left ventricle. The ductus arteriosus is found to be pervious, and at this point the artery divides into its right and left branches. The other viscera did not present any important lesions.

April 17th, 1882.

IV. DISEASES ETC., OF THE ORGANS OF DIGESTION.

1. *Carcinoma of œsophagus.*

By Norman Moore, M.D.

The carcinoma occupied a somewhat exceptional position, the middle third of the œsophagus. It infiltrated the whole wall, and had caused a stricture, just admitting a large probe. The œsophagus was adherent to the lung, and at the point of adhesion its wall was perforated. The lung at this point was pneumonic, not gangrenous. Secondary masses were shown in the small intestine, liver, spleen, mesenteric glands, and both lungs, and there was one nodule in the outer wall of the left ventricle. All had been examined microscopically, and showed a large celled epithelial growth with an abundant stroma, exactly similar in character to the primary growth in the œsophagus. All the secondary masses were very firm, and those in the ileum were of the same shape as the new growth in the œsophagus, that is to say they encircled the tube and infiltrated all its coats.

The patient was a man aged 56. His first symptoms of dysphagia were in May, and he died in December, so that the duration of the new growth was about eight months. Thirteen cases of cancer of the œsophagus have been examined at St. Bartholomew's during the last fifteen years. All were males. In seven the lower and in five the middle third were affected. In four cases secondary growths were found in the lungs, in one in the heart. Exhaustion was the commonest cause of death. Hæmorrhage was fatal in two cases; pleurisy in three; gangrene of the lung in one. The earliest age of occurrence was 36, and the latest 58. The following is a table of cases examined by me at St. Bartholomew's, in which a microscopic examination determined the new growth to be a carcinoma. In none were there any cell-nests.

Table of cases of carcinoma of œsophagus (1880-1883).

No.	Sex.	Age.	Situation of Growth.	Secondary Growths.	Adhesions.	Other Notes.
1	M.	53	Lower third.	None.	To right lung.	Gangrene of lung.
2	M.	52	2 in. above diaphragm.	None.	None.	ex. micro.
3	M.	54	Lower third.	Stomach, liver, kidneys, left supra-renal, heart, bronchial glands.	To bronchial glands.	—
4	M.	56	Lower third.	Left pleura, pericardium, liver.	None.	—
5	M.	56		Small intestine, liver, kidneys, spleen, left ventricle.	To right lung.	Pneumonia.

January 2nd, 1883.

---

2. *Cancer of œsophagus with perforation into the right lung, the upper lobes of which were converted into a cavity filled with decomposing food.*

By Frederic S. Eve.

James W—, aged 42, was admitted into St. Bartholomew's Hospital under the care of Mr. Langton.

He complained of dysphagia, and stated that he had been unable to swallow solid food for three months.

He had recently been an in-patient at the Victoria Park Hospital, and whilst there his dysphagia was twice relieved by "something breaking in his throat," when he coughed up a good deal of offensive material.

A small œsophageal bougie was passed.

On the ninth day after admission he again ejected much offensive material, and at the same time experienced the sensation of something bursting in his throat.

Whilst in the hospital a considerable part of the food taken by the mouth, after being retained for some time, was returned mixed with mucus.

On the eleventh day he was attacked with dyspnœa, and died on the following day.

Autopsy.—About the level of the bifurcation of the trachea the œsophagus was constricted to one quarter of an inch in diameter by a hard cancerous growth—creaking under the knife—which infiltrated about one inch and a half of its length. Near the upper end of the constriction, on the right side, was an ulceration with some dilatation of the tube, at the bottom of which were two fistulous passages the size of crow-quills; these passed directly into a large cavity, occupying the whole of the external portion of the two upper lobes of the right lung. The cavity was filled with fœtid, semi-fluid, or pultaceous food; its walls were formed by sloughing pulmonary tissue, and were traversed by blood-vessels, which had longer resisted the destructive process; near the apex the wall consisted only of the pleura, here adherent to the chest wall; the cavity was of an elongated form, and extended from the apex of the lung to the fissure between the middle and lower lobes; the lower lobe was solidified by pneumonia. On the left side of the œsophagus, slightly higher up, was a smaller ulceration, with two fistulous passages extending into the cellular tissue between the œsophagus and trachea.

The tumour was a cancer of the glandular type, not an epithelioma. *November 21st*, 1882.

---

3. *A case of ruptured stomach.*

By John R. Lunn.

C. B—, aged 4 years, male, was admitted into the Marylebone Infirmary, Notting Hill, on Sunday, December 24th, 1882, about 2·30 p.m., run over by a two-wheeled cab, which had one person inside. When admitted he was rolling about and putting his hands to his stomach as if in pain. Abdomen distended, but resonant all over and no lump to be felt. The left wrist was much bruised. No bones broken. Some blood oozed from left nostril, which apparently came from his stomach or lungs. He died the same

evening about 6.30 p.m. Nothing was found in his lungs by auscultation.

Post-mortem notes.—When the abdomen was opened some semi-digested food was found in the abdomen amongst the coils of the intestines mixed with some blood.

The intestines were distended with gas, the stomach partially collapsed, and, at the splenic end of the stomach, were two ruptures about one inch in diameter at the commencement of the greater curvature; the rest of the mucous membrane healthy.

No fractured ribs or other bones broken.

Other viscera quite normal. *January 2nd*, 1883.

---

4. *The stomach from a case of acute gastrorrhœa or acute dilatation of the stomach; death within forty hours of the onset of vomiting.*

By Henry Morris.

Alfred S—, aged 37, a valet, was admitted into the Middlesex Hospital under me on October 9th, 1882, with suppuration of the right ankle-joint.

In June, 1882, he first noticed a slight pricking pain on walking in the right ankle, and after exertion the ankle became puffed. By degrees he walked worse and worse until at length he could not get about at all. For five weeks before admission he had not put his foot to the ground.

Since May, 1882, his right wrist had been somewhat swollen, and the muscles of the right arm had been wasting. He says that for some years he has suffered from asthma and bronchitis. There is no family history of phthisis. He has never had any venereal disease or rheumatism, and has led an abstemious life.

On admission it was noted that he was very thin, of narrow, spare frame, with a face pinched and hollow, and with dark rings about his eyelids. His skin was of a dark, sallow hue. The right ankle was uniformly swollen and tender, but there was no œdema or superficial redness about it. He complained of dartings in the foot whilst dozing in the day and whilst sleeping at night. He did not complain at all of his wrist. He had a slight cough, and

vomicæ were detected in the apex of each lung. His temperature was not above normal. His pulse regular, but weak. Urine normal. Appetite and digestion very good.

As it was obvious that the ankle-joint was full of pus a mixture of ether and chloroform (two parts of ether to one of chloroform) was administered, and an opening was made into the joint on the outer and inner sides. The joint was irrigated, dressed with terebine and oil on lint, fixed in a splint, and covered with absorbent cotton wool.

All went well till November 6th, when the local symptoms led me to think that possibly a sequestrum might be keeping up the discharge from the outer wound.

His general condition remained the same as when admitted, his appetite was good, bowels acting, pulse regular though weak, and his temperature was in the morning about 99°, and in the evening about 100°, never reaching a higher point except on the night previous to the second administration of an anæsthetic, viz. November 10th, when it was 101°.

About 8.30 p.m. on November 11th (Saturday) ether was given by the resident medical officer, but as this seemed to irritate it was changed after about half a dozen inhalations for chloroform. The ankle was again examined, and a considerable quantity of soft gelatinous matter was scraped away through the outer wound. Bony grating was detected in the joint, but no sequestrum. The limb was dressed and fixed as before. These proceedings might have occupied from fifteen to twenty minutes.

About an hour after chloroform was discontinued the patient began to vomit quantities of thin greenish fluid which came up in mouthfuls at a time, and without any pain or effort on his part. The vomiting was repeated, at frequent intervals, all through the night and the next day and following night, and up to the time of his death, which occurred about eight o'clock on the morning of November 13th (Monday).

The character of the vomited matter was the same throughout, viz. a thin, green watery fluid, neither frothy nor offensive, and not mixed with any particles of food. The fluid was brought up in large gulps without straining; it was, indeed, almost shot out of his throat. The sister of the ward said it was like the vomit she often sees just before death; she was in consequence alarmed from the very first about the patient. The longest interval between the

acts of vomiting was from eleven to twelve on Saturday night, whilst a mustard poultice was applied to the epigastrium. The quantity vomited was described to me by the sister of the ward as being at least ten pints; there might have been a good deal more, she added, but she was sure there was no less. The patient imagined he must have brought up a much larger quantity, and on Sunday morning remarked that he was sure he had vomited "gallons."

He had been prepared for the anæsthetic in the usual way, that is, he had taken a dose of house medicine early in the morning, and later on had an enema. The bowels had acted freely. At 10 a.m., *i. e.* rather more than five hours before taking chloroform, he had a meal of jelly, beef tea, and bread. After this he took nothing into his stomach except a little ice and a dose of bismuth mixture, which was given to allay the sickness, until 3.30 p.m. on November 12th (Sunday), when he tried to keep down a cup of tea. On Sunday morning his temperature was 97° F., and on Sunday evening 96° F. Twice between Saturday evening and Sunday morning he passed urine, but not more than two ounces at a time; afterwards he passed none at all. He did not perspire. He could not lie down, but sat bolstered up in bed, with two or three porringers by his side and nearly always one before him, throwing up the vomit. He was pinched and haggard in face, and the dark rings round his eyes had by Sunday mid-day became more marked than I think I had ever before seen them in anyone. His abdomen was retracted, but not painful or tender on pressure. His skin was cold and dry, and he was intensely thirsty. On Sunday evening the vomiting appeared to (Mr. Fardon) the resident medical officer like that seen at the commencement of intestinal obstruction, and he examined the patient under that impression. He found nothing to support that idea; the abdominal walls were very hard from the rigid contraction of the muscles, which were boldly mapped out on the surface. There was no abdominal pain or tenderness even on very firm pressure, and there was no odour in the breath or vomit.

The pulse was very rapid, weak, and small, and the skin was cold. He complained, too, of feeling cold in his extremities. Nutritive enemata with brandy were ordered every few hours.

Before death the thirst increased a great deal; and though the vomiting was no less frequent the quantity vomited was less. He died very quietly and from exhaustion about forty hours from the commencement of vomiting.

The *post-mortem* examination was made by Dr. Fowler, and the following notes are taken from his report:

The stomach was enormously dilated, though its anterior wall was flat. It had the following measurements:

Longest diameter,	transverse	.	7 inches.
„	„	oblique	. 12 „
„	„	vertical	. 4 „

It occupied almost the whole of the front of the abdomen, and reached to within three inches of the symphysis pubis.

The intestines were contracted behind the stomach, and only one or two coils of them and the liver were visible until the stomach was disturbed. The stomach contained 28 oz. of thick, grumous, greenish fluid; when laid open mucus and similar greenish stuff were seen adhering to the walls. The submucosa and mucous membrane of the cardiac extremity were stained and injected, as was also the mucous membrane of the greater curvature. Towards the pylorus the mucous membrane was mammillated. The coats of the stomach were thin; they shrunk considerably after being divided.

The small intestines were congested on the peritoneal surface, but not otherwise changed, and were nearly empty. The colon was collapsed. There was no obstruction.

The bladder was contracted, and contained little if any urine.

The kidneys were indurated and scarred on the surface; in the right there was a small cyst.

Both auricles of the heart were distended with black clot, and the right ventricle was occupied by soft fibrinous clot, which extended into the pulmonary artery. Valves and pericardium normal.

Both lungs were emphysematous, and in the upper lobe of each was an old cavity. Miliary granulations were sparsely scattered throughout the remainder of the right lung.

The cartilages of the ankle-joint were ulcerated, that of the tibia being almost entirely destroyed. The exposed surfaces of bones were rough, carious, covered with pus, and of a dark red tint. The synovial membrane of the ankle was soft, pulpy, and injected; that of the calcaneo-astragaloid and astragalo-scaphoid joints was also red and pulpy; and in the latter there was a line of ulceration commencing.

Dr. Goodhart kindly examined a section of the stomach for me, but no microscopic changes in its coats were detected.

Remarks.—Two causes for this fatal vomiting were considered; a third might under other circumstances have been entertained. The idea of poisoning might have arisen had the patient not been under hourly supervision in the hospital; as it was the thought was out of the question. Intestinal obstruction crossed the mind in this case as it has done in others similar to it, but no obstruction existed. Chloroform was supposed to be chargeable with the death, but without sufficient reason. The vomiting was quite unlike chloroform sickness, both in character and quantity; the man had inhaled a mixture of ether and chloroform a month previously without suffering any subsequent inconvenience, nor am I aware that in any case of death from chloroform the stomach has been found dilated, or that the mode of death has been other than through the heart or respiratory organs by the sedative effect of the chloroform on the nervous system.

The only other similar cases to which I am able to refer are—one contained in the 4th volume of the Path. Soc.'Transactions,' one related by Dr. Hughes Bennett, in his 'Principles and Practice of Medicine,' and two described by Dr. Hilton Fagge in a very suggestive paper in the 18th volume of the 'Guy's Hosp. Reports' (3rd series). Two other cases of a more chronic nature, but in many points much resembling the rest, are described by Andral in his 'Clinique Médicale' (Translation by Spillan, pp. 850, 852, Cases 5 and 7). In all these cases there was very profuse vomiting of liquid, mostly of a greenish, or greenish-yellow, or brownish colour; the stomach was greatly dilated, the skin dry, the urine scanty or suppressed, and the small intestines empty. In Andral's cases the symptoms were less severe but more prolonged, the patients living nine months and thirteen months, and were reduced to the last stage of marasmus before their death. In Dr. Humby's case death was delayed until the eleventh day; in Dr. Bennett's until the ninth. In each of Dr. Fagge's the symptoms were much more acute, death following the commencement of the symptoms in three days. In my own case death was still more rapid, and occurred in less than two days.

The question arises—what is the relation of the dilatation to the vomiting? The answer, as it seems to me, is that both are due to the enormous quantities of gastric fluid secreted, and that this is due to some error either of the nerve influences or of the

circulation of the stomach.[1] This over-secretion may proceed gradually or interruptedly, and thus slowly wear out the patient; or, secondly, it may be more rapid, so that several quarts may be evacuated in twenty-four hours, and after this the vomiting may cease, owing to the palsy of the coats of the stomach and of the abdominal muscles, and the patient will die with many quarts of the same kind of fluid accumulated in the dilated organ; or, thirdly, the secretion may be rapid and continuous, the vomiting unceasing from the first, and yet the patient dies with the stomach dilated, and with many ounces or even pints within it.

That the over-secretion of gastric fluid and not the dilatation is the origin of the evil is, I think, indicated by the clinical symptoms, viz. the absence of perspiration, the scanty urine, and the thirst, together with the large quantity of liquid vomited; and I would therefore suggest that some name which implies this feature would better designate such cases than "acute dilatation." Possibly "gastrorrhœa" might serve the purpose sufficiently well. It is conceivable that death may occur from the exhaustion of the gastrorrhœa and vomiting without dilatation being present after death.

Dr. Fagge, to whom I mentioned this view as to the probable cause of the vomiting and dilatation, has drawn my attention to the fact that Cohnheim has expressed a somewhat similar view of the pathology of cholera, viz. that the rice-water stools are due, not to an inflammatory origin, but to an over-secretion of fluid by the mucous membrane of the intestines, and that collapse is produced as well by excessive secretion as by the exaggerated exudation of inflammatory fluid.

It has been proved experimentally that such fluid may be profusely secreted by the intestines after paralysing the nerves of the bowel. "This secretion of the intestine was first discovered by Moreau, who isolated a loop of intestine by means of ligatures, and then divided all the nerves passing to it in their course along the mesentery. On examining the intestine after four hours the loop, which had previously been empty, was discovered to be filled with fluid.

"This fluid was investigated chemically by Professor Kühne, now of Heidelberg, who found it to be neither more nor less than very dilute intestinal juice, and almost identical in composition

[1] In one of Dr. Fagge's cases there was a retro-peritoneal abscess communicating with the duodenum, and very probably, therefore, irritating the ganglia of the sympathetic and the splanchnic nerves. See also one of the cases quoted by Dr. Goodhart in the succeeding communication.

with the rice-water fluid which is poured from the intestines so abundantly in cholera" (Kühne and Parkes).[1]

Dr. Pye Smith and Dr. Brunton, in their reports to the British Association on the "Nature of Intestinal Secretion" (1875-6), have further shown that the "paralytic" secretion of Moreau results from the removal of the small ganglia of the solar and superior mesenteric plexuses; that these ganglia are indeed the centres of the secretory nerves of the intestines; and that this secretion is unaffected by section of the splanchnics, the vagi, or the dorso-lumbar part of the cord.

It is to be regretted that no analysis was made of the vomited matter in this case, but from analogy with what is known respecting the excitation of the salivary and intestinal secretions, as well as for the clinical reasons above stated, it may, I think, be concluded that the secreting structures of the stomach were in some manner at fault. Whether the error was due in the first place to an abnormal stimulation of the mucous surface of the stomach, to paralysis of certain nerves passing to the stomach, or to direct stimulation of the secretory nerves, I cannot pretend to offer an opinion.

December 5th, 1882.

---

5. *Notes of the cases of dilated stomach, not due to pyloric obstruction, observed in the post-mortem room of Guy's Hospital from* 1875 *to* 1882.

By JAMES F. GOODHART, M.D.

1. A MAN, aged 40, died with stricture of the urethra, for which perineal section had been performed. The scrotum was in a sloughing condition.

The stomach is merely stated to have been "dilated."

2. A man, aged 22, operated upon for strangulated inguinal hernia, died with suppurative peritonitis.

The stomach was dilated to twice its natural size.

3. A woman, aged 48, suffered from a growth in the neck,

[1] Report of the Committee, consisting of Dr. Pye Smith and Dr. Brunton, appointed by the British Association, for the purpose of investigating the Nature of Intestinal Secretion. *Vide* 'Report of the British Association,' 1874, p. 55.

obliterating the vessels on the left side, the left vagus, and cervical sympathetic.

The stomach occupied the greater part of the abdominal cavity; it lay flat upon the coils of intestine, and contained about a pint only; the mucous membrane was healthy.

4. A woman, aged 49, died with ulceration of the colon, acute enteritis, and thrombosis of the superior mesenteric artery.

The stomach occupied most of the abdominal cavity, was quite flaccid, and almost empty.

5. A male, aged 17. Case of mitral and aortic disease; distension of the stomach by food; sudden death.

The stomach was very distended with a large meal of potato, casein, and orange. It seemed to be not improbable that the sudden death might have been due to over-distension, having paralysed the stomach and interfered with the already impaired function of the heart.

6. A female, aged 28, with granular kidneys and hypertrophied heart. The stomach was greatly enlarged, projecting low into the abdomen, the mucous membrane being very remarkably hardened and opaque and mammillated.

7. A woman, aged 24; amputation at the hip-joint was performed eleven days before death. There was suppuration in the joint and caseous glands in the lumbar region.

The stomach filled the greater part of the abdominal cavity; its walls were thin from over-distension by gas; it contained only ʒij of liquid food.

8. A women, aged 84, died nine days after ovariotomy.

The stomach symptoms were considerable. Two days after the operation flatulent distension of the abdomen is noted. Four days after she is very sick and weak. Six days after there was constant vomiting.

The stomach was extremely dilated; there was not much evidence of peritonitis.

9. A man, aged 29. His knee was excised on May 11th under chloroform. He vomited obstinately every few minutes after the operation, and died in about seventy-five hours exhausted.

The viscera were all healthy, save the stomach and lungs, which are thus described by Dr. Fagge:

"The stomach was dilated, reaching down to the umbilicus; its walls were thin; its mucous membrane had undergone solution to

some extent; it contained a large quantity of thin, gum-brown fluid, which I have seen in other cases of dilated stomach.

"The air-passages contained a quantity of the same fluid, which bubbled out of the finer tubes on pressure, and in the back part of the right lower lobe were large patches of lung tissue uniformly stained by this fluid, which must have been sucked in during life; these parts were also œdematous." In all these cases the condition was found at the autopsy without being suspected during life. The clinical history is, therefore, somewhat wanting. But the absence of mention of vomiting in most of the cases makes it nearly certain that it was not present to any marked degree in most of them.

Dilatation of the stomach appears to be found on the *post-mortem* table under conditions of some variety; but, referring to the foregoing cases, it would seem that most of them give some countenance to the idea that paralysis of the viscus is, if not the determining cause, at any rate an accompanying condition, and in this light they are of interest as bearing upon the question raised by Mr. Henry Morris in the preceding communication.

Nine cases are here recorded; two of them were peritoneal cases (suppurative peritonitis and death after ovariotomy), a third was a case of enteritis, a fourth one of growth in the neck obliterating the vagus and cervical sympathetic, and a fifth a case of caseous disease of the lumbar glands. Of the other four one appears to have been the paralysis of over-distension, another a case of renal disease, another a case of extravasation of urine with sloughing of the scrotum, and the last is one in many respects resembling that recorded by Mr. Morris. The man was operated upon for excision of the knee under chloroform. The vomiting afterwards was obstinate, and appeared to be the cause of death.

---

6. *Stomach exhibiting the condition known as phlegmonous gastritis.*

By A. Quarry Silcock, M.D.

[With Plate X, figs. 4 and 5.]

The stomach shown was taken from a patient, aged 54, on whom Mr. Herbert Page performed the operation of gastrostomy at St. Mary's Hospital, for œsophageal obstruction produced by an

epitheliomatous growth. The operation was completed in two stages; in the first an incision was made through the anterior abdominal walls parallel to and about one inch below the margin of the thorax on the left side with antiseptic precautions, and the peritoneal coat of the stomach stitched to the edges of the wound; in the second, the adhesions being firm, a small opening was made through the walls of the viscus five days afterwards. Subsequently the patient was fed by the stomach and gained flesh, all going well until the twenty-first day after the operation, when he was attacked by intense pain in the region of the stomach, accompanied by attempts to vomit, which were ineffectual by reason of the œsophageal stricture. He rapidly sank, and died thirty-six hours after the onset of the symptoms. No circumstance could be discovered which threw any light upon this unexpected and untoward occurrence.

Post-mortem.—The gastrostomy wound appeared to be perfectly healthy; the peritoneal coat of the stomach was secured to its margins by many carbolised silk sutures, and was in perfect coaptation therewith, the adhesions being firm and organised. The opening into the cavity of the stomach was about as large as a pea, and situated in the centre of the wound; the mucous membrane, extruding slightly beyond its margin, was yellow in colour, swollen, and softened, a few black streaks on its surface being probably altered blood pigment. On opening the abdomen about 20 oz. of liquid effusion was found, resembling "melted butter" in colour and consistency; no plastic deposits of lymph were observed except on the outer peritoneal coat of the spleen, but the intestines were greasy to the touch and injected. A large quantity of gelatinous lymph had been effused into the meshes of the subperitoneal tissues in the neighbourhood of the stomach, especially around the œsophagus, beneath the posterior layer of the small omentum, and around the upper end of the left kidney. The stomach was of an opaque yellowish-white colour, notably so on the posterior surface near the greater curvature, where this appearance was obviously due to an effusion of lymph beneath the peritoneal covering. When opened a quantity of black grumous fluid was inside it; the mucous membrane was swollen, of an opaque yellow colour, with here and there a few patches and streaks of injected vessels; its surface was smooth, the rugæ obliterated, but it was nowhere eroded or ulcerated. The walls of the viscus attained fully one

third of an inch in thickness in the neighbourhood of the fundus, the thickening gradually shading off towards the cardia and pylorus, where it ceased almost abruptly.

The coats of the first part of the duodenum were, however, thickened in some measure. The cut surface of the stomach everywhere exuded a thick, creamy, purulent fluid, which seemed to flow from the submucous and muscular coats; examined microscopically, it contained leucocytes, portions of muscular fibre-cells, a large amount of granular matter, and abundance of micrococci. The stitches had in no case been passed deeper than the muscular coat, and there was no trace of suppuration around them. The lymphatic glands along the greater and lesser curves were enlarged. With the exception of the adhesions immediately around the wound there were no others, recent or old, in connection with the viscus.

In the colon were well-formed scybala; the intestines, with the exception of changes due to commencing peritonitis, were normal.

In the œsophagus, 8½ inches below the level of the cricoid cartilage, was a hard growth, about the size of a chestnut, resembling on section to the naked eye a scirrhus cancer of the breast. It completely encircled the œsophageal tube, greatly constricting its lumen; the mucous membrane over it was eroded, and one or two lymphatic glands adjacent to it secondarily affected. The tumour when examined microscopically proved to be a squamous epithelioma.

The liver was enlarged and fatty, the kidneys in an early contracted granular condition; the spleen was slightly swollen and very soft; the endocardium was deeply stained, but, with the exception of chronic degenerative changes, the heart appeared to be unaffected. The lungs were congested, otherwise healthy. The liver and heart when examined microscopically showed changes due to "cloudy swelling."

Microscopical examination of stomach.—The mucous membrane was inflamed throughout, its epithelial cells swollen, granular, and blocking the gland tubes; the inflammatory changes were most marked towards its deeper surface, where they merged into those involving the submucous tissue. On its free surface the epithelium had in part become disintegrated, leaving only granular débris, leucocytes, and the more resistant interglandular connective tissue. The submucous tissue was infiltrated with inflammatory

products, rendering it almost diffluent, and it was evident that the great thickening of the walls of the viscus was to a great extent dependent upon its swollen condition, and that it was the source of the fluid which exuded from the cut surface of the coats at the time of the autopsy (see Plate X, figs. 4 and 5). The muscular and peritoneal coats were likewise inflamed and swollen. Micrococci were to be seen in the section in abundance, after staining with methylene blue. At the margin of the artificial opening the mucous membrane showed no decided evidence of digestion; it was in much the same condition as elsewhere, but not so markedly affected; the submucous coat in this situation was the seat of an intense inflammatory cellular infiltration, but not broken down and "pulpy" as in other districts further from the wound. (*Vide* Plate X, fig. 5).

The first portion of the duodenum was comparatively healthy; its submucous tissue, however, was somewhat swollen and infiltrated, giving rise to thickening of its walls near the pylorus; the gut below this was unaffected.

Remarks.—No other case of diffuse inflammation of the stomach has been recorded either in connection with the operation of gastrostomy or with gastric fistula; one such, however, by Waldmann, was ascribed to an injury in the region of the stomach, but the particulars of this case could not be obtained. The disease has usually arisen during some affection of the stomach, such as that produced by abuse of alcohol; or in the course of some malignant fever, such as typhus, variola, septicæmia, &c. Sometimes it has occurred independently of any cause which could be associated with it. In the present instance, it would seem probable that the disease was in some way connected with the operation; perhaps the most reasonable hypothesis would be to assume that some virulently septic products derived from the wound were absorbed at the margin of the artificial opening, where the submucous tissue was opened up as it were, and rapidly traversing the lymphatics of the part, gave rise to a spreading erysipelatous or phlegmonous inflammation involving the whole thickness of the stomach walls, and chiefly the submucous tissues.

I am indebted to Mr. S. G. Shattock for the little drawings which accompany this paper. *March* 20*th*, 1883.

7. *Cases of gastric ulcer associated with general degeneration of the arteries.*

By NORMAN MOORE, M.D.

1. AN ulcer of circular form, of the size of a sixpence, and situated on the lesser curvature two inches from the pylorus. In the base of the ulcer are three small adherent clots leading into a branch of the pancreatico-duodenalis artery, a copious hæmorrhage from which was the cause of death.

The floor of the ulcer was firmly adherent to the pancreas.

The patient was a man, aged 53 years, who was brought dead to St. Bartholomew's Hospital.

His left ventricle was hypertrophied, and his kidneys were small and granular. His lungs were emphysematous, and his arteries, except those of the circle of Willis, highly atheromatous. Many of his joints showed degeneration of cartilage.

2. An ulcer of oval form and one inch in diameter on the posterior wall of the stomach, two inches from the pylorus. Its edges were remarkably sharply cut; its base showed an opening into a branch of the pancreatico-duodenalis artery, and a hæmorrhage from this was the cause of death. The pancreas was adherent to the stomach at the region of the ulcer.

The weight of the heart was 17 oz., and there was great hypertrophy of the left ventricle. The kidneys were in an advanced condition of chronic interstitial nephritis.

All the arteries of the body were highly atheromatous. The posterior third of the left cerebral hemisphere was softened, and the cerebral arteries largely calcified. The aorta was atheromatous, and the gastric artery was almost completely calcified.

3. A commencing ulcer in the middle of the greater curve of the stomach of a woman aged 34 years, who died in St. Bartholomew's of interstitial nephritis associated with atheromatous arteries and abundant gouty deposits in joints and other parts. The middle part of the ulcer is covered by epithelium, and consists partly of blood and partly of necrosed mucous membrane. The ulcer is bounded by a distinct edge, and its base is in close relation to an adherent clot in an atheromatous gastric vessel.

These three cases are examples of a variety of gastric ulcer met with in persons with degenerate arteries, and sometimes, as in the third case, due to a thrombus. This variety, though rarer than that found in young people, is not very infrequent, as the following table shows.

Cases in which the Diagnosis of Ulcer of the Stomach was made in the Wards of St. Bartholomew's Hospital.

Year.	Total Number of Cases.	Under 30.	About 40.	Senile Cases.
1882	16	5	5	6
1881	13	8	2	3
1880	6	5	1	0
1879	9	4	3	2
1878	11	7	3	1
1877	12	5	5	2
1876	11	5	1	5
1875	5	2	1	2
1874	14	5	5	4
1873	10	5	2	3
1872	7	5	2	0
Total in 10 years	114	56	30	28

Thus, assuming the diagnosis to have been correct, there were 28 cases with degenerate vessels out of 114. But Case 3 shows that some of the cases in period 30—45 may belong to the same group, so that it is probably accurate to state that of cases of ulcer of the stomach about one quarter are associated with chronic degeneration of the gastric arteries. The few *post mortems* during a somewhat longer period (see Pathological Society's 'Transactions,' 1880) are perhaps insufficient to argue from, but they show that 10 out of the 12 cases recorded were in people with degenerate vessels, so great a preponderance as to lead to the belief that ulcer of the stomach associated with degenerate gastric arteries is the most fatal form of the affection. *May 15th*, 1883.

8. *A case of sulphuric acid poisoning with intense inflammation of the transverse colon.*

By W. Hale White, M.D.

Maria G—, aged 48, was admitted into Guy's on the 17th January, 1883. Thirteen hours before admission she swallowed a large quantity of sulphuric acid. The doctor who was called in gave her mustard as an emetic, but as she got worse he sent her to the hospital. On her arrival she was in such an extremely collapsed condition that she died within a hour of admission in spite of the plentiful application of stimulants.

The *post-mortem* examination was made twenty-eight hours after death. Rigor mortis was extreme. The mouth and pharynx were much excoriated and reddened; the epiglottis and aryteno-epiglottidean folds were intensely congested, and had on them a thin white slough not unlike a diphtheritic membrane; this could be peeled off easily. The œsophagus was very red and rough with an almost continuous white slough forming a complete lining for the inner surface. All along the greater curvature, and all over the lower three fourths of its interior, the stomach was soft and black, and could easily be washed away by a stream of water; the rest of the surface was very red. These changes ceased abruptly at the pylorus, but the inflammation affected all the coats of the stomach and was easily visible on the outside. At the middle of the greater curvature was a perforation, it was impossible to say from its appearance whether it was *ante* or *post mortem* as the walls of the stomach were so altered both by the acid, and the changes that had elapsed in the interval between death and the autopsy, but it seemed more probably *ante mortem* for otherwise it would be difficult to account for the slight peritonitis limited to the lower and most dependent part of the abdomen, which we conjectured had been set up by some of the contents of the stomach having escaped during life.

The small intestine was perfectly healthy except some slight injection of its peritoneal vessels where the peritonitis before alluded to was present. The large intestine was normal, except the transverse colon, which on its exterior was red and black like the internal surface of the stomach, whilst its interior was

intensely congested. The piece of great omentum between the stomach and transverse colon was much inflamed.

The greater part of the upper surface of the liver was a peculiar light whitish-yellow colour, this was quite superficial.

This is an extremely interesting case, for there is not, as far as I know, any other recorded in which there was such intense inflammation limited to the transverse colon. Two causes for this are possible: firstly, that some acid passed the pylorus and was transmitted so quickly through the small intestines that it did not affect them, but, for some reason or another, was retained in the transverse colon and there set up the enteritis (this hypothesis is on the face of it so highly improbable that it may be dismissed at once); secondly that the inflammation spread directly from the stomach to the transverse colon, and there can I think be no doubt that this is the correct explanation, especially if it be borne in mind that the stomach is during life in actual contact with the transverse colon, and connected to it by a piece of great omentum. This affection of the transverse colon may be taken as evidence of the great intensity of the inflammation set up by the sulphuric acid, for in the short space of thirteen or fourteen hours inflammatory changes had spread through the wall of both the stomach and transverse colon.

The case is also interesting in the relation it bears to the Eau de Cologne one mentioned in the 'Medico-Chirurgical Transactions,' for 1879, for in both a membrane closely allied to a true diphtheritic membrane, if not identical with it, was produced by an irritant, and as in this case there was no question of contagion from dirty tubes, it affords another proof of the possibility of the occurrence of a membranous laryngitis not due to diphtheria.

The last point to which I would direct attention is the peculiar colour of the surface of the liver. Was this due to the acid or to the mustard, which, together with the rest of the contents of the stomach, had been extravasated into the peritoneal cavity?

February 6th, 1883.

9. *Two cases of simple ulcer of the duodenum.*

By Norman Moore, M.D.

Cases of simple ulcer of the duodenum are so uncommon that it seems worth while to record two, which I have recently examined at St. Bartholomew's, and which with one other are the only examples of the affection recorded in the medical *post-mortem* books of the hospital (1867-1882).

1. A man, aged 34, came to St. Bartholomew's Hospital at 11 p.m. on May 9th, 1882. Until that evening he felt quite well, and at 10 p.m. had vomited about a pint of blood. He was admitted into one of Dr. Gee's wards. At 2.30 a.m. on the 10th he vomited a small quantity of blood, and at 6.30 the same morning lost a large quantity per rectum. He became collapsed, and died in an hour and a half.

Post-mortem.—All his organs were found much blanched, and the whole intestine was distended with blood; the œsophagus and stomach were normal. In the duodenum close to the pylorus there was an ulcer with clean-cut vertical sides, and about half an inch in diameter. Its base was adherent to the pancreas, and showed two small openings into branches of the pancreatico-duodenalis artery. The pancreas was otherwise normal.

The case is remarkable for the rapidity with which death followed the first attack of hæmatemesis.

2. A man, aged 49, who died in St. Bartholomew's of bronchitis. He was a bricklayer, and had had repeated attacks of bronchitis. For the three months before his death he had had slight attacks of indigestion, but without distinct or localised pain. His duodenal ulcer was not suspected during life.

He was very fat, and died with general anasarca.

Post mortem.—A deep ulcer with abrupt sides was found in the duodenum close to the pylorus. The base of the ulcer was adherent to the pancreas, and there was some puckering of the peritoneum near the adhesion, but no perforation. There was a small congenital diverticulum of the œsophagus, and in the stomach three minute ulcers were found near the pylorus.

The lungs were highly emphysematous, and there was great hypertrophy of the right ventricle.

The heart weighed 24 oz., and its muscular tissue was degenerate; the aorta and vessels at the base of the brain were highly atheromatous.

The kidneys were large (weight 17 oz.) and engorged, but showed no signs of permanent disease.

Ulcer of the duodenum is most frequent in young people, but this case illustrates the fact that, like simple ulcer of the stomach, it is also to be met with in connection with general degeneration of the tissues, and particularly of the blood-vessels.

October 17*th*, 1882.

---

10. *Lympho-sarcoma invading the duodenum.*

By Norman Moore, M.D.

From a woman, aged 41, who died in St. Bartholomew's Hospital under the care of Dr. Gee.

The lumbar glands were greatly enlarged, and the mesenteric glands to a less degree, by a soft growth, which microscopic examination showed to be a lympho-sarcoma. The duodenal wall was invaded by the growth and greatly thickened, and the mucous surface ulcerated. No other organs were infiltrated by the new growth.

During life an irregular ovoid tumour was felt in the epigastric region, reaching from the xiphoid cartilage to the umbilicus and outwards on either side for four inches. Distinct pulsation was felt uniformly over it. The greater part of it gave a muffled, almost dull sound on percussion; a lesser part was slightly resonant. The dull part was ascertained *post mortem* to correspond to the place where the duodenum was most thickened. Above the thickening, which had caused some obstruction, the duodenum was dilated, and this dilated part corresponded to the resonant area observed during life.

There was no intestine in front of the tumour.

The duration of the illness had been eight months. A pulsation in the abdomen was first noticed, then vomiting after food, and the abdominal tumour. *January* 2*nd*, 1883.

11. *Colloid cancer of stomach, lymph-glands, and lungs*

By P. H. Pye-Smith, M.D.

The patient from whom these remarkable specimens of gelatinous carcinoma were taken was a man of 58, who came under my care in Guy's Hospital in the summer of 1882. He had then a cough, and beside moderate emphysema showed no obvious organic disease; yet his appearance was so aged, pale, thin, and cachectic, that I expected evidence of some chronic affection to develop. This, however, did not occur, and he went out in a short time relieved.

He was readmitted, after some weeks, at the end of last September. There was then œdema of the left leg, and constant lumbar pain, but no hæmorrhage, jaundice, or ascites. The symptoms pointed to a retro-peritoneal glandular growth, pressing on the iliac vein. Subsequently (October 13th) a small lump appeared to the left of the umbilicus, and then a larger mass which I supposed to be the left lobe of the liver. The patient gradually wasted, and died on the 19th of November, 1882. There was scarcely any vomiting, and no hæmatemesis, throughout his illness.

Autopsy.—The body was much emaciated. The primary disease was found to be a large mass of colloid cancer, not, as usual, infiltrating the walls of the stomach or intestines and spreading through the folds of the peritoneum, but forming a circumscribed, fungoid tumour about 3 inches in diameter, which projected into the cavity of the stomach from its posterior wall. There was a large secondary mass of closely similar growth infiltrating the retro-peritoneal lymph glands and projecting forwards in the epigastric region, where it pushed up the liver. The left renal artery was so pressed upon that the corresponding kidney was excessively anæmic. There was no large tumour in the liver, only two or three small cancerous nodules. No gall-stones were present. The pancreas was stretched out over the tumour at the back of the abdomen, but was not involved in the disease. Perforation had taken place into the third portion of the duodenum. The small movable lump felt during life was found to be in the omentum. The spleen, kidneys, adrenals, tested, and bones were unaffected. There was, however, ulceration of the whole of the colon. The only other diseased organs were the

lungs, which were both filled with deposits of colloid material, mostly the size of peas or rather smaller. Except for some old adhesions, both lungs were free from inflammatory changes, and there was no sign of hæmorrhage, ulceration, gangrene, or other destructive process. At first sight they looked like lungs filled with miliary tubercles, but the nodules were not in clusters; they were much larger, softer, and more translucent.

The tumour of the stomach and the numberless secondary nodules of the lungs showed all the characters of colloid cancer. They were very anæmic and gelatinous, with a small amount of solid tissue, in which the colloid masses lay like boiled sago grains. There was no caseous degeneration and no hæmorrhage.

The retro-peritoneal glands, though also colloid, contained more opaque, white, "encephaloid" material.

On microscopical examination, beside the alveolar arrangement of true carcinoma, there were found, both in the primary tumour and in the lungs, abundant epithelium-like cells and others with many nuclei, as well as a multitude of very small nucleated cells like those which have been described as free nuclei.

The stomach and one of the lungs are preserved in the Museum of Guy's Hospital.

The peculiarities which seem to me to give these specimens pathological interest are, first, the unusual occurrence of colloid cancer as a fungous tumour on the mucous surface of the stomach; and, secondly, the rarity of colloid cancer of the lungs.

In the first volume of our 'Transactions' (p. 91) is narrated a case of "alveolar cancer of the stomach" in which a tumour situated in the small omentum ulcerated into the stomach. But, with this somewhat doubtful exception, I do not know any instance of a colloid tumour observed in this situation, and with this mode of origin and growth.

I have found thirty-four other cases of colloid cancer recorded in the 'Transactions' of this Society, almost all peritoneal and only one of them gastric.

This was a remarkable case published by Dr. Bristowe in our nineteenth volume (1868). The œsophagus, cardiac end of stomach, and lymph-glands were infiltrated with colloid cancer; and the lungs were also affected with the same disease, though in a very early stage, apparently conveyed directly by the lymphatic vessels. See Dr. Bristowe's account, *loc. cit.*, pp. 232, and that of the Morbid

Growths Committee, p. 236. The course of the disease in this case was quite in harmony with the subsequent observations of von Recklinghausen and Köster on its growth from lymphatic endothelium.

In the museum of Guy's Hospital all the specimens of colloid cancer are abdominal. One tumour described as "areolar" or colloid, a case of Dr. Bright's, affects the stomach; but although the growth has a somewhat gelatinous appearance, subsequent examination showed that it is not histologically colloid cancer. In the late Professor Bennett's treatise on 'Cancerous and Cancroid Growths,' published at Edinburgh in 1849, five cases of colloid cancer were described, and the microscopical characters, for the first time, I believe, in this country, accurately figured. Two were typical cases affecting the peritoneum, two were mammary, and one was a more doubtful tumour of the back.

All authorities—Rokitansky, Frerichs, Lebert, Wagner, Paget, Wilks, and Payne—agree in the rarity of true colloid cancer, except in the abdomen or the mammary gland.

The present case would of itself almost suffice to determine two important questions in the way in which they are now most generally answered. First, whether colloid disease is true carcinoma. This was proved in my case by the microscopical structure of the tumours, by their infection of lymph-glands and lungs, and by the progress and event of the disease. Secondly, whether colloid cancer is a distinct variety or a degeneration. The latter hypothesis is here contradicted by the uniformity of the growths, and particularly by the beautiful and most characteristic appearance of the disease in the lungs, where it was most recent, uniform, and free from any sign of decay. *November* 21*st*, 1882.

---

12. *Epithelioma of stomach with wide diffusion of secondary deposits in other viscera and throughout the integuments.*

By David W. Finlay, M.D.

[With Plate VIII and Plate IX, figs. 1 and 2.]

Benjamin C—, aged 38, a packer by occupation, was admitted into the Middlesex Hospital under the care of Dr. Cayley on September 24th, 1882.

DESCRIPTION OF PLATE VIII.

Illustrating Dr. Finlay's case of Epithelioma of the Stomach with Secondary Nodules in the Skin, &c. (Page 102.)

Back and front views showing the appearance and arrangement of the subcutaneous nodules in a case of epithelioma of the stomach.

From drawings by Dr. Finlay.

Fig. 2.

Fig. 1.

C M F del.

F Huth Lith^r Edin^r

There was nothing in his family history tending to throw light on his present illness.

As regards personal history, he stated that he had always enjoyed good health up to about four months before admission, with the exception of a severe attack of acute rheumatism four years previously, which had laid him up for nearly three months.

In May last he noticed that he passed blood with his motions, the hæmorrhage being always preceded by pain in the region of the umbilicus. This lasted for about three weeks.

Six weeks ago dull aching pains began to be complained of between the shoulders and over the front of the chest, and about the same time he noticed a small swelling to the right of the umbilicus; this swelling gradually increased in size, and became tender to touch, being soon followed by the appearance of numerous other similar tumours on various parts of the body. There was occasional recurrence of the hæmorrhage from the bowels, but none for six weeks before admission. He was habitually constipated, and had recently suffered from attacks of retching, but had never vomited blood.

On admission he was described as anæmic and emaciated. His chief complaint was pain in the back, and also in the lower sternal region, the latter pain being aggravated by the ingestion of food. The surface of the trunk was thickly studded with hard subcutaneous nodules of varying size, from that of a walnut downwards, more numerous on the front than on the back of the body. A few nodules were found also on the arms and legs, and the glands in the groins and axillæ were enlarged and hard. Most of the nodules appeared to be quite subcutaneous, the skin being adherent to many of them, but some of the larger were felt to be more deeply seated, and seemingly adherent to subjacent parts. Nothing abnormal could be detected in the thorax or abdomen, no evidence of any internal tumour being obtainable. The man's tongue was coated; his appetite good; temperature 99°; urine, sp. gr. 1016, acid and albuminous.

On October 1st two of the subcutaneous nodules were cut out, and on microscopic examination were found to consist in great part of alveoli, lined with cells resembling columnar epithelium.[1]

[1] It may be mentioned as a fact of clinical interest, that from the structure of the nodules excised during life, it was concluded that the primary growth was in the alimentary tract, although its exact locality could not be fixed.

As to the progress of the case, it will be sufficient to say that the pain in front became more localised in the region of the epigastrium; the temperature rarely exceeded 100°, being on the average about normal; the breath sounds and percussion resonance became impaired over the left side of the chest; the nodules increased in number and size; the patient became gradually more emaciated and exhausted, and died on October 29th. Towards the end he suffered much from the epigastric pain, and on one day, a week before his death, he vomited all his food as soon as it had been swallowed.

The following is an abstract of the record of the post-mortem examination, which was made by Dr. Fowler thirty-seven hours after death.

As regards external appearance, the body was emaciated, and there were numerous nodules, varying in size from a pea to a horse chestnut, situated in the subcutaneous tissue of the integuments, the largest being found just to the right of the umbilicus. These nodules were hard, the smaller freely movable beneath the skin and upon the deeper structures, the larger adherent to the skin, but movable with it. None had ulcerated, but scars marked the sites of two, which had been excised during life.

The arrangement of the nodules was somewhat symmetrical on the two sides, especially those on the posterior surface of the body; none were found lower than the popliteal spaces.

In the abdomen the mesenteric glands were enlarged and infiltrated with new growth. A nodule the size of a hazel-nut was found at the attachment of the mesentery to part of the ileum, and on opening the bowel a flattened and circular growth the size of a shilling was seen to have perforated the intestinal wall. The large intestine was free from new growth.

The under surface of the diaphragm was covered with flattened patches of similar growth.

In the stomach, at its point of junction with the œsophagus, an area of new growth commenced, and extended over the posterior wall, occupying an area of about $3\frac{1}{2} \times 3$ inches. Its margin was raised, soft, injected, and irregular in outline, the mucous membrane being destroyed over its surface, which was rough and of a pinkish colour. The growth had not perforated the peritoneal covering of the stomach, except over a small area, where it was continuous with a mass of infiltrated glands surrounding the cardia.

The retroperitoneal and bronchial glands were also infiltrated.

The liver presented a number of small secondary nodules, chiefly around the inferior vena cava.

The vessels and ureter of the left kidney were embedded in a mass of the growth, which had also involved the suprarenal capsule.

The kidneys were granular, the cortex being much wasted, and the calyces of the left slightly dilated.

The left suprarenal capsule was enlarged and soft; its central part completely converted into white and soft cancer growth, the cortical portion being thin, but normal in appearance.

The right suprarenal was normal.

The spleen was not infiltrated.

The muscular substance of the heart was pale; the valves normal.

The left pleura contained about half a pint of clear serous fluid. On the left lung the pleura was thickened and rough, and a few small secondary growths were apparent in the superficial portions of the lung. The walls of the bronchi were thickened and partly surrounded by cancerous growth, which had extended along them to the lung. Numerous secondary deposits were found in the lower lobe.

Similar extension had taken place along the bronchus to the right lung, in the lower lobe of which a small growth was found, surrounded by an area of consolidation.

The subcutaneous growths on section were hard and white, with red striæ radiating from their centres; their cut surfaces yielded a little milky juice on scraping.

Examined microscopically, the new growth is found to present, in all the different parts, the same essential appearances. It consists chiefly of oval, circular, or horseshoe-shaped alveoli lined with cylindrical epithelium, embedded in a stroma of coarse fibrous tissue.

The most typical columnar cells are to be seen in the section of the primary growth from the stomach, where there is also the least development of fibrous tissue.

The appearances in the nodule from the liver come next in order as to perfection of cell type; and in the subcutaneous growths, although the cells are not in the main so large or distinct, still the alveoli and their epithelial lining are quite characteristic. In the last-named situation, also, there is the most abundant development of fibrous stroma.

There can be very little doubt that the growth was primary in the stomach, and that being so, it seems most reasonable to look to

the blood as the agent in the dissemination of the cancerous infection to the remoter structures.

I should add that I am indebted to Dr. Cayley for permission to record the case. *March 20th*, 1883.

---

13. *Polypus of the stomach.*

By Norman Moore, M.D.

A soft spherical growth from the mucous membrane projecting at the end of the first third of the great curve. The polypus was from a man, aged 68 years, who died of bronchitis, and it had given rise to no symptoms during life. Some specimens of polypi of the small intestine have been shown to the Society this year, but polypi of the stomach are less frequent. There are three specimens of the kind in the Museum of St. Bartholomew's, but the infrequency of the growth is shown by the fact that the present specimen is only the second which has been observed in the last three thousand *post-mortem* examinations. *May 15th*, 1883.

---

14. *Intussusception caused by an intestinal polypus, and cured after sloughing of the strangulated bowel.*

By Anthony A. Bowlby.

This specimen was taken from a female infant, aged 18 months, who was admitted into St. Bartholomew's Hospital under Mr. Morrant Baker, to whom I am indebted for permission to publish the case.

The following is a brief sketch of the most important clinical features:—On April 28th the child was seized with severe pain in the abdomen and passed a motion. The following day she passed some blood, and, during the next week, two green motions with some slimy mucus. On May 7th the motions became black, and the child appeared to be dying.

On May 10th she was admitted into St. Bartholomew's Hospital, and some shreds of gangrenous bowel which protruded from the anus were removed by the exercise of very slight traction. During the three following days no blood was passed, but a good deal of

mucus, and on May 13th another small portion of gut came away. From this time the patient rapidly improved, and on May 19th was discharged; at this date the motions were fairly healthy. On June 1st a syphilitic rash made its appearance, the child refused its food, wasted, and died on July 2nd, its motions having been natural up till its death.

A *post-mortem* examination revealed the signs of old peritonitis, the coils of intestine being adherent to each other and to a mass of enlarged mesenteric glands. A further examination shows that the entire colon has been destroyed, and that the small intestine reaches to within three inches of the anus. At this point the peritoneum is scarred and puckered, and the calibre of the gut slightly narrowed. Five inches higher up the small intestine is a polypoid growth; it nearly entirely fills the intestinal canal, and the mucous membrane around is ulcerated. Microscopically it was found to consist of fibrous and glandular tissue.

The two portions of sloughy gut which were removed during life are respectively the cæcum with the vermiform appendix, and a part of the colon about two inches in length.

It seems probable that the presence of the polypus excited excessive vermicular motion of the intestine, which resulted in an intussusception, commencing at the ileo-cæcal valve, and subsequently destroying a part of the small intestine and the whole of the colon, the continuity of the canal being restored three inches above the anus. Thus, although a polypus may be the exciting cause of an intussusception, the latter does not invariably commence at that portion of the gut from which the polypus springs. The case is further interesting as affording another example of the possibility of a natural cure by sloughing of the strangulated bowel. *December 19th*, 1882.

---

15. *Very large connective-tissue polypus of rectum.*

By Anthony A. Bowlby.

The patient from whom this specimen was removed was a girl, aged 24, who had not been aware of anything the matter with the rectum, and who could give no history of any symptoms pointing to the presence of a tumour.

One day while straining at stool she felt something come down which she was unable to return. Soon afterwards she was seen by Mr. Everley Taylor, of Scarborough, who found a large red mass, about the size of a fœtal head, protruding from the anus, and tightly gripped by the sphincter. Under chloroform the present tumour was found attached to the anterior wall of the rectum four inches up; after transfixion and ligature of its base it was removed with scissors, its weight when fresh being two pounds all but one ounce. The tumour consists of very loose connective tissue, the meshes of which contain much viscid fluid; a good deal of the latter has drained away, and thus reduced greatly the bulk of the mass. The base of attachment is about one inch and a half in diameter, and the growth is covered by normal mucous membrane. The specimen is chiefly remarkable on account of its large size and the entire absence of any symptoms. *December 19th*, 1882.

---

16. *Diffuse polypoid growths of large intestine.*

By ANTHONY A. BOWLBY.

THE intestine here exhibited was taken from a man aged 64 years, in whom no other disease of the alimentary canal was found. The entire colon from the ileo-cæcal valve to the sigmoid flexure is the seat of small polypoid growths, from one third of an inch to half an inch in length, either sessile or pedunculated, covered by normal mucous membrane, and not bearing any particular relation to any part of the circumference of the gut. On microscopic examination they are seen to be composed of loose connective tissue.

Similar specimens exist in some of the museums of the London hospitals, but are mostly found in cases where the gut is also strictured. *December 19th*, 1882.

---

17. *A case of double obturator hernia.*

By ANTHONY A. BOWLBY.

THE patient from whom these specimens were taken was a very thin woman aged 69, who had been married and borne three children. Her general health was good, but she suffered from rheumatoid arthritis of the hip and prolapse of the uterus. Careful inquiry failed to elicit any history pointing to previous attacks of abdominal obstruction.

On June 10th, at noon, she was suddenly seized with severe pains in the abdomen and vomited; there was much prostration, and she was obliged to keep her bed.

Constipation, pain, and vomiting continued until her admission into St. Bartholomew's Hospital on June 14th.

The abdomen was distended, more so on the right side than the left, painful and tender, especially in the neighbourhood of the umbilicus. The descending colon could not be felt, and the rectum was empty. A vaginal examination revealed nothing.

The upper part of the right thigh was bulged slightly at the femoral ring, where there was a slight tendency to hernial protrusion. She complained of pain shooting down the thigh, but it appeared to be of a similar nature to that from which she frequently suffered on account of the rheumatic condition of the right hip.

The symptoms of obstruction continued, and she died on the 21st of June, being the eleventh day of her illness. A *post-mortem* examination showed the existence of a strangulated obturator hernia on the right side, and an empty sac in the same situation on the left.

The sac on the right side was about the size of a pigeon's egg; the peritoneum forming it was thickened, as was also the subperitoneal tissue; the protrusion had passed over the upper edge of the obturator externus muscle, some of the fibres of which were spread over the under surface of the sac; the pubes was in immediate contact with the upper part of the neck.

The obturator nerve was stretched over the sac, and slightly to its inner side lay the obturator artery, to which the internal circumflex sent a large branch along the lower and inner wall of the hernial protrusion. On laying open the sac along its anterior surface, it was found to contain a large knuckle of small intestine—

part of the ileum—which, though deeply congested, was not gangrenous, and was adherent in its whole circumference to the sac

WOODCUT 2.

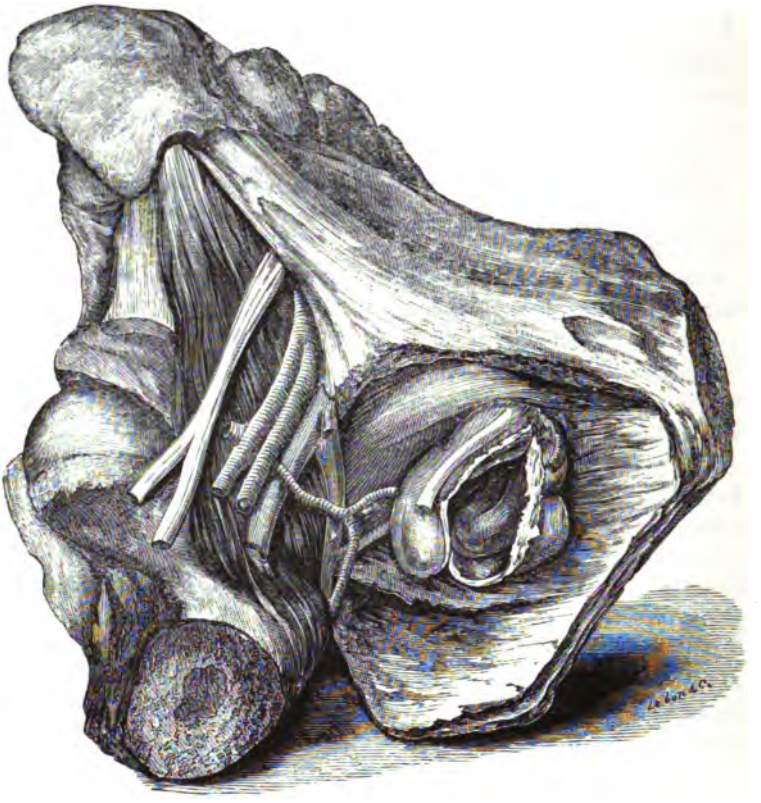

wall; the adhesions were slight, and apparently recent. There was no omentum and scarcely any fluid in the sac.

On the left, the empty sac was about the size of a walnut, and bore the same relation to the obturator externus muscle as did that of the opposite side. The obturator nerve lay over the front of the tumour, but the artery passed directly behind it, dividing into its two main trunks close to the neck of the sac, and, as on the other side, giving a large branch of communication to the internal circumflex.

Obturator herniæ appear to occur most commonly in thin, old women, and this patient was no exception to the rule. The specimens illustrate the variations which may occur in the distribution of the obturator artery relative to the sac, for on one side it was in front, on the other, behind. The former position would appear to be rare, for Vinson (quoted by Birkett in Holmes' 'System of Surgery'), out of fifteen cases, found that this vessel lay three times behind the sac, six times to its inner, and six to its outer side. In the specimen described by Stanley in a former volume of the 'Path. Soc. Trans.,' and which is in the Museum of St. Bartholomew's Hospital, the artery accompanies the nerve over the front of the sac; in another specimen in the same museum it lies on the upper and inner side.

WOODCUT 3.

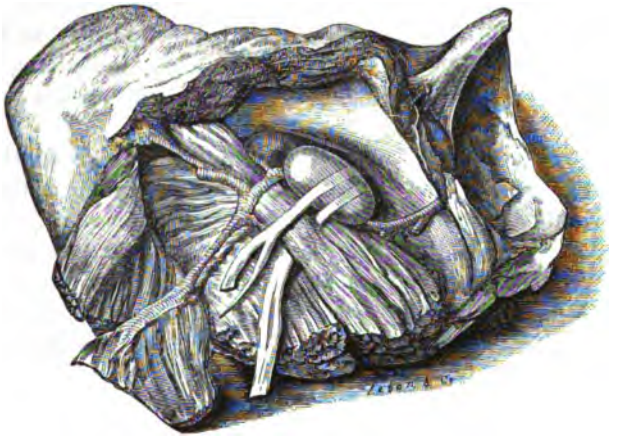

The tumours were both small, and the contained intestine on the right side was not drawn out into a diverticulum, as has been described in several specimens.

The presence of two obturator herniæ, as in this patient, has been noticed in other cases, and the tendency to hernial protrusion was further exemplified by the bulging at the crural ring.

In these patients, the strangulation does not as a rule appear to be very acute, for in the present case, at the end of eleven days, the gut was not gangrenous; and in another recorded by Arntz, the patient lived twenty-one days without the condition being

diagnosed; similar histories have been detailed by other authors, and I think this is only what might be expected considering the smoothness of the bone at the seat of constriction, and the absence of any very sharp-edged ligaments. The exact seat of the greatest stricture lies probably in the neck of the sac, for in the present case after division of all the surrounding muscles the gut still remains constricted. The chief obstacle to reduction in the earlier stages consists in the great depth at which the tumour lies, and the difficulty which results in applying taxis. It is probable that in many cases reduction could be effected after dividing the more superficial structures, by which means the hernia would be brought more within reach of manipulation.

Any division of muscle around the neck of the protrusion would necessarily be fraught with danger of wounding some of the large arterial branches, while the small amount of fluid, and the close adhesion of the gut to the sac wall, which occurred not only in the present case, but also in those recorded by Stanley and other authors, point to the necessity of extreme care in opening the sac to reach any stricture which may exist either in its walls or in the contained viscera.

With regard to diagnosis, it is interesting to note that the characteristic pain along the thigh, due to stretching of the obturator nerve, was present, but the statements of this patient concerning it were misleading, and it was attributed to the rheumatic condition of the hip. Vaginal examination which has been successfully used in order to clear up the diagnosis in other cases, was tried, but without success. *October 17th*, 1882.

---

18. *Stricture of intestine at the ileo-cæcal valve.*

By NORMAN MOORE, M.D.

THE patient was a man, aged 47, who died in St. Bartholomew's Hospital under the care of Dr. Andrew. He had an attack (his first) of obstruction of the bowels on October 18th. The bowels not having acted up to November 1st, on that day colotomy was performed by Mr. Howard Marsh. At the time there was no relief, but the next day a quantity of fæces came through the wound.

The patient died on Nov. 4th. The wound showed no unhealthy suppuration. The intestines above and below contained a considerable quantity of soft, fluid fæces, but were not greatly distended. The stomach was normal. The small intestine was dilated, œdematous, and reddened; 3½ inches above the valve it showed extensive irregular ulceration, which extended all round. Some of the ulcers seemed healing, and there were many puckerings where healing had been complete. The ridge of the ileo-cæcal valve was very low, and the orifice was so contracted as but just to admit a large probe. Below the valve for 3 inches there was a less degree of ulceration. The colotomy wound was 2 inches below the valve in the large intestine. No tubercle was discoverable. The mesenteric glands were normal; the lowest part of the ileum was slightly adherent to the abdominal wall.

Microscopic sections from several parts showed that there was no carcinoma or other new growth, but that the thickening and contraction were due to long continued inflammatory changes.

December 5th, 1882.

---

19. *Cases of ulceration of vermiform appendix in typhoid fever.*

By Norman Moore, M.D.

Cæcum and vermiform appendix from a girl, aged 12 years, who died of typhoid fever. Eight feet of the small intestine were ulcerated, the sloughs being attached in some and detached in others of the ulcers. The large intestine was free from ulcers, except in the vermiform appendix. The vermiform appendix was tumid in the middle, and on slitting it up a small ulcer was found. It contained no foreign body or impacted mass of fæces.

Another example of a similar ulcer in an adult has recently occurred in the *post mortem* room at St. Bartholomew's, and among the records are two cases in which a fatal result in typhoid fever was due to perforation of the vermiform appendix.

It has sometimes been thought that ulcers in this situation were previous to or independent of the fever, but the fact that in these four cases there was extensive general ulceration makes it probable that the ulceration of the vermiform appendix, occasionally found in typhoid fever, has the same relation to the fever that ulceration of other parts of the large intestine has. *November 7th*, 1882.

20. *Typhoid fever; ulceration of large intestine with perforation.*

By Samuel West, M.D.

Case 1.—Sarah L—, æt. 28. Ill fourteen days. Diarrhœa seven days. Temp. 103°—105° from Oct. 19th—28th; fell for five days; rose again on Nov. 3rd. Patient became delirious. For last ten days of life, motions three, copious, in twenty-four hours, offensive. Died in great abdominal pain.

On opening abdomen there was no general peritonitis or free fluid. In the pelvis, the intestines and organs were loosely adherent, and covered with purulent effusion, but there was no free fluid.

Beneath one of the adhesions were two small perforations about one line broad, on the anterior surface of the rectum about 9 inches from the anus.

The small intestine was healthy until about three feet from the valve, and here was found a cicatrised ulcer, with pigmented edge, which was not swollen. The mucous layer had disappeared, and the muscularis was exposed. About a dozen such ulcers occupying the site of Peyer's patches, the largest only about three quarters of an nch long, were found between this spot and the valve. Round the valve the mucous membrane was thickened and much pigmented.

The whole colon was slate-coloured from pigmentation, and was in an advanced condition of ulceration. In the upper part the ulcers were small with tumid edges, and exposed the muscular coat. In the middle of the ascending colon the ulceration became most extensive for about two feet, and the greater part of the mucous membrane here was completely destroyed.

These ulcers corresponded, like dysenteric ulcers, with the free edges of the sacculi. The muscular coat was here so brittle that it was difficult to remove the intestine without tearing. From this point the ulcers became less extensive, though very numerous. The ulcer which had perforated was only about one inch long and half an inch broad.

At the rectum for an inch and a half from the anus, the mucous membrane was completely ulcerated away, with the exception of

one or two narrow bands which reached the anus. There were here a few old piles.

The kidneys were large, and in an advanced condition of cystic degeneration. They weighed together 12½ oz.

The liver was speckled with small capsular thickenings of old date.

Heart and spleen natural.

The lungs were congested at both bases, and in the apex of the left was a small calcareous nodule.

CASE 2.—Clara B—, aged 17, was admitted into the Royal Free Hospital with a history of illness for only a few days. The symptoms were not at first very definite, but the diagnosis was made of typhoid fever. In all respects it appeared a mild case, except that from the day of admission the heart sounds were very weak, the first being almost inaudible. The patient had three relapses, each time becoming more feeble, and never rallied from the last. She slowly became weaker and finally died of exhaustion after rather more than four months' illness.

On opening the abdomen, a mass of dense adhesions was found in the right hypochondrium, matting together the colon, liver, gall bladder and kidney. Between the liver and diaphragm was found an abscess capable of holding about half a pint of pus, bulging up into the thorax, the diaphragm being here so thin that it tore on attempting to separate it, and pus escaped into the right pleura. The colon formed several coils which could not be unravelled around the adhesions.

In the descending portion of the colon were numerous old healed ulcers, clearly marked by the cicatrisation and by the deep pigmentation. These ulcers were most abundant in the cæcum and round the valve, and for two inches up the ileum the pigmentation was well marked; above this for three feet there were typical healed typhoid ulcers.

One of the ulcers in the colon in the midst of the adhesions was still slightly ulcerated, and from it a perforation was found leading into a small abscess cavity about the size of a hazel nut. This had probably started the suppuration, which had then extended over the liver.

The lungs were congested, and the heart pale, but no noticeable change was found in the other organs.

Cases of perforation of the colon in typhoid fever are among the pathological rarities of this disease.

Murchison (Fevers), out of 39 cases of death from perforation, found the perforation in 4 cases only in the colon (1 in the cæcum, 1 in the sigmoid flexure, 1 at the junction of the ascending and tranverse colon, and 1 in the cæcum with a second in the sigmoid flexure). One other case he mentions in which the perforation was in the vermiform appendix. Morin, out of 64 cases found perforation of the large intestine in 14 (some of these, however, Murchison thinks may not have been true cases of typhoid fever). Of these 14, 2 were in the cæcum, 7 in the ascending colon, 1 in the transverse colon, and 4 in the sigmoid flexure. *October 18th*, 1882.

---

21. *Ulceration of large and small intestines in enteric fever.*

By J. Curnow, M.D.

Thomas Lawson, aged 26, an engine greaser, was admitted under Dr. Curnow at the Seamen's Hospital on December 11th, 1882. He was a Norwegian, and was on his return voyage from Alexandria in one of the troopships. The drinking water was taken on board at Alexandria, and there were other cases of fever on board the same ship. He had never suffered from ague, dysentery, or other severe illness. Eight days before admission he was suddenly taken with rigors, vomiting, headache, and abdominal pains, and was compelled to give up work. On admission he presented the usual symptoms of enteric fever, with well-marked rose-spots, tumid abdomen and slight diarrhœa, and the fever ran a normal course. Several fresh rose-spots came out during the attack, and it was noticed that his stools although typhoid in character were peculiarly offensive. The area of splenic dulness was enlarged. The temperature range was from 102°—103° F., until the 15th day of the disease, and on the 18th it became normal. He then appeared to be quite convalescent for four or five days, and was so well that he even read a novel. On the 23rd day the temperature rose, and he complained of great pain and tenderness in the left thigh and calf. The temperature remained very high (103°—104°),

the pain in the thigh continued and was accompanied by slight œdema; the pulse quickened, and he had occasional attacks of vomiting, and died on the 31st day of the disease. The bowels never acted more than three times in twenty-four hours, and there was no reappearance of rose-spots during the relapse. There was no hæmorrhage from the bowel, and no symptom of peritonitis or pneumonia. The case seemed to be a very usual one, viz. enteric fever, followed by a relapse and thrombosis of the external iliac and femoral veins. But on making a *post mortem* examination the intestines presented some unusual features for a case of enteric fever, as will readily be seen on their examination.

The upper part of the jejunum was thin and very transparent in some parts, whilst the mucous membrane was opaque, swollen, and injected in others. About its centre some oval patches were very distinct and swollen, and in one or two places ulcerated. In the lower part of the jejunum scattered ulcers occurred, whilst in the ileum they became much more numerous and rapidly increased in number towards the ileo-cæcal valve. Many of them were longitudinal and occupied the sites of Peyer's patches, whilst others were round and irregular in form. Just above the valve they were so numerous and close set that the whole of the internal aspect of the bowel seemed to be involved in the swelling and ulceration. The ulcers were well defined with a swollen margin and a yellowish sloughy-looking base, and in many of them a caseous mass can be seen distinctly rising above the level of the ulcerated margin. The cæcal appendix was much swollen and its lining ulcerated, whilst its apex was adherent to the ascending colon. The large intestine was covered with small rounded ulcers, in many of which a small central opening showing a cheesy interior can be seen; whilst others were deeply excavated, with sloughing and pigmented bases extending downwards in many cases to the serous coat. The whole of the mucous and submucous tissue is much swollen throughout the large bowel. The ulcers were remarkably numerous and close-set, and extend from the valve to the very lowest piece of the rectum; they were most numerous and best marked in the cæcum and the commencement of the ascending colon, in the transverse colon, sigmoid flexure and rectum. The mesenteric and meso-colic glands were enlarged, especially near the cæcum. The stomach and œsophagus and larynx were quite normal. The heart was somewhat large, but otherwise healthy, and the lungs merely

showed some emphysema. The liver was pale and rather fatty. The kidneys were healthy. The spleen was enormously enlarged, it weighed nearly 30 ozs.; and was very soft on section. The external iliac vein was filled with a black adherent clot, spreading downwards into the femoral vein and its branches.

I would only call the attention of members of the Society to some special points: viz. (1) the enormous number of the ulcers and the great extent to which the large bowel is involved, for although ulceration of this portion of the intestine is not uncommon, it is very so to find it extending quite to the anus, and attacking the large intestine even more than the small; (2) the ulcers in the transverse colon more particularly seem to be older than those in the small intestine, for they are more deeply pigmented and the sloughs are much deeper; (3) the absence of any marked diarrhœa; and (4) the fact of convalescence (clinically), in spite of the great amount of the ulceration. *May 15th*, 1883.

---

22. *Case of syphilitic perihepatitis.*

By Seymour J. Sharkey, M.B.

[With Plate VII, fig. 2.]

W. S—, aged 55, horsekeeper, was admitted into St. Thomas's Hospital under the care of the late Dr. Murchison on September 13th, 1876.

His father and mother were dead, but he could give no account of their ages or of the cause of their death. He had several brothers and sisters alive and in good health, and he did not know that any disease prevailed in his family.

Until three months before admission the patient had always enjoyed good health, with the exception of an attack of smallpox and a winter cough, with which he had been troubled for years. He stated that he had also had gonorrhœa, but that he had never had syphilis.

He had been in the habit of drinking considerable quantities of whiskey and other alcoholic liquors, but had become a teetotaller for the last month.

DESCRIPTION OF PLATE VII.

FIG. 1.—To illustrate Dr. Sharkey's case of Syphilitic Arteritis. (Page 10.) From a drawing by Mr. C. Stewart.

Section through middle cerebral artery.

a. Internal elastic lamina.
b. Muscular coat but little altered.
c. Small cell infiltration of external coat.
d. dilated vasa vasorum. (× 75 diams.)

FIG. 2.—To illustrate Dr. Sharkey's case of Syphilitic Perihepatitis. (Page 118.) From a drawing by Mr. C. Stewart.

a. Portion of a small gumma.
a'. Young cells at its periphery.
b. Fibro-cellular new growth.
c. Isolated liver cells. (× 333 diams.)

FIG. 3.—To illustrate Dr. Cayley's case of Acute Yellow Atrophy of the Liver. (Page 127.) From a drawing by Dr. Finlay.

Section of the liver. (× 420 diams.)

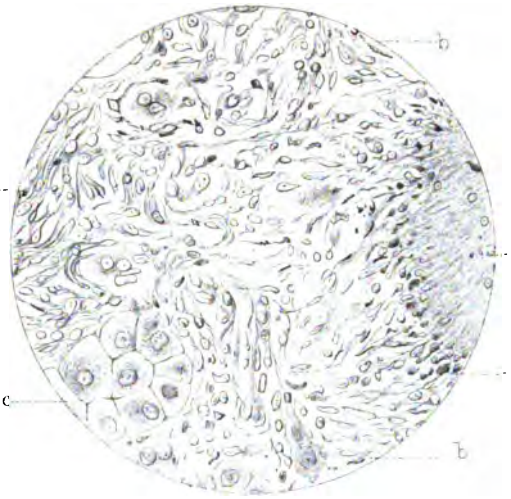

Fig. 2

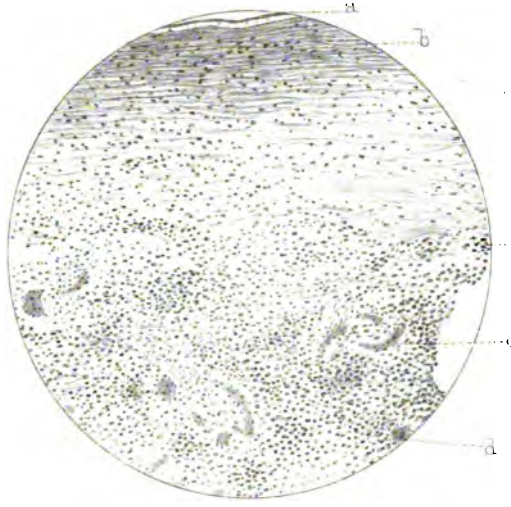

Fig. 1.



Fig 3.

For the three months previous to admission he had had constant diarrhœa, but had not stopped his work. He had been losing flesh for six weeks, and had noticed a swelling in his abdomen for one month.

On admission he was a stout, ruddy man, free from pain, jaundice, or vomiting, but suffering from diarrhœa. The bowels acted three or four times in the twenty-four hours. There was slight emphysema of the lungs; the heart appeared to be healthy. Urine sp. gr. 1020, contained no albumen. The temperature was normal.

On examination of the abdomen the liver was found to extend as far as the umbilicus, and to have a pretty hard edge. The surface in general appeared to be fairly smooth, but between the ensiform cartilage and the umbilicus was a large mass, indefinitely nodulated. Though this lump appeared to be as large as an orange, it probably was not so, as the abdominal wall was very fat, and produced a false idea of the size of a mass below it. The tumour was hard, elastic, and gave no sense of fluctuation; it moved with respiration, and appeared to pass insensibly into the liver substance. The patient had no pain, and allowed free manipulation of the tumour. There was no ascites, and little if any enlargement of the spleen.

Opinions were divided as to the nature of this mass, some thinking it to be a deeply-seated cyst, while Dr. Murchison pronounced it to be a rare form of cirrhosis, affecting mainly the left lobe of the liver.

The patient scarcely felt ill or inconvenienced by the disease, and soon left the hospital. Two years later, on October 3rd, 1878, he was readmitted under Dr. Bristowe.

He stated that, after leaving the hospital in 1876, he remained well and able to work until a few days ago, when he felt sick, and vomited a large basinful of blood. He vomited about six times subsequently, and the vomit each time contained blood. He also passed several motions containing black blood.

On admission he was still a very stout man. The abdomen was considerably distended, measuring forty-three inches in circumference. The superficial veins of the thorax, as well as those of the abdomen, were distended. There was dulness in both flanks, altering with position, and evidently due to fluid.

The conjunctivæ were slightly jaundiced. The upper border of hepatic dulness was on a level with the sixth rib. In a line with the

left nipple the lower border of the liver descended to within an inch of the umbilicus, and felt uneven and hard.

There was no evidence of disease of heart or lungs.

Urine had sp. gr. 1020, and contained no albumen, but a trace of bile.

Pulse 128, temp. 98·6°.

There were a few small non-striated hæmorrhages on the retina.

The patient increased gradually in girth, and had some pain and swelling in the legs, but otherwise did not change much until the 14th of October, when he had a return of the hæmatemesis and melæna, and died on the 16th, a fortnight after his admission.

On *post-mortem* examination the lungs were found to be emphysematous, and the right side of the heart somewhat hypertrophied. There was atheroma of the aorta and of the mitral valve.

The kidneys were pale and somewhat wasted, the spleen large and firm. The stomach and intestines contained a quantity of dark blood. The abdominal cavity was moderately distended with clear fluid.

The liver was large and very heavy, weighing 6 lbs. 7 oz. The surface was very coarsely nodulated, some of the nodules being as large as walnuts. The whole contour of the organ was greatly distorted and studded with the most irregular elevations. On making a section it seemed as if the disease was mainly confined to the peripheral portions of the organ, and the deeper parts appeared fairly normal. From the capsule inwards, for a distance of an inch or more, there appeared to be a growth of hard, fibrous material, which quite obscured the normal anatomical details of that region. These changes were distributed over the whole surface of the liver, and passed into the fissures and around the vessels on the under surface of the organ.

Microscopic examination revealed a process which was most intense, and likewise most advanced in the neighbourhood of the capsule, and which diminished, or was in an earlier stage of development, an inch or an inch and a half from the surface. The pathological changes consisted in a fibrocellular infiltration, in which were embedded small gummata. This fibrocellular new growth could be seen proceeding from the lower layer of the capsule, and at the deepest point at which it was detected it followed the lines of Glisson's capsule between the lobules. It ceased alto-

gether at a point an inch or an inch and a half distant from the surface. Where the process was in its early stage it consisted of a round-celled infiltration, which gradually became more and more finely fibrillated, the fibrillæ crossing in all directions, so as to form a feltwork. The latter broke up the hepatic lobules, so that they could no longer be distinguished, and separated the liver-cells in groups, the individual members of which were remarkably little altered. The new tissue was richly supplied with vessels, and some of the pre-existing ones appeared to have undergone amyloid degeneration. Here and there in this new growth were small gummata with their centres caseating, and the cells at their periphery elongating and sending out their extremities to join the fibres of the feltwork around. In some parts the bile-ducts appeared to be increased in number, in some they did not. Even in its most advanced stage the new growth seemed to be different from that constituting alcoholic or other forms of cirrhosis of the liver, for the fibrous tissue in the latter is developed in longer, coarser strands, is less nuclear, and does not exhibit the reticular appearance presented in this specimen. In any case, the very characteristic microscopic gummata, which occurred here and there in the new growth, pointed clearly to its syphilitic origin.

The alterations in connection with the liver which syphilis is said to produce are:

(1) Gummata.

(2) Interstitial hepatitis and perihepatitis.

(3) Amyloid disease.

The gummata are in the vast majority of cases localised masses on or near the surface and developed in relation with the capsule.

Interstitial hepatitis and perihepatitis are also considered to be results of syphilis. Still it is thought that apart from the history such cases could not be pronounced of syphilitic origin. In other words, the anatomical characters of the disease are said to be the same as those of alcoholic cirrhosis. In Wilks and Moxon's 'Pathological Anatomy,' the matter is stated thus:—"Some authorities set down as the result of syphilis a universal induration, such as we have described to you under cirrhosis, and they also admit a syphilitic form of capsular inflammation or perihepatitis. But if so caused, such changes could not be known from those due to spirit drinking, &c., whilst the latter cause would probably often coexist with the occasion of syphilis."

The present case is of interest because the patient gave a most decided history of drink, but none of syphilis; and yet the pathological characters of the disease admit of no doubt as to its being due to syphilis and not to alcohol. As an instance of syphilitic disease of liver its peculiarity consists, not in the development of gummata in connection with the capsule (this being their usual position), but in the diffusion of the process over the whole surface and to such a depth as to make the case a somewhat rare pathological specimen. *January 16th*, 1883.

Report on Dr. Sharkey's specimen of syphilitic inflammation of the capsule of the liver.—We have carefully examined some sections for the microscope furnished us by Dr. Sharkey of the liver observed by him. We understand that the original specimen was not preserved.

In the sections shown there appears to us to be clear evidence of syphilitic disease in the form of small gummata. The masses of small-celled growth, amorphous and caseating in the centres, surrounded by a belt of highly vascular fibrous tissue, appear to us to be unmistakeable.

With reference to the naked eye appearances, described by Dr. Sharkey in his report of "hard fibrous material" passing inwards from the capsule "for a distance of an inch or more, and obscuring the normal anatomical details of that region," we are unable to say without having seen the specimen, whether those changes were to be regarded as evidence of syphilis or not.

S. COUPLAND.
March 20th, 1883. J. F. PAYNE.

---

23. *Acute atrophy of the liver.*

By JOHN CAVAFY, M.D.

THE specimens shown are the liver, and microscopic sections of liver, kidney, and lung, from the following case.

William N—, aged 28, was admitted into St. George's Hospital, under my care on November 23rd, 1882. No accurate history was

obtainable; it was stated that he came up from the country three days before admission, and was then slightly out of health; he made no very definite complaint, however, had a good appetite, and was well enough to be up and walk about for two days. On the day before admission he rapidly grew very ill, vomited profusely a dark brownish matter without fæcal odour, became jaundiced, and at six o'clock in the evening unconscious, without antecedent delirium or convulsions.

On admission.—I saw him next day soon after one o'clock, and found him to be a well-built muscular man, brightly jaundiced and completely unconscious; the conjunctival reflex was very slow and slight, and both pupils were equally dilated and fixed. He lay on his back making constant slow masticatory movements; the limbs were semiflexed and rather stiff, especially the lower extremities. The heart's action was very weak, but the sounds normal; the respiratory sounds in front were also normal. The abdomen was only slightly distended, and the liver-dulness much diminished, extending in the right nipple line from the fifth intercostal space downwards for about one and a half inches only. The hypogastric region was dull on percussion, and distended; a catheter was therefore introduced and a pint and a half of urine drawn off of a dark brown colour; it contained a small quantity of albumen, gave the reactions of bile pigment, and yielded plenty of leucin and tyrosin on concentration. Respirations 24, pulse very weak, 110, and temperature 98°. He remained without change till his death at 4 a.m. on Nov. 24th.

Post-mortem examination, thirty-four hours after death.—Body well nourished; skin strongly jaundiced; cadaveric staining and rigor mortis well marked. *Head.*—On removal of the skull cap the dura mater was distinctly icteric, especially over the frontal, right parietal, and occipital regions; Pacchionian bodies well defined; pia mater congested. On slicing off the cerebral hemispheres to the level of the corpus callosum the puncta vasculosa were strongly marked, and the grey matter redder than usual; the texture of the brain was firm; a little yellowish fluid in the ventricles. *Thorax.*—A very small quantity of fluid in pleuræ; no adhesions; both pleural surfaces were studded with ecchymotic spots and blotches; the mucous membrane of the trachea and bronchi was blood stained; lung tissue spongy and crepitant, but occupied by irregularly distributed small and large dark red

hæmorrhages, especially at the bases and posterior borders. The pericardium contained a little straw-coloured fluid; the heart weighed 10 oz., and was contracted; valves normal; the muscle of the left ventricle was normal in colour for the outer half of its thickness; but the inner half, both auricles, and right ventricle were of a striking yellow colour; the muscular substance was tolerably firm; the whole endocardium, and the inner surface of the pulmonary artery were strongly icteric, while the lining membrane of the aorta was much blood stained; beneath the endocardium of the left ventricle there were numerous small ecchymoses, especially marked in the ventricular septum. *Abdomen.*—On opening the abdomen only a minute piece of the liver was visible just below the ensiform notch, the stomach and intestines being much distended; the surface of the great omentum presented numerous hæmorrhagic spots and was of a bright icteric tint; the whole of the lesser omentum, especially the gastro-splenic fold, was very richly studded with small hæmorrhages, which were also present but not so plentiful in the serous coats of the viscera. The stomach was distended and its serous coat yellow; its mucous membrane was pale, and the contents a small quantity of brown fluid like altered blood. There was slight submucous hæmorrhage in the first part of the duodenum, and a large amount of blackish altered blood was contained in the small intestine, of which the mucous membrane was icteric; the large intestine was empty, and only slightly stained. The pancreas was icteric, but otherwise normal to the naked eye. The spleen weighed 9 oz., was soft and of a uniform dull purplish-red on section. The liver was much atrophied, weighing only 36 oz.; it was very flabby, but at the same time moderately tough; the atrophy more especially affected the left lobe which was very thin with leaf-like edges, the capsule over it being much wrinkled. No trace of lobular marking could be seen through the capsule, the whole organ appearing of a nearly uniform dull red tint with some diffused slate-coloured patches over the right lobe. On section, the liver substance showed no lobular marking, and was of a dull brownish-red colour with darker purple patches; here and there portions were slightly mottled with a brownish-orange tint, but no other trace could be found of the bright rhubarb yellow material which is usually considered to form the first stage of acute atrophy, either diffused or circumscribed, and the whole surface was smooth without

nodular projections. The gall bladder contained a viscid, treacly, greenish-brown fluid. The kidneys weighed together 17 oz., and in both the cortex was much swollen; the capsule stripped off easily. The left kidney was enlarged with dilated and cystic pelvis and calyces; the pelvis and one of the calyces were occupied by small black calculi. The bladder was normal and contained about a pint of dark brownish yellow urine.

Chemical examination.—I am much indebted to Mr. F. J. Allen for carefully examining the urine, and to Mr. G. A. Buckmaster (now Radcliffe Travelling Fellow) for analysing the fluid from the ventricles of the brain, the pericardial fluid, and the contents of the gall-bladder. Their results are as follows:—The urine contained a mere trace of urea, a considerable quantity of urates, much tyrosin, a moderate amount of leucin, bile pigment, and a very doubtful trace of bile acids. There was also present a substance crystallising in colourless prisms and tablets, which was probably creatinin, but was unfortunately lost before it could be fully investigated. The fluid from the ventricles yielded abundance of chlorides and a small amount of leucin. The pericardial fluid yielded leucin in considerable quantity, and also tyrosin. The contents of the gall-bladder furnished no leucin nor tyrosin, but contained much bilirubin and a trace of cholesterin. Salts of the bile acids were carefully searched for on two occasions by adding excess of ether to an alcoholic extract, but no resinous or crystalline deposit was formed after very long standing; it seems, therefore, that they were absent.

Microscopical examination.—Portions of liver, kidney, heart, and lung were preserved in Müller's fluid and spirit, and from these sections were prepared by Mr. Alfred Lingard, and examined by Dr. Klein, to both of whom I beg to return my best thanks for their kindness. The liver tissue shows very advanced atrophy, and has no trace of any lobular arrangement; the cells are represented either by brown or brownish yellow strongly granular non-nucleated masses of irregular size and shape, which remain unstained by reagents or nearly so, or as smaller, shrunken, irregularly polygonal, and rounded remains of liver-cells, which absorb colouring matters more readily; they are either indefinitely scattered in an obscurely fibrillar matrix, or sometimes, in the case of the smaller ones especially, aggregated into larger or smaller irregular groups. Throughout the tissue there are to be found strongly-coloured,

bright, brownish-yellow granules and scales, with much colourless detritus. There is certainly no increase of fibrous tissue to be made out; the portal canals are about normal in this respect, and the indistinctly fibrillar matrix appears to consist entirely of the shrunken and collapsed remains of capillaries, of which the nuclei can no longer be distinguished, and of which the lumen is mostly obliterated by collapse and atrophy of their walls; in some places this shrinking has gone on to an extreme degree, and has given rise to a very irregular meshwork, containing only scattered granules and detritus, with isolated atrophied cells. No bile-ducts can be made out with certainty, except in the portal canals, where their epithelium is blurred and indistinct. A few lymphoid cells or leucocytes are to be seen here and there, but they are irregularly placed, and too scanty to be accepted as evidence of inflammatory change; the whole tissue, as is to be expected from the extensive destruction of the capillaries, is bloodless. A careful search has been made for bacteria, but with an absolutely negative result. The kidney shows cloudy swelling and early fatty degeneration of the epithelium of the convoluted tubes of the cortex, of which the majority are blocked; no nuclei can be distinguished; the same fatty change is to be found in the straight tubes of the cones, but not to the same degree, as the nuclei of the epithelium are evident in some of these; every here and there bright brownish-yellow granules are to be seen, but no bacteria. The heart is in a state of commencing fatty and granular degeneration, but many—perhaps the majority—of the fibres are quite normal, with well-marked transverse striation; again there are no bacteria.

Sections of the lung show hæmorrhage into the air-cells, of which many are filled with blood, the corpuscles being well preserved; a few air-cells contain granular matter and mucous corpuscles, with threads of fibrin, but this is by no means commonly the case. In sections of the lung stained with Spiller's purple there are numerous bacteria to be seen, and these are of three kinds:

1. Long bacilli, more than the length of the diameter of a coloured corpuscle.

2. Short bacilli, of the length of the diameter of a coloured corpuscle or less.

3. Micrococci, isolated or in dumb-bells.

All these forms occur in the blood contained in the alveoli in small numbers, and are more numerous in the air-cells which con-

tain catarrhal products; but they are most plentiful, especially the long bacilli, in the wall of a small blood-vessel, which occurs in one of the sections. It is not probable that these micro-organisms have any pathological significance; the bacteria, or rather micrococci, which have been said to occur by several observers in acute atrophy of the liver have been described as being found in the liver itself, and therefore in distinct relation to the diseased tissue; but in the present instance no trace of them can be found, except in the lung, and it is, therefore, more than probable that they are simply putrefactive, especially if we bear in mind the long time (thirty-four hours) which elapsed before the body was examined. Their absence from the other organs examined, notwithstanding probable early putrefactive change, may perhaps be accounted for by the fact of the lungs containing air, and being in this way more immediately accessible to floating germs.

The present case is remarkable for the very short duration of acute symptoms, death occurring in less than three days from their onset; and also for the absence from the liver of the bright yellow material, which one would expect to find in so rapid a case, the whole organ being practically in the stage of red atrophy.

May 15th, 1883.

---

24. *Cirrhosis and acute atrophy of liver.*

By W. CAYLEY, M.D.

[With Plates VI and VII, fig. 3.]

THE patient was a tailor, aged 30, who died in the Middlesex Hospital on March 17th, 1883.

He appears to have been of dissipated habits, and a free drinker of spirits. He had twice had gonorrhœa, the last time ten months ago, but stated that he had never had syphilis, and that his general health had always been very good. His mother and a sister had died of consumption.

About the middle of January he began to suffer from symptoms of dyspepsia, and his fellow workmen noticed that his face was a little yellow. He had pain and a sensation of weight after food in

the epigastric region, but no vomiting. On January 24th the pain became more severe and passed through to the back, and he now suffered from general malaise and the jaundice became more marked. Three days before admission the belly began to swell. His bowels during this time were freely open, and the motions were pale.

On admission the patient was observed to be of good muscular development and well nourished. He was decidedly but not very deeply jaundiced. The abdomen was distended, measuring thirty-five inches in circumference. It was resonant in the front, dull in the flanks. The dulness shifted with position, but no fluctuation was perceptible. The area of liver dulness was much diminished. The upper border was situated an inch below the nipple, and it only extended downwards for an inch and a half in the mammary line. Between the lower border and the costal margin the resonance was tympanitic. Heart and breath sounds were normal, but the cardiac impulse was very feeble. There was some œdema of the ankles, and numerous petechiæ on the lower extremities. His general condition was one of much depression; pulse 80, very weak and compressible. Tongue coated. He complained of epigastric pain and nausea. The first evening the temperature was 99°, but afterwards it remained persistently below normal, varying from 96·6° to 98·2°. The motions were paler than usual, but not devoid of bile.

The urine was jaundiced but free from albumen, and after evaporation was found free from leucine or tyrosine.

He gradually became more prostrate, was delirious at night, vomited his food, and on March 16th some blood. Numerous petechiæ appeared on the belly. On March 13th, the amount of urea was estimated and was found to be very deficient, the urine containing only $\frac{1}{10}$ per cent instead of 2 per cent. No leucine or tyrosine could be detected. At last he sank into a state of coma, and died on March 17th.

On *post-mortem* examination the liver was found to be much atrophied, the greater part of it was converted into a flaccid, reddish, fibrous tissue, projecting from which were large yellow circumscribed bosses with some smaller isolated nodules of similar appearance. These evidently consisted of fatty liver tissue. On section these two different textures presented a distinct demarcation. The gall bladder contained a little brown bile.

On microscopical examination the red fibrous part of the liver

Fig. 2.

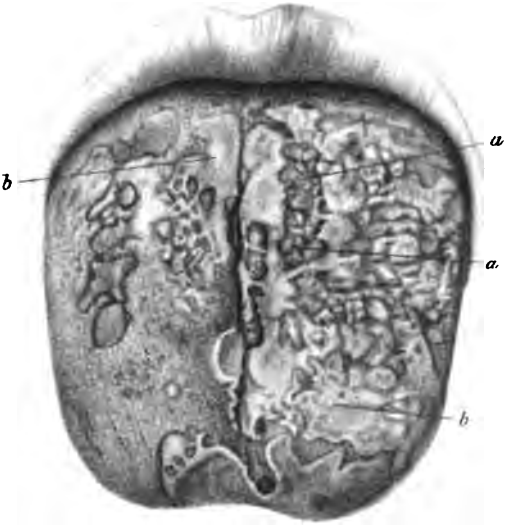

Fig. 1.

DESCRIPTION OF PLATE V.

FIG. 1.—To illustrate Dr. Cayley's case of Acute Yellow Atrophy of the Liver. (Page 127.)

The liver is reduced to scale, and shows the external appearance. The protuberances being bosses of the non-atrophied part of the liver which are seen in section in Plate VI.

FIG. 2.—To illustrate Dr. Hadden's case of Tubercular Disease of the Tongue (Page 135.)

a. Elongated ulcer with large yellow tubercular granulations in its floor.

b b. Ulcerated surface covered with a smooth yellowish slough.

DESCRIPTION OF PLATE VI.

To illustrate Dr. Cayley's case of Acute Yellow Atrophy of the Liver. (Page 128.)

Appearance of the liver on section.

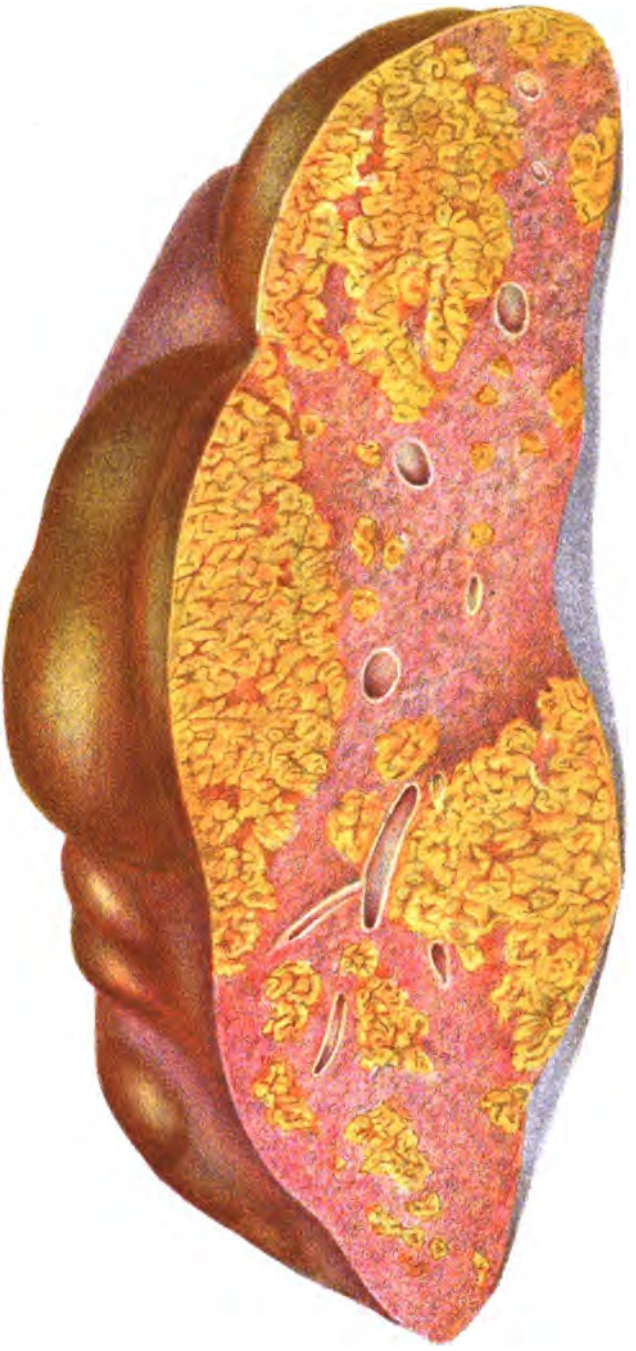

Mintern Bros Chromo imp

was seen to consist of a reticulated connective tissue with many nuclei. The yellow portions presented hepatic lobules, the cells of which were filled with oil globules and granular matter. At the margins of the yellow nodules the sections showed spaces in the fibrous tissue apparently due to the crumbling away of the liver cells. The liver weighed 35 oz.

The peritoneal cavity contained about two pints of ascitic fluid. There were several grey tubercular granulations on the peritoneal surfaces of the intestines surrounded by pigmented patches.

The stomach contained some altered blood, and the mucous membrane showed numerous small hæmorrhagic erosions. Throughout the whole of the small intestine and the ascending colon were numerous ulcers presenting the characters of tubercular ulcers.

The lungs showed adhesions at the apices, and at the right apex was a puckered fibrous patch surrounding a dilated bronchus, and showing old fibrous tubercular granulations.

With the exception of sub-serous ecchymoses the heart was normal.

The kidneys were enlarged and presented the characters of cloudy swelling. The spleen was small.

In this case it would appear that the acute atrophic process, fatty degeneration of the liver causing a rapid destruction of the secreting cells, had supervened on a chronic cirrhotic process, which had not caused any symptoms sufficiently severe to attract the patient's attention. The tubercular ulceration of the intestine which was found after death gave rise to no characteristic symptoms, as the patient was well nourished and had no diarrhœa.

The microscopical drawing was made for me by my colleague Dr. Finlay. *March 20th*, 1883.

---

25. *Cirrhosis of the liver in a child of seven months from congenital absence of the common duct.*

By Henrage Gibbes, M.D.

The following is a short history of a case sent me by Dr. Steel, of Abergavenny:—A male infant, the eighth child of healthy parents in good circumstances, born December 3rd, 1881, of good

average development, began to exhibit slight yellowness of the skin and conjunctivæ a few days after birth. This was regarded as simple icterus infantum, and was not treated, except with a mild dose of castor oil. As in the course of the next fortnight the jaundice persisted with clayey stools, other treatment was adopted, and carried out during six months, without success or any notable influence, except that under the use of iridin, in doses of two to three grains thrice daily, the stools occasionally became somewhat deeper in colour and the skin clearer, but the effect was not sufficiently decided to enable Dr. Steel to feel certain it was due to the drug.

The jaundice was never very deep in colour. Various other remedies were tried, including ammonium chloride, potassium iodide, and sodium salicylate, and external applications. Nutrition was maintained tolerably well until the sixth month, when wasting increased, and the abdomen enlarged from ascites. Death occurred on July 10th.

The *post-mortem* examination was made twenty-four hours after death, in some haste and under the difficulties often attending private cases. Dr. Steel was able to remove the liver, but no other organ.

There were some recent adhesions between the stomach, the transverse colon, and the pancreas, with effusion of lymph. The spleen and kidneys were congested, but were not specially examined.

The liver was hard and smooth, and weighed 4 oz. after being hardened in spirit. On carefully examining so much of the parts as were sent me I found no trace of the common duct in connection with the duodenum. The pancreatic duct seemed to be occluded, as it was impossible to get a bristle into it. I dissected out what appeared to be a portion of the hepatic duct, close to the liver, and this was filled with a fibrous mass. I could find no dilatation, but what I take to be the hepatic duct was very tortuous, and so firmly adherent to the surrounding tissue it was impossible to isolate it. The portal vein was normal. The parts had been very much cut up, and I could not make a satisfactory dissection of the gall-bladder and cystic duct.

On making a microscopical examination I found an enormous increase of interlobular connective tissue. This can be seen in the sections under the microscope as a dense fibrous stroma, having

small masses of cells in the alveoli. With high powers these cells are seen to be the epithelium of the bile-ducts; in many places the lumen can be made out, and this is generally filled with bile.

The fibrous tissue seems to have grown round the bile-ducts, and isolated them. I was able to trace the intermediary portion of the ducts to their junction with the hepatic cells. These cells are broken down, and do not stain with logwood.

I think this case may be considered one of cirrhosis following congenital absence of the common duct.

The fact that no jaundice appeared for the first few days after birth may, I think, be explained by the small amount of bile secreted at that early stage, having found its way into the diverticula of the bile ducts; after having filled these and distended the ducts it would then cause jaundice. *October 17th*, 1882.

---

26. *Lardaceous disease of the liver, the infiltration appearing to follow the course of the capillaries within the lobules of the organ.*

By F. Charlewood Turner, M.D.

[With Plate IX, fig. 3.]

The specimen exhibited is a portion of the greatly enlarged liver of a man, aged 34, who died from pneumonia in the London Hospital in June last after a short illness. There was a history of a chancre followed by sore throat, and a cutaneous eruption ten years before.

The liver, which weighed 11 lb. 8 oz., was uniformly enlarged, of firm consistence, and smooth on the surface. It cut like a lardaceous liver, and was stained by iodine in a typical manner. On section of the organ the lobulation of the liver tissue appeared distinctly mapped out, suggesting the presence of a condition of cirrhosis concurrently with the lardaceous degeneration.

Microscopical examination of thin sections from the organ showed no notable increase of connective tissue in the portal

tracts, but areas of liver tissue, consisting of portions of lobules, or small groups of lobules, surrounded by tracts of extreme lardaceous infiltration. In the former the liver cells are small and the vascular tracts wide, the two forming complementary networks not greatly differing in the thickness of their strands. At the borders of these areas there seems to have occurred a swelling up of the capillary network by an accumulation of the lardaceous material about the vessels with a consequent atrophy of the liver cells, the relics of which appear in a more and more attenuated network, as they are further separated from the still uninfiltrated areas (see Plate IX, fig. 3).

Within the well-defined boundaries of these areas are nodules of lardaceous infiltration, which appear to be continuous with the capillary network. They are seen bending round projecting angles of the liver cell network. In the specimen shown under the microscope a nodule of lardaceous material is seen indented on opposite sides by projecting angles of the liver cell network, between which a line of translucency can be distinctly traced, the appearance being as though an accumulation of lardaceous material about the adjacent capillaries had caused complete atrophy or displacement of the liver cells between them, reducing the liver cell network at that point to a mere thread for a certain distance. The specimen shows also lardaceous infiltration of the walls of the hepatic arterioles.

The kidneys in this case were also lardaceous. They were much enlarged and congested.

The heart was hypertrophied, weighing 16 oz. There was some lymph in the pericardium. No valvular disease.

There was grey hepatisation of the upper lobe of one lung, and purulent pleurisy over the lung generally. There was also some fibroid thickening and puckering of the apices of the lungs.

The spleen was enlarged, red, and fleshy looking.

January 2nd, 1883.

DESCRIPTION OF PLATE IX.

Figs. 1 and 2.—Illustrating Dr. Finlay's case of Epithelioma of the Stomach with Secondary Nodules in the Skin. (Page 102.)

From drawings by Dr. Finlay.

Fig. 1.—Section of the primary growth in the stomach, showing alveoli lined with columnar epithelium. (× 420.)

Fig. 2.—Section of a subcutaneous nodule. The appearances are similar to those seen in Fig. 1; the epithelium lining the alveoli, however, is scarcely so typical throughout, and the fibrous stroma is in greater abundance. (× 420.)

Fig. 3.—Illustrates Dr. Charlewood Turner's case of Lardaceous Disease of the Liver. (Page 131.)

From a drawing by A. T. Hollick.

Fig. 1.

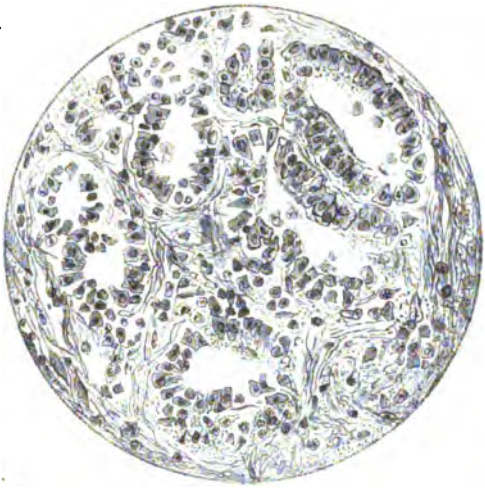

Fig. 3.

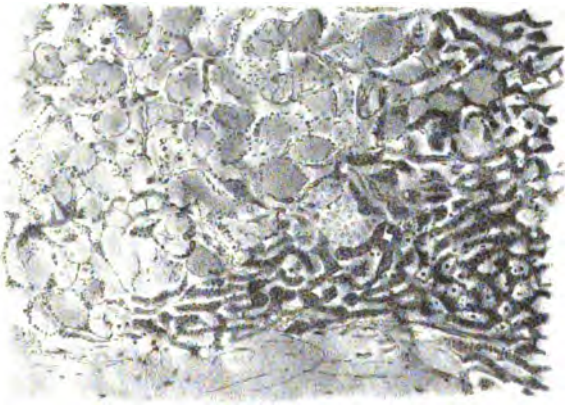

Fig. 2.

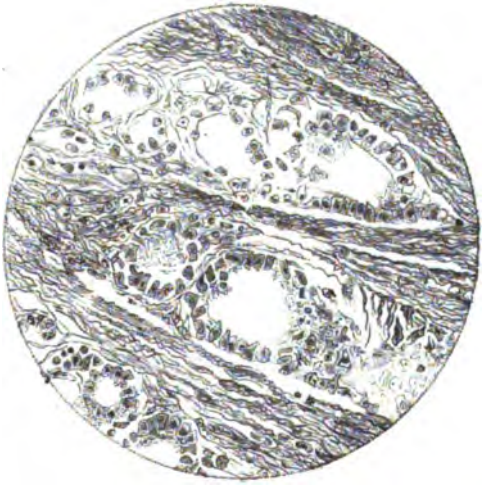

D. W. F. & T. Holbeck del.

West, Newman & Co. lith.

27. *Case of visceral syphilis.*

By NORMAN MOORE, M.D.

THE patient was a man, aged 56, who died in St. Bartholomew's Hospital. In November, 1881, he had hæmatemesis, and was admitted with ascites and general indications of cirrhosis of the liver. He was relieved, but was re-admitted in January, 1883, and died in a few days of general dropsy. There was a distinct specific history, and a scar on the glans. His viscera showed three forms of morbid change attributable to syphilis.

1. A general uniform thickening of the capsule of the liver and spleen without any general peritonitis. The spleen weighed 19 oz. Microscopic sections of the liver near the capsule showed in several places minute gummata close beneath the superficial thick layer of fibrous tissue.

The liver was reduced in size, but in the deeper parts no increase of connective tissue was present.

2. Amyloid disease of the kidneys.

3. Extensive calcification of the aorta with two aneurysms, one just beyond the arch, the other two inches above the diaphragm.

February 6th, 1883.

---

28. *Tubercle of the liver in an adult.*

By NORMAN MOORE, M.D.

THE liver of a man, aged 49, who died in St. Bartholomew's Hospital, under care of Dr. Andrew, of tubercular pulmonary phthisis with ulceration of the larynx. His lungs had large cavities.

The liver was studded throughout its substance with numerous whitish growths, most of them of the size of a large pin's head. Microscopic sections showed that these were tubercles. Giant cells were found in most of them; in some the cellular elements were not degenerate, in others caseation had taken place. All showed a considerable meshwork of connective tissue. Virchow, Cornil and

Ranvier, and Rindfleisch, describe tubercle as often found in the liver in the general tuberculosis of children, and Virchow states that it more often occurs in the liver than is generally thought, but cases in which the whole liver is infiltrated with tubercle at so late an age as forty-nine, in chronic phthisis with pulmonary cavities, are certainly rare in London. *December 5th*, 1882.

---

29. *Tubercular ulcers of the tongue.* (*Card specimen.*)

Exhibited by STANLEY BOYD.

W. F—, aged 47, a letter carrier. Seen March 21st, 1883, complaining of ulcers on the tongue. Scar on right side of neck, probably from suppurating glands, six years ago. Had suffered from night sweats, progressive loss of flesh, and cough without hæmoptysis for two years. Six months previously, his voice became aphonic and remained so. Gonorrhœa many years ago, but no syphilis. No family history of phthisis; of four children, the first died at one month in fits; the second at two years with a large abscess (?) below jaw; and another is an idiot.

Patient thin, and delicate looking. On the point of the tongue, just to right of mid-line, an ulcer as large as threepenny piece, covered by thin yellow slough, distinctly indurated for some little distance beneath base; edge sharply cut, smooth, not thickened, in depth about equalling the normal thickness of the mucous membrane. This ulcer had been forming three months; sense of irritation drew attention to part; red pimple found, touched with caustic, ulcerated about one month later and spread slowly; touched occasionally with caustic. During last two months four small ulcers formed on under surface of tongue behind tip; they vary in size from pin's head to a small grain of rice, not indurated at first but tending to become so, and to be covered by yellow slough as they slowly deepen. Practically, no pain; towards evening some irritation and redness of tip of tongue comes on. No large glands. Phthisis of both apices; early laryngitis.

No improvement followed a six weeks course of iodide of potassium, with lotion of Hydrarg. Bicyan. locally. Yellow slough cleared off large ulcer, leaving base covered by greyish red, rounded granulations of considerable size. The ulcers beneath tongue increased slightly in size, and a fresh one formed on left of tip, running into first ulcer on the right. This new ulcer was quite superficial at first, just baring papillæ; it spread rapidly, as compared with the others, and there was no induration at its base.

The presence of phthisis, absence of history and signs of syphilis, uselessness of antisyphilitic treatment, a distinct difference in appearance between these ulcers and ordinary syphilitic ones, the sex of the patient and the situation of the ulcers on the edge and under surface of the tongue near the top seem to justify the diagnosis of "tubercular" ulceration. *May 1st*, 1883.

30. *Tubercular disease of the tongue.* (*Card specimen.*)

Exhibited by W. B. HADDEN, M.D.

[With Plate V, fig. 2.]

THE patient, aged 47, was admitted into St. Thomas's Hospital under Mr. Croft on February 23rd, 1883. Ten weeks before admission a small sore spot was noticed on the under surface of tongue near the tip.

On admission there were numerous superficial erosions, from the size of a shilling downwards, over the anterior half of left side of tongue. The part was red, swollen, and indurated. There was no glandular enlargement. Two prominent lower incisors were removed, as it was thought they might be a source of irritation. Antisyphilitic medicines were ordered, although no specific history could be obtained. The ulceration gradually extended over the greater part of anterior two-thirds of tongue, and to the under surface on left side. The ulceration was superficial, although there was much thickening on the surface and considerable deep-seated induration. Before death signs of phthisis were discovered. The temperature throughout was of an intermittent character. He died forty days after admission.

In the specimen there is superficial ulceration over anterior third and under surface of tongue on left side. The rest of tongue, in front of circumvallate papillæ, is white and very hard. Under the microscope there were numerous areas of lymphoid cells, with some ill-defined giant cells between the muscular fibres. There was extensive consolidation of both lungs, and three small cavities at the apices.

In the large intestine there were numerous ulcers, on the floor and edges of which many grey tubercles were visible.

There were also miliary tubercles in pia mater at base of brain.

There was also an ulcer on left vocal cord and on mucous membrane of trachea. *May 1st*, 1883.

31. *Primary cancer of pancreas.* (*Card specimen.*)

Exhibited by PERCY KIDD, M.D.

THIS specimen was taken from a patient who died of pulmonary phthisis, but in whom during life there was no suspicion of any abdominal disease.

Summary of *post-mortem* examination:

Lungs.—Advanced phthisis; cavities in both lungs.

Intestine.—Extensive tubercular ulceration of large and small intestine.

Mesenteric glands hard and slightly caseous.

The head of the pancreas was transformed into a firm, rounded mass, as large as a duck's egg, the tail of the organ being extremely atrophied.

Stomach.—Mucous membrane slightly mamillated.

No other new growth was found.

The growth in the pancreas proved to be a carcinoma on microscopical examination.

One of the largest mesenteric glands was also examined microscopically, but showed only a fibro-caseous change.

April 19th, 1883.

32. *Cirrhosis of liver.* (*Card specimen.*)

Exhibited by ANGEL MONEY, M.D.

THE liver weighed 19 oz., measured 7½″ across, 4½″ from before back, and 1½ thick. Consistence greatly increased; very little true liver tissue remains; the fibroid overgrowth is very extensive, and of grey-red colour. The surface is irregularly nodulated. No fibrosis of any other organ. There was some green pus in pelvic cavity.

Taken from a female child, aged 8.

There was a history of general pain since Christmas, 1880. Ascites and œdema of lower limbs set in April 28th, 1882. Jaundice noticed on May 5th. Death May 13th.

Patient sat on wet grass one week before dropsy set in.

At the age of three years patient lived for two months with some relations who kept a beershop, and the father believes she there acquired a taste for liquor.

There was no evidence of syphilis. At least a personal examination of all the members of the family, and cross-examination of the parents, failed to elicit any satisfactory testimony of this disease.

January 2nd, 1883.

33. *Deposit of lime salts in mucous membrane of hepatic ducts in an ox.* (*Card specimen.*)

Exhibited by B. G. Morison.

The whole mucous membrane was calcified; the salt chiefly carbonate. Two liver flukes were found in one of the ducts. The liver was normal in other respects.

January 2nd, 1883.

34. *Intestinal obstruction resulting from adhesion of the ileum to the mesentery* (*Card specimen.*)

Exhibited by F. Taylor, M.D.

Removed from a man, aged 57. He had been ill for fourteen days with frequent vomiting; dull heavy pain at the pit of the stomach; constipation for the last four days; hiccup since the preceding evening. He was extremely collapsed on admission, with frequent hiccup, eructation, and vomiting of sour-smelling yellow fluid, like pea-soup; not distinctly stercoraceous.

The abdomen was only moderately distended; no scybalous masses could be felt; rectal examination gave no indications. He died in a few hours.

The large intestine was found contracted and empty but for a few fæcal masses. The lower two thirds of the ileum were empty, firmly contracted, and lay close to the cæcum. A mass of bowel forming the upper part of the ileum, was matted together, and lay in the pelvis; the coils composing it were partly distended, partly contracted, respectively above and below an obstruction, the nature of which was shown in the specimen.

This consists of the greater part of the ileum with its mesentery. About the middle of the ileum the mesentery has become folded upwards and to the left, in front of itself, and two layers are adherent to each other by organised pigmented adhesions for a length of about four inches. The intestine attached to the reflected mesentery is also to the adherent surface of the normal mesentery, just above and parallel to its attached intestine. By this adhesion of the bowel, and the consequent sharp flexure in its course, an obstruction was produced, the bowel above the flexure being distended; that below, as well as the adherent bowel itself, being empty and contracted. The mucous membrane is normal. There was no ulceration or other disease than the adhesion.

There was an empty hernial sac, admitting two fingers, in the left inguinal canal.

April 17th, 1883.

V. DISEASES ETC., OF THE GENITO-URINARY ORGANS.

1. *Renal calculus and abscess (traumatic?) ruptured into left pleural cavity.*

By JOHN R. LUNN.

G. B—, aged 65, widower, a bricklayer by trade, was admitted into the Marylebone Infirmary, Notting Hill, December 24th, 1881.

On admission he said he had been well until two months previously, when he had been run over on the back by a cart: and since then he had been laid up with pain in the loins and weakness. He had had some hæmaturia before admission.

No fracture or external marks of injury were to be seen, and no disease could be found in abdomen.

He was weak but fairly nourished, partially demented, being quiet, apathetic, unable to do much for himself, and rather drowsy.

He remained in bed for some time on account of pain and weakness and supposed injury; but before long got up and about every day without any inconvenience, except from an old irreducible scrotal hernia.

He remained feeble and apathetic, and never complained much. He showed very little alteration for a long time, except that he got weaker very slowly, shown chiefly by apathy, inability to make much exertion, tendency to loss of appetite, and frequent attacks of incontinence (without retention) of urine, chiefly by night. Never subject to rigors, heats, or sweats, and the temperature when taken was always normal. The urine was generally pale, non-albuminous, never contained blood, sometimes contained a small trace of pus by microscopic examination.

September, 1882.—He became a good deal more feeble without any apparent cause; he had anorexia; stayed in bed; was constantly drowsy, never complained of pain; had no rise of temperature.

20th.—A great deal of pus was passed by the urine for the first time. On examining the abdomen a large spherical elastic tumour was felt in the left hypochondriac and lumbar regions, reaching forwards nearly to the umbilicus, and downwards nearly to the iliac crest. It was fixed, and there was no resonance on percussion over it.

On the same day an aspirator needle was introduced at the most prominent part, a little below and in front of the left costal cartilages; three pints of very offensive (fæcal odour) pus were withdrawn.

The next day (21st) the urine was almost clear, and the tumour was much smaller. It slowly regained its former size, and in about a month it was as large as before.

Pus was present in the urine on some days and absent on others.

The patient gradually became thinner and weaker, without rigors or bed-sores.

October 25th.—Became more collapsed rather suddenly, and died the same evening.

Post-mortem notes.—Body not well nourished; no bed-sores or signs of violence about his body; rib cartilages very slightly calcified.

Heart.—Pericardium empty, weight 8½ oz., small and contracted; walls soft and brownish; cavities normal.

Lungs.—In left pleural cavity was a large quantity (one to two pints) of thin pus, occupying, as the body lay horizontally, the posterior portion of the cavity. With the exception of one broad band of old adhesion about the centre, the lung floated freely in the pus. It was collapsed, but not compressed, nearly airless, and dry.

On emptying the cavity the posterior surface of the pleural cavity near the spine was seen to be much congested, with a thin adherent layer of recent lymph.

Right lung.—Universally adherent by old fine fibrous tissue; organ apparently healthy.

Liver.—Normal.

On left side of abdomen the spleen, descending colon, and left

kidney were closely adherent together and to abdominal walls, the kidney and spleen being concealed mostly by the stomach, colon, and ribs.

Right kidney weight 4½ oz., small, but healthy in appearance.

Left kidney much enlarged; it formed a large thick-walled sacculated cyst, containing pus, but only partially filled, and weighed, when empty, 22½ oz. It was intimately adherent by fine, short, fibrous tissue, to diaphragm above, loins behind, and ribs outside; also to descending colon in front, which was stretched over it. It was very thin above, and its wall and the diaphragm were pierced by a small ulcerated aperture into the left pleural cavity, by which the kidney had evacuated much of its pus into the pleura. The capsule of the kidney was indistinguishable from cortex, but was blended with it into thick, tough, fibrous tissue, not easily separable from the surrounding structures.

No trace of proper renal structure remained; the body of the organ was divided into a number of communicating cavities (expanded calyces and pelvis?) by partitions, all lined with smooth grey membrane, and containing thin, greasy pus.

Ureter not dilated, but its mucous membrane thickened and stained black.

At the upper end of the ureter, either in its mouth or in the pelvis contracted over it (which of the two could not be exactly made out—the organ was too deformed), was a large T-shaped calculus with cylindrical branches, black and granular externally; encysted and very slightly movable, in a smooth well fitting cavity, communicating with the rest of the interior of the kidney by a small round aperture.

Bladder not dilated or hypertrophied; mucous membrane healthy.

The calculus weighed 106 grains, and consisted of a thin, smooth, irregular covering, soft, black, and laminated, apparently inspissated blood; and an internal nucleus, irregular, nodular, dark brown, hard, and laminated, consisting of uric acid chiefly.

I am indebted to my friend and colleague, Dr. Benham, for able assistance with the above case, and also to my late teacher Dr. Ord, for kindly examining the calculus, which he reports is chiefly uric acid and organic matter.

Remarks.—The above case is interesting on account of the hæmaturia which occurred two months before the patient's admis-

sion, and because of the uncertainty of the cause of this, whether accident or calculus. The symptoms pointing to renal calculus were few, and the man had neither constitutional symptoms nor rise of temperature.

Lastly, the mode of death is worthy of record, there having been no symptoms of the abscess bursting into the pleural cavity during life, and the right kidney was apparently quite healthy in appearance and structure. *January 2nd*, 1883.

---

2. *Alveolar sarcoma of the capsule of the right kidney.*

By J. KNOWSLEY THORNTON, M.C.

THIS large sarcomatous tumour I removed from the abdomen of a woman, aged 53, by median incision, on February 2nd, 1883, at the Samaritan Hospital.

It is apparently a sarcoma of the capsule of the right kidney; the organ itself is seen bedded in the centre of it, and beyond, being slightly smaller than normal, does not appear unhealthy. The renal artery and vein were enormously enlarged, the blood rushing through the former with a strong purring thrill. After the removal of the tumour I was unable to find the kidney end of the ureter, but, from what I saw of its situation when securing the bladder end of it during the operation, I believe it passes through a large portion of the tumour, *i. e.* the tumour is developed in the capsule round the pelvis of the kidney and the ureter.

The patient had been married twenty-eight years, and had borne four living children. The tumour was first noticed as a mobile lump in the abdomen six years ago, and just at the menopause. It grew very slowly at first, but latterly faster, and from a weight of fifteen stone, she had become during the last few years emaciated and anæmic.

At the time of admission into the hospital the urine was quite normal.

My first diagnosis was a correct one, but after repeated examina-

tions, and always finding a clear space behind the tumour in the right loin, I began to think that the tumour was ovarian, and the operation was commenced with the median incision under this impression. Immediately the peritoneum was opened, however, it was clear that the original diagnosis was correct.

The operation was rendered difficult by the median incision, by the large solid mass interfering with the ligature of the renal vessels, by the extreme vascularity of the capsule, and by slipping of a large vessel into the cellular tissue behind the peritoneum and under the border of the liver, but it was completed in an hour and three quarters. The patient, when placed in bed, had a normal temperature, and pulse of 104.

The tumour weighed 11 lbs.

The bladder end of the ureter was dropped in, after being securely ligatured. A counter-opening was made in the loin, and a drainage tube introduced close to the dropped ureter. The necessity for this proceeding was made evident by free discharge of dark serum for some days, followed by offensive suppuration, eventually requiring another opening farther back in the loin, and first an india-rubber drainage tube right through from one opening to the other, and then a horsehair drain in the same situation for some weeks longer.

My own examination of the minute structure, would lead me to place the tumour as an alveolar sarcoma of the capsule of the kidney.

Messrs. Eve and Vincent Harris have also been kind enough to examine the tumour. Mr. Eve says "The character of your tumour may be briefly summed up as follows:—It consists of rounded cells, often of large size, finely granular, and having each one or more distinct nuclei; in places the cells are arranged somewhat indistinctly in columns, elongated masses, or 'streaks,' while in others they are confusedly crowded together."

Dr. Harris says: "Both in the arrangement of the cells in columns, and also in the shape and general appearance of the cells themselves, the tissue greatly resembles the suprarenal capsule. More than that I am unable to say."

I may point out that the slow growth favours my own view, that it is an alveolar sarcoma, and that its position with regard to the kidney is against the notion that it is of suprarenal origin. I am not aware either that any tumour of this size has ever been found,

or described as growing from the suprarenal capsule. In the portions I examined I did not find the columnar arrangement, but a distinctly alveolar one, the groups having a coarse alveolar stroma and the single cells also a very delicate one; probably, as in most sarcomata of this size, its structure varies in different parts.

Since the patient returned home the remains of the bladder end of the ureter, with my silk ligatures partly absorbed, bedded in its tissues, has come away as a slough, proving to me that my opinion as to the surgical importance of bringing this portion of ureter to the external surface of the wound is correct. One of the silk ligatures used on the capsule has also come away through the same opening. Dr. Jones, of Enfield, writes to me on April 20th, that the patient is getting stout again.

The only complication in the case has been the putrid suppuration round the bladder end of the ureter, which may, of course, have communicated itself to many of the silk ligatures, and rendered it necessary that they should be cast off, instead of being absorbed, as in aseptic conditions. *February 6th*, 1883.

---

8. *Tests for albumen in urine.*

By CHARLES HENRY RALFE, M.D.

FOUR specimens of urine are brought forward this evening to show the range of the newly-proposed tests for albumen, viz. the picric-acid test, the ferrocyanide of potassium and citric acid, the brine test, and the test papers proposed by Dr. Olliver.

The four specimens of urine are—1. A urine containing seroalbumin from a case of Bright's disease. 2. The same urine modified by means of acid. 3. An alkaline urine containing pus and mucus, but no discovered or suspected renal disease—probably a case of vesical catarrh, in which the albumin of the pus has become altered owing to the alkaline reaction (ammoniacal) of the urine. 4. Urine from a case of peptonuria, in which the ordinary albumin has been removed by boiling and filtration, leaving only the peptones behind.

In all four urines it will be seen that the reagents named above

give a precipitate, a cloudiness, or a coagulation; they therefore show that the urines contain an albuminous or proteid substance of some kind, but they do not inform us of its nature. In order to determine this further tests must be applied. Thus, on boiling we find that only No. I gives a coagulation, whilst Nos. II, III, and IV are unaltered. This denotes the presence of serum albumin, since the blood albumin—sero-albumin and paraglobulin alone coagulate by heat—72°—76° C. No. II, however, coagulates when neutralised with sodic carbonate. No. III does the same when neutralised with dilute acid. No. IV gives a faint precipitate (parapeptone) when neutralised with sodic carbonate, but it is not a coagulation such as occurred in No. II; it differs also in the fact that when Fehling's solution is added to it, it gives a rosy red coloration, whereas Nos. I, II, and III give a mauve.

Now, the conclusion to be drawn from these facts is that, however delicate these new tests are, they are not sufficient to determine the nature of the albumin present; for this purpose heat must be employed in order to discriminate between sero-albumin—the important albumin clinically—and any modifications caused by alterations in reaction of the urine, or the presence of a distinct form. It will thus be seen that while the new tests are cleanly, efficient, and portable substitutes for nitric acid, they do not supersede the test by heat. This must always be employed for the recognition of sero-albumin in an unaltered form in urine. The difficulty of applying this test at the bed-side would be obviated if, instead of the cumbrous spirit lamp, the practitioner would use a piece of ordinary wire gauze, which, placed between the flame of a candle or gas-burner, would prevent the test-tube or spoon in which the urine was boiled from becoming blackened, and thus answer all the purposes of the spirit lamp. The wire gauze need not exceed a square inch—small enough to be carried in the pocket case.

March 6th, 1883.

4. *Sarcoma of prostate and bladder, of very rapid development.*

By SAMUEL WEST, M.D.

ROBERT G—, aged 21, gave the following history:

On September 16th had difficulty in passing water, and his bladder was distended. He was catheterised and admitted into the Royal Free Hospital.

27th.—He had some hæmorrhage from the bladder; 10 oz. were drawn off with the catheter, and 16 oz. again three hours later. He passed at the time blood-clots, and also two "fleshy bodies," which were not examined.

The rectum was examined by the finger three weeks before death, and no tumour felt.

Cancer was suspected only a few days before death.

Post-mortem.—A large tumour, soft, semi-diffluent, occupied the place of the prostate gland, and was composed of small round and spindle cells, and had a few hæmorrhages in it. It was of the size of a large orange.

The rectum was empty and flattened by the tumour.

The urethra was dilated, so as to admit the middle finger easily, and in it lay a fleshy polypus two inches long, attached by a long and narrow pedicle to the origin of the bladder; part of this was discoloured, and from it the hæmorrhage had clearly taken place.

One large oblong mass, 2½ inches long, soft, cellular, and similar to the prostate tumour, arose from the side of the base of the bladder. Several small pedunculated masses took origin from various parts of the base near this.

The bladder was distended, and contained several ounces of altered blood.

The ureters and pelves of the kidney were both much dilated.

The kidneys enlarged, the cortical part degenerated, and containing numerous small punctate abscesses, the largest as big as a barley-corn.

The other organ was healthy; no secondary deposits.

The interest of this case lies, not only in the organ affected, but in the extreme rapidity with which the tumours grew, for when the rectum was examined, three weeks before death, there was no

evidence of any enlargement of the prostate, so that the whole of this tumour must have reached its present size within three weeks.

A case of similar rapid growth of sarcoma, with references to other instances, is recorded earlier in the present volume.

November 21*st*, 1882.

---

5. *A sacculated bladder in a female.*

By W. Hale White, M.D.

Mary R—, aged 55, admitted into Guy's under Dr. Wilks in June, 1882; married; no children or miscarriages. Her abdomen was tapped twenty years ago and fluid drawn off. Since that time she has been quite well. She was admitted for hæmaturia and pyuria, accompanied by bearing-down pain. It was evident that she was suffering from cystitis, but no cause for it could be detected, and she sank and died.

On *post-mortem* examination the bladder was found very much thickened, and the whole of the inner surface was covered with a deposit of phosphates; the cystitis had evidently been severe. On the inner surface of the bladder, between the orifice of the left ureter and the commencement of the urethra, was an opening about a third of an inch in diameter, through which a quantity of muco-purulent, grumous urine oozed. This opening led into a thick-walled cavity, rounded, considerably larger than the bladder itself to the left and in front of which it was situated. The lining membrane of this cavity was evidently inflamed, and had a coating of phosphates deposited upon it.

To the right of the uterus, between it and the bladder, was a thin-walled cavity, about as large as a walnut, which contained a quantity of thin pus, but did not communicate with the bladder. The right kidney had at its upper part a small abscess, but with the above exceptions all the organs in the body were healthy.

The immediate cause of death appears to be evident, namely, that urine was retained in the large cavity to the left of the bladder; there it decomposed, slowly trickled into the bladder, and rendered the cure of the cystitis impossible; but the interesting question is,

What is the cause of the large secondary cavity communicating with the bladder? One of the first suggestions made was that it was a case of double bladder, but I think there can be no doubt that this is not so, for such an abnormality is excessively rare; in fact, although I have looked in several books and museums, I cannot find an example. Besides which, in this case, both the ureters opened into, what is surely for this reason, the true bladder. Seeing, therefore, that the cause is not anatomical it must be pathological, and the sac may be either a sacculus of the bladder, or some cavity abscess or otherwise, opening into the bladder.

Sacculi as large as this are not common. The largest recorded is one mentioned in 'Gross's Surgery' as occurring in the practice of Professor W. Greene, in which it contained a gallon of urine, and so pressed on the abdominal viscera that it impeded respiration.

In the Pathological Society's 'Transactions' (vol. iii, p. 128) there is an example of a sacculus, so large that it formed an abdominal tumour. In vol. xiv, p. 133, there is an example recorded by Murchison of a sacculus springing from the right side of the bladder, which pressed on the right iliac vein in such a manner as to cause thrombosis of it with œdema of the leg, and finally death; and in vol. v, p. 199, is an example, in which the sacculus was so large that during life it was mistaken for an enlarged prostate. The cause of the disease in all these cases was stricture; and next in frequency comes stone, but as both these affections are almost confined to the male sex, I have looked through the *post-mortem* records of Guy's Hospital for six years, during which time nearly three thousand *post-mortem* examinations have been made, and among these are twenty cases, or 1 in 150, in which the bladder was sufficiently sacculated for the sacculation to be recorded, but not one of these occurred in the female sex. The causes were distributed as follows:—Eleven cases were due to stricture, five to stone, two to spinal disease (one to fractured spine and one to transverse myelitis), one to enlarged prostate, and one happened in a patient who died of epithelioma of the face, in whom no cause could be found for the sacculation. In not more than four and probably in only three cases was the sacculus as big as the bladder itself. We thus see that sacculation of the female bladder is excessively rare, and probably the only two causes for it, likely to prove fatal, are spinal disease and inflammation (such as pelvic cellulitis), spreading from neighbouring parts. As regards the first of these, the spinal affection which most

frequently produces cystitis is fracture or dislocation of the spine; but, from their occupation, women are not liable to such injuries. In this case there was no spinal disease, so that if the cavity to the left of the bladder is a sacculus, it was probably caused by some inflammation in the pelvis setting up cystitis. If it be not a sacculus in the strict sense of the word, but an abscess cavity which has opened into the bladder, this cavity has behaved just as a sacculus would, and has been the cause of death by continually keeping up the cystitis, which would otherwise have been controlled by the various remedies applied, such as washing out the bladder. Possibly, considering the presence of the smaller cavity containing pus and situated to the right of the uterus, the larger cavity to the left had its origin in a pelvic abscess opening into the bladder.

March 6th, 1883.

---

6. *Large calculus with a nucleus formed of a mulberry calculus; removed from the bladder by lithotomy.*

By GEORGE LAWSON.

THE calculus exhibited, and which is well represented by the woodcut on the next page, I removed from a man, aged 48, by lateral lithotomy, at the Middlesex Hospital, on March 10th, 1883.

When I sounded the patient the stone was felt to be very hard and large, and I thought that lithotomy afforded a better prospect of success than a Bigelow's operation. When removed, the stone was found to measure 2½ inches in length, 2 inches in width, and 1½ inch in depth. It weighed 4oz. all but 60 grains. Its surface was nearly smooth, of a yellowish-white colour, and when washed was inodorous. On making a section of the stone about a drachm of a reddish-brown stinking ammoniacal fluid escaped. The nucleus of the stone was a mulberry calculus, very rugged in outline, and measuring seven eighths of an inch in each of its two principal diameters. The bed in which this calculus lay was too large for it, so that there was a free space around it, and this space was filled up with the reddish-brown fluid. The explanation of the manner in

which this collection of ammoniacal fluid was incarcerated within the stone was, I believe, the following :—At the period of the stone's growth, when the mulberry calculus was free in the bladder, there had been cystitis, and the interstices between the nodules had become filled up with mucus, and muco-pus mingled with ammoniacal urine. The irregularities of the stone being thus obliterated it presented a tolerably smooth surface, upon which the salts of the urine were deposited in concentric laminæ, as seen in the specimen.

Woodcut 4.



A quantity of ammoniacal and tenacious matter was thus pent up within the stone, and this undergoing decomposition and becoming stained with the colour of the oxalate of lime calculus with which it was in contact, produced the reddish-brown ammoniacal fluid which escaped when the section of the stone was made. The patient has done well.

Dr. Thomas Taylor, late Lecturer on Chemistry at the Middlesex Hospital, kindly examined the calculus, and has given me the following report :

"This calculus is of a flattened, oval form. It measures 2½ inches in its long axis, and 1½ and 2 inches respectively in its two shorter axes. The nucleus and central portion consist of a mulberry calculus about seven eighths of an inch in diameter, around which are irregular spaces, which were filled with pus, mucus, and putrid urine. The rest of the calculus consists principally of compact semi-crystalline triple phosphate, containing irregularly alternating layers of oxalate of lime, mixed with traces of uric acid and

phosphate of lime. The surface of the calculus is nearly pure triple phosphate."

The following notes I have added for the completion of the case:

On the eighth day after the operation there was evidence of some ulceration of the rectum by the escape of fæces and flatus through the wound, The man, however, in other respects progressed well, and all bladder symptoms were completely relieved. Owing to the communication with the rectum the wound was very slow in healing. The patient left the hospital for the country in July, but there was still a fistulous opening, through which a portion of his urine continued to escape. No fæces escape now by the wound, except when the evacuations are fluid.

If the fistula does not completely close the man will come up again to the hospital for further treatment. *March 20th*, 1881.

---

7. *Mucous polypus of the urinary bladder.*

By SAMUEL G. SHATTOCK.

POLYPUS of the urinary bladder is a form of new growth sufficiently rare of position to merit a recorded description; and besides its intrinsic or pathological interest there is a practical interest which attaches to this and other tumours of the bladder in so far as their removal is possible by surgical procedure.

The specimen was obtained from a female child, 1½ years of age, who was under the care of Mr. Marshall in November, 1877. The bladder was distended during life so as to reach the umbilicus. The child was very exhausted, and died before any grave operation for its relief could be attempted.

After death some pale brownish serum was found in the abdomen. Both the lungs were congested at the bases, but as regards the other viscera nothing abnormal was noted. The polypus is connected with the right side of the base of the bladder, between the opening of the right ureter and the urethral orifice, and is attached by a short pedicle about half an inch in diameter, from which a low outgrowth of the mucous membrane extends around the opening of the right ureter as far as the middle line. The

mucous membrane over the rest of the base of the bladder is slightly swollen and minutely rugose, the swollen membrane having a distinct upper margin in which direction it extends about a third of an inch above the orifice of the right ureter. The tumour is partly cleft into lobes, or in places more deeply divided and compounded of secondary pedunculated masses. When close-packed it forms an ovoidal mass about one and three quarter inches by one and a quarter in its chief diameters. The surface of the different parts of the tumour is uniformly smooth, and the growth itself is soft, compressible, and largely infiltrated with fluid, its texture resembling that of the ordinary nasal polypus. A long process, over an inch in length, occupies and projects beyond the urethra which is considerably dilated around it, and behind is confluent, from ulceration, with the vagina. This part of the tumour is deeply congested, and superficially ulcerated. The ureters and pelves of the kidneys are to some degree, and equally, dilated, but the substance of the kidney looks healthy, and the microscopic section proves no degree of fibrosis.

The bladder is slightly fasciculated.

Morbid histology.—Microscopic sections of lobules of the tumour display, after hardening in alcohol, oval and more elongated cells lying in an abundant intercellular substance, either albuminous or mucous, and scantily traversed by fibres; no stellate cells are present. At the peripheral parts of the lobules the tissue is for some depth composed of small, close-packed, spheroidal cells, a fact which may mark peripheral growth in the tumour. The investing epithelium, so far as can be guessed from what remains of it, is like that which normally lines the bladder.

There are two specimens of this rare form of vesical tumour in the museum of the Royal College of Surgeons. One of these is from a boy in whom the bladder was opened partly on the supposition of a calculus being present; the growths were, many of them, cut off with scissors. No hæmorrhage followed.[1]

The other specimen is from a female patient. "Numerous, lobulated, cauliflower-like polypous growths rise from the mucous lining, and nearly fill the cavity of the bladder; some of the growths have protruded through the urethra, and their ends are ulcerated and flocculent." *January 2nd*, 1883.

[1] Reported by Crosse, 'A Treatise on Calculus,' fig. 2, p. 20, 1885.

8. *Sarcoma of a diverticulum of the bladder.*

By W. Roger Williams.

The patient from whom this specimen was obtained—a thin, grey-haired, fairly healthy-looking Frenchman, aged 62—was admitted into the Middlesex Hospital on November 17th, 1882, under the care of Mr. Henry Morris, who has kindly allowed me to publish the case, complaining of great frequency of micturition by night and day, and of some pain in the act. He also complained of weakness and pain in the left lower limb, so that he could not walk without support; and this pain generally resembled somewhat that of sciatica. He passed rather a small stream, but it was fairly well projected, and quite free from blood.

No. 10 English catheter passed easily, so there was evidently no stricture worth mentioning. A small quantity of rather turbid yellowish urine was drawn off; specific gravity 1015, alkaline, and slightly albuminous. He was sounded, but no stone or other vesical abnormality could be thus detected.

After these proceedings there still remained dulness in the suprapubic region, extending upwards for a few inches above the symphysis, and to a greater height in the left iliac fossa.

A firm, smooth, elastic mass could be felt, occupying this area, apparently springing from the pelvis.

Rectal examination revealed prostatic enlargement of the ordinary kind, and the bowel was found full of scybala.

At the end of these various manipulations the patient passed about half a pint of urine, deeply blood-stained; whereas just previously it had been free in this respect.

His temperature was 100·8° F. At this time there was very little constitutional disturbance.

He says he first experienced some difficulty in micturition several years ago, and that he has never had complete retention. His present urinary troubles began four months ago without any known cause; at the same time he first began to experience pain and weakness in his left leg. These symptoms have since progressed *pari passu*. It is only during the last two months that he has occasionally noticed his urine of a bloody colour. When young he had

gonorrhœa, but not syphilis. He is a teacher of French, married, and of temperate habits.

With the object of emptying the rectum, and seeing what effect this would have on the abdominal tumour, large soap-and-water enemas, preceded by the injection of olive oil, were administered; but these caused no diminution in the size of the abdominal tumour. The fæcal matters thus evacuated were pale and hard, but not otherwise abnormal.

A few days after this examination his urine again became quite free from blood; further manipulation of the tumour, however, caused it to reappear shortly afterwards.

About this time his left foot and leg first became swollen and œdematous; otherwise his condition remained unchanged. From this date a great alteration was observed, both in the urinary and in the general symptoms, evidently the result of inflammatory change in the bladder.

The urine now became exceedingly thick, puriform, and fœtid; whilst an asthenic type of fever developed, under which the patient rapidly sank. He died thus on December the 6th.

At the *necropsy* by Dr. Fowler, on the following day, some old fibrous adhesions were found in connection with the right pleura. Both lungs were emphysematous, and there was some recent lymph about the root of the left.

The heart was normal.

On laying open the abdomen the pelvic peritoneum was seen to be pushed upwards, nearly to the level of the umbilicus, by some intra-pelvic growth.

The spleen was small and pinkish, its capsule thickened in places. The liver was compressed and slightly fatty, whilst the gall-bladder contained numerous calculi.

The small intestine, at about two inches above the ileo-cæcal valve, was adherent to the peritoneum covering the pelvic tumour. Some coils of small intestine lying near the left side of the spine, behind the tumour, were covered with recent lymph.

The cæcum and ascending colon contained hard scybala.

In removing the intestines pus was found in the cellular tissue behind the descending colon, and also over the psoas and iliacus muscles where these came into contact with the growth.

The rectum, much flattened, could be seen passing downwards in the middle line behind the tumour.

The left kidney was small and much sacculated, only a thin layer of its secreting structure remaining. Its pelvis and ureter were much dilated; but the mucous membrane of these parts was pale and smooth, presenting no signs of inflammatory changes. The opening of this ureter into the bladder was patent, and it was not involved in the vesical disease.

The right kidney was congested, but only sacculated to a slight extent; its pelvis and ureter were dilated, and full of stinking pus, the mucous membrane of these parts being of a deep purple colour and intensely injected. The lower opening of this ureter, though patent, was involved in the vesical disease.

The bladder itself was compressed and flattened by the growth against the right wall of the pelvis.

On removing the genito-urinary organs with the pelvic contents and the growth *en masse*, extensive suppuration was found to have taken place behind the latter, to which the iliac vessels and the commencement of the great sciatic nerve were adherent on the left side.

The iliac vein was found to be completely blocked in this situation by a thrombus of comparatively recent formation, extending down the femoral and profunda veins nearly to the middle of the thigh.

The walls of the bladder, which was of normal size, were hypertrophied, and its mucous membrane was of a slaty colour. The prostate was hypertrophied to a moderate degree.

About an inch above the orifice of the left ureter, and on this side of the bladder, was a rounded opening the size of half a crown, which led into a diverticulum considerably larger than the bladder itself. This contained a soft fleshy growth about the size of an ordinary apple, which was attached by a broad base to that end of the diverticulum furthest from the opening into the bladder. This it was that had been felt through the abdominal walls during life. The lining membrane of this pouch, where it came into contact with the growth, as it did in nearly its whole extent, presented diffuse outgrowths of a tissue similar to that of the primary tumour. The margins of the opening into the bladder were similarly affected, and from its lower part the disease had spread downwards into the bladder, so as to involve the orifice of the left ureter, as previously stated.

This diseased patch had evidently been pressed by the progress of the primary tumour against the opposite wall of the bladder;

and it was interesting to observe that a similar outgrowth had formed there at the point of contact. This certainly appeared to have resulted from a local infection by direct implantation, and I have observed that such a result is common with tumours of this kind when the thin capsule which originally lines their free surface has become eroded or destroyed in some other way. As this seldom happens until a comparatively late stage of the disease the primary growth is usually found to be very much larger than the secondary ones; and when the former has retained its capsule intact it is quite exceptional to find any secondary growths. This is a point of some practical importance.

But to resume: the bladder and its diverticulum contained a considerable quantity of purulent, stinking urine, mixed with sloughy shreds from the diseased parts.

On making a section of the primary growth its base and the parts beneath it were found to be in a state of suppuration; but there was no extension of the growth beyond the walls of its containing pouch.

The peritoneum covering the diseased portions of the bladder was not generally adherent to them; indeed, the only adhesions that existed were obviously the result of inflammatory changes behind and beneath the growth. The glands near these inflammatory foci were enlarged, but they presented no signs of secondary disease; neither were there secondary deposits in any part of the body.

The microscopical characters of these various growths are identical, consisting chiefly of rounded granular cells, rather larger than leucocytes, and sometimes mixed with small spindle cells.

In some of my sections bundles of spindle-celled tissue can be seen occupying extensive areas. A delicate small-meshed fibrillar intercellular substance is visible in many parts, after removal of the contained cells. Numerous blood-vessels can be seen here and there in the sections, mostly divided transversely, and embedded in the cellular mass. There is no fibrous alveolar stroma.

Taking everything into consideration, therefore, I am decidedly of the opinion that this growth is not of a cancerous nature, but sarcomatous. It is, I think, a mistake to regard such growths as highly malignant; they very rarely give rise to secondary deposits.

March 6th, 1883.

Report of the Morbid Growths Committee on Mr. Roger Williams' tumour in a diverticulum of the urinary bladder.—From the appearance of some of the sections furnished us by Mr. Williams, we found it very difficult to be certain of the precise nature of this tumour. The growth consisted of coarse fibres so loosely held together as to form a meshwork, which in some parts was infiltrated with small round cells like leucocytes. In other sections cells of a larger size and less regular shape were present, and in one section composed the chief part of the growth. The arrangement of these larger cells was not that of the cells in carcinoma, nor were the cells themselves such as we should expect to find in carcinoma of the bladder.

We agree with the opinion expressed by the author that the disease is a sarcoma which has been inflamed. Although the cells are very irregular in size and shape, it may be classed as a round-celled sarcoma on account of the large number of round and ovoid cells which are present. Part, at least, of the fibrous tissue is probably due to organisation of the constituents of the tumour; part, perhaps, to past inflammation.

The naked-eye characters of the disease are unquestionably those of malignant disease, not of simple fibrous tumour. Thus, the tumours are ill-defined, ragged, and broken down, and the walls of the bladder are much thickened and infiltrated by the tumour.

JAMES F. GOODHART.
HENRY T. BUTLIN.

---

9. *Villous sarcoma of the bladder.*

By W. ROGER WILLIAMS.

THE only history I have been able to obtain of this specimen (No 44 of the bladder series in the Middlesex Hospital Museum), is that it was removed from the body of a man, aged 60, who died in the hospital.

In the recent state the bladder was filled with coagula, but its mucous membrane appeared healthy. There were no secondary deposits.

The prostate was slightly hypertrophied.

The bladder has been laid open in front exposing a quasi-solid growth about the size and shape of a hen's egg, fluffy on the surface, attached to the base of the bladder by its larger extremity, close to the orifice of the right ureter; judging from the dilated stump of the latter now remaining its patency must have been considerably interfered with. Though the growth has a solid appearance, on manipulation it proves to be of a soft, spongy texture, except at the base where there is a collection of firm solid substance.

Sections of the soft part show, under the microscope, complicated branching processes entire or cut in various planes. These villosities are covered by a large-celled spheroidal epithelium; within they contain a core of blood-vessels, supported by strands of spindle-celled and loose fibrous tissue, infiltrated with small round cells resembling leucocytes. This small-celled tissue is most abundant immediately beneath the lining epithelium of the villi, and at their extremities; in the latter position it almost entirely supercedes the other structures. The solid base of the growth is almost entirely composed of a similar small-celled tissue. No muscle-cells were detected, nor were there any epithelial ingrowths or nests such as occur in cancerous growths of this kind. This growth differs from a simple papilloma in that its whole structure is infiltrated with small round cells, of which its solid base is composed.

It may be supposed to have originated in a co-incident proliferation of the submucous connective and vascular tissues.

March 6th, 1883.

---

10. *Multiple growths in the bladder.*

By JOHN H. MORGAN.

THE bladder exhibited was removed from a well-built, muscular man, aged 65, who had been an inmate of Charing Cross Hospital in May last, having come from Great Wakering, in Essex, to seek relief from his frequent micturition and hæmaturia. The

symptoms had commenced fifteen years previously with pains of a cutting nature, which were referred to the region of the neck of the bladder. Later on micturition had become frequent, and blood was constantly mixed with the urine in large quantities. He came of healthy parents, and he had, previously to these symptoms, himself enjoyed good health, and was of temperate habits. He stated that he had during the last few years occasionally passed gravel, pieces sometimes coming away with the urine of the size of wheat grains.

During his stay in hospital he was for the most part kept in bed, and at no time was there any calculous matter passed with the urine. He required to micturate frequently during the day, the intervals varying from two hours to five or ten minutes. Movements such as walking about the ward increased the frequency, and gave rise to some pain which was not, however, at any time excessive. The amount of blood passed varied greatly, and bore no constant relation to any symptom or cause, the urine at one time being bright scarlet, at others so nearly natural in colour that the presence of blood could only be detected by the aid of the microscope. It was, however, constantly present to some amount, and when the quantity passed was large there were frequently found masses of flocculent material which proved on examination to be decolourised clot; no characteristic epithelial cells could be discovered.

On sounding no calculus was detected, but the sensation was given of a soft uneven mass lying at the posterior part of the bladder. No further information on this subject was gained by rectal examination, but the prostate was found to be somewhat hypertrophied.

On May 11th I performed the operation which has lately been advocated by Sir H. Thompson, and passed my left forefinger through a small wound in the middle line and a little above the anus into the urethra, which was opened just in front of the prostate. With the assistance of my right hand on the abdomen I was enabled to explore the whole of the interior of the bladder, and found a quantity of soft velvety growths springing from the posterior wall and generally diffused, but one large mass could be felt separate and springing from a pedicle a little above the rest of the growth. This was grasped between the blades of a lithotrite, and removed through the incision. This tumour was of the size

and shape of a filbert, and in structure consisted of a rather contracted pedicle, from which sprang innumerable branchlets which were again subdivided into small villous prolongations very like those of the chorion.

The patient made a good recovery, and at the end of a fortnight returned home at his own request. He remained very much better for some time, the urine being comparatively free from blood and requiring to be passed only once in two or three hours. At the end of two months, however, the former symptoms began to return and gradually increased in severity until he died much reduced by hæmorrhage in November last, six months after the operation was performed. Dr. Raper, of Great Wakering, attended the patient after his return home, and to him I am indebted for the trouble which he took to obtain leave to examine the bladder and to forward it to me.

It will be seen that the prostate is moderately enlarged, and that in the trigone and about the orifices of the ureters are several masses of new growth. Those nearest to the commencement of the urethra have a large broad base, and consist of aggregated tufts of villi, whilst other growths spring from various parts of the mucous membrane of the bladder, and are all more or less pedunculated. Of these isolated tumours several can be seen in the specimen, but many more existed during life; but their attachment was so slight and easily broken down that they fell off in the course of their conveyance to London. They are indiscriminately scattered over the surface of the interior of the viscus, and in size resemble a small almond, while to the touch they gave the sensation of soft, wet velvet. The walls of the bladder are not much hypertrophied, and the ureters at their entrance to the organ were only moderately dilated.

The consent to any examination was most reluctantly given, and therefore no other parts could be removed, and, what is to be regretted still more is that the urethra has been divided just in front of the prostate, and does not show the incision made at the operation.

Looking to the fact that there was but one tumour which could be felt at the time of the operation, and that by its removal the symptoms which had previously existed were kept in abeyance for some six weeks, it is fair to presume that the tumours which are seen to be so numerous in the specimen have for the most part

grown in the interval between the operation and the patient's death, the larger mass at the trigone being doubtless a further development of that velvety condition of mucous membrane which was felt at the operation. In another case I should certainly not leave such a condition without dealing with it by scraping away the redundant epithelium with a sharp spoon, or swabbing it with some strong solution of perchloride of iron, both of which modes of treatment have been recommended.

At a recent meeting of the Royal Medical and Chirurgical Society Sir H. Thompson stated that some of the tumours which he had removed under circumstances similar to those of the present case proved upon examination to be fibromata. The tumours were, however, all single, and, so far as related, have not been followed by any recurrence. In the present instance the major part of the growth is situated in the region of the trigone, and to the naked eye gives all the appearance of a papilloma. Mr. Stanley Boyd has kindly made sections of some of the scattered growths, but owing to the length of time during which they were macerated in spirit before being cut, the epithelium has been so far washed out of them as to make it difficult to state positively their exact microscopical structure. In some spaces, however, the sections show the characteristic disposition of the elements, and there are seen numerous thin-walled vessels ramifying and branching off into various parts. Upon these lie, without the interposition of any basement membrane, layers of epithelial cells of an indistinct columnar type, and generally about three deep on the surface of the villi. Polygonal or rounded spaces are enclosed by the vessels in which lie cells of an identical character to those on the free margins. In some of these the epithelial cells have been washed out, leaving almost empty spaces. Towards the deeper parts of the tumour the epithelial elements are more densely aggregated, and occasional bundles of fibrous tissue are seen, with connective-tissue cells intermixed with those of epithelium. The nature of the epithelial cells is everywhere homologous, which establishes the character of the growth as a papilloma.

I have to acknowledge the kindness of Mr. Boyd in preparing with much care the sections which are shown.

May 15th, 1883.

11. *Epithelioma of the bladder, from a case of hæmaturia.*

By W. A. Berridge.

The patient first began to pass blood in the summer of 1880. For some months he only passed it at night, and not in the day. He recovered for a time, but in the summer of 1881 the hæmaturia returned. He was treated in the Reigate and Red Hill Cottage Hospital, and also in the London Hospital under Mr. Waren Tay, but the hæmaturia persisted, although he returned to work. He was only laid up a week at the last. He died in great pain July 31st, 1882.

The bladder was removed next day, and a ragged ulcerating surface, three inches in diameter, was found in the base of the bladder, with raised uneven edges, and from this the hæmorrhage had come. There was nothing that could have been removed by operation. The prostate was healthy, and not enlarged. The right kidney was pale and fatty; the left venously congested. The body was well nourished, the peritoneal surface of the bladder being covered with fat.

Mr. Mansell Moullin made a microscopical examination, and reports: "There is no doubt it is malignant . . . There was the most unmistakable ingrowth of carcinomatous type, with large epithelioid cells, into the submucous tissue, and even between the muscular fasciculi . . . I should class it as an example of villous epithelioma of the bladder; the centre was really an epitheliomatous ulcer. *January 16th*, 1883.

---

12. *Adeno-sarcoma of testis with secondary growths in the viscera, occurring in a case of cardiac malformation.*

By Victor Horsley, B.S.

The following case in which a tumour of the testicle was removed with subsequent death from the rapid growth of secondary tumours in the abdominal and thoracic viscera is interesting, not

only on account of the nature of the new growth, but also from the coexistence of several congenital defects of structure. Though solitary cases of this kind cannot be expected to throw much light on such an obscure subject as the etiology of new growths, it is believed that the record of the following facts sufficiently justifies their publication, as adding to our knowledge on this point.

As regards the theoretical origin of sarcomata and the simpler tumours of the connective tissue type there are now two views before the profession, viz. one which imagines foci of tissue possessing still their embryonic nature to remain undeveloped in various organs and tissues from which the neoplasm forms, while, according to the other, adult tissue under certain circumstances quickly assumes active growth, resulting in the production of a tumour. The first view, supported by the experiments of Cohnheim and Leopold, would seem to be completely borne out by the following details; for in this case the subject was a slightly grown man below middle age (31), in whom there existed the following defects of development, viz. patent foramen ovale with partial atresia of the pulmonary orifice, congenital hernia, mal-development of the right testicle, and marked lobulation of kidneys and spleen. It is not necessary to enter here upon the question either as to the causation of the cardiac malformation, or the causative relation which this may bear to the other embryonic conditions; it suffices to show that in this case in all probability there existed (more especially in the genito-urinary organs) here and there tissues which had not matured and still preserved potentiality of wide development. In connection with this point and with that of so-called traumatic malignancy, it will be seen that the growth commenced locally after a severe blow.

But before describing the new growth the condition of the heart is sufficiently interesting to call for more special notice. On looking up the records in the Society's 'Transactions' of previously noted cases of patent foramen ovale with varying conditions of the valves on the right side of the heart, venous pulse is mentioned in two only and tracings of the pulsation in none. Unfortunately there has not been time to search the continental journals, and the only tracings of the heart beat in this or like conditions that I am aware of in British literature are in a paper in the 'Edinburgh Medical Journal' by my friend Dr. Roy. These, however, could not for several reasons be employed in explaining the following curves, so that the

latter are here produced for comparison with others that may be made in future cases.

In order that the case should be complete, those facts in the history which bear upon the etiology and mode of growth of the tumour are briefly appended.

Patient was a thin, pale man, aged 31, about five feet four inches high, slight build, and of dark complexion.

Personal history.—Had been a carpenter all his life; never strong; pleurisy twice; gonorrhœa once; never cyanosed; no syphilis; right oblique inguinal hernia (congenital).

Family history good; no hereditary disease; father had a right (inguinal?) hernia.

History of present illness.—Patient was kicked with the knee on the left testicle eighteen months ago. He suffered intense pain at the time. The testicle swelled a little, but he took no notice of it for four days, at the end of which time a constant aching pain began in it, and the organ gradually swelled. He applied hot fomentations and ointments. The testicle increased more rapidly during the last two months.

Present state.—The left side of the scrotum was occupied by a firm oval tumour reaching up to the external abdominal ring. Tumour elastic, a little tender, gives testicular sensation in the lowest part of the posterior surface. No enlargement of lymphatic glands nor other tumour. Right testicle about one third normal size. The lungs and abdominal viscera appeared to be quite normal.

Vascular system. Arterial.—Area of cardiac dulness extended to the centres of the right costal cartilages. Apex beat normal. The first sound was accompanied by a rough blowing murmur heard loudest at the third left costal cartilage, but well also up and down the sternum. Pulse 80. Sphygmographic tracings showed that the ventricle emptied itself rather suddenly, and that the dicrotic wave was but slightly marked.

Venous.—There was marked venous pulse extending as far as to just below the elbows (in the ulnar veins), the only vein which did not show it being the right external jugular. The venous pulse alternated with the radial. On the right side of the neck there was noticed a powerful double pulsation behind the sterno-mastoid, that muscle being pushed forward at each beat. The pulsation was soon found to be produced by two series of beats

alternating with one another, and that one series was synchronous with the radial pulse, or rather a little before it.

The accompanying diagram shows the tracing A obtained (by Marey's tambour with the quick rate of the clock) from this pulsation. Tracing B is the radial pulse taken with the same instrument.

WOODCUT 5.



Tracings of actual curves.

It will be seen at once that curve A consists of the carotid beat C with a second wave (J) intervening too late and being too large to be confounded with the dicrotic wave. In the absence of more certain data for fixing the commencement of auricular systole in man, it would be hazardous to assume that this second wave (which appears certainly to be the tracing of the venous pulse in the internal jugular) is produced by the auricular systole, and yet this would seem the only possible explanation.

From the tracing B of the radial pulse and the sphygmographic tracing, it is seen that, at any rate, the second wave is certainly not dicrotic, therefore certainly not arterial. Its time-rate showed, of course, that it was not respiratory, and it is not necessary to add the respiratory tracing.

This part of the case will be best concluded by the *post-mortem* appearances of the heart.

Pericardium normal.

Right side.—Auricular appendix short and wide. Wall of auricle thick, averaging about a quarter of an inch. No trace of The-

besian valve. Venæ cavæ normal. Tricuspid orifice somewhat smaller than usual. Foramen ovale found to be patent. When spread out the opening had a roundish outline interrupted by a median trabecula of connective tissue covered by endocardium, and a smaller one in front. The diameter of the foramen was one and a quarter inches. Tricuspid valve much thickened, puckered, and thrown into folds. Chordæ tendineæ shortened and thickened, and the posterior segment attached to the septum ventriculorum by small cords extending up as far as the auriculo-ventricular ring. The musculi papillares were united, and the atrium of the pulmonary artery was even narrowed by some of the bands. Ductus arteriosus normal. Pulmonary artery from the outside showed a depression on the anterior surface. The pulmonary valves were united into a fibrous cone, the right segment of which was closely adherent to the wall of the artery. The remaining segments, anterior and posterior, had each a sinus of Valsalva five eighths of an inch deep, and were united to one another by their contiguous margins. The line of junction of the anterior and external segments was prolonged down beneath the endocardium to the atrium.

No abnormality could be found in the distribution of any of the large vessels.

The tumour of the testicle consisted of an oval mass about three inches long and two and a half inches broad, formed by extensive cystic disease of the body of the testis, surrounded by the thickened tunica albuginea. On the anterior surface was the tunica vaginalis, containing a small quantity of turbid straw-coloured serous fluid. In the upper third of the tumour was found a ragged cavity about one and a half inches in diameter, containing a dirty-brown, thick fluid, with yellowish curdy masses floating in it, evidently masses of corpuscles, &c., undergoing fatty degeneration. The fluid was brown from altered blood-corpuscles and particles of hæmatin.

The vas deferens was found to be considerably thickened at the time of operation, so as to be half a diameter broader than normal, and the vessel was of a pale yellowish-white colour. An additional inch was removed at the time of operation, and the upper end appeared normal.

The tunica albuginea, described above as thickened, presented the ordinary appearance of white fibrous tissue with extensive new growth of the same on its inner surface. This new-formed fibrous tissue extended into the tumour between the cysts.

The tumour substance occupying the position of the body of the testis was made up of a stroma forming the walls of numerous cystic cavities, which, for the most part, were oval or round, but many were elongated, and even forked. They varied in size from those only to be seen with a low power up to the cavity mentioned above.

When examined by the microscope the stroma was found to vary from fine fibrous tissue to a soft sarcoma tissue, composed of round and irregular corpuscles, varying in size, but of the average breadth of red blood-corpuscles, each with a deeply staining nucleus and protoplasmic body.

The cystic cavities, when very small, consisted simply of spaces in the stroma lined by columnar epithelium; as they increased in size the epithelium became flatter until in the largest cysts it was broader than tall. In one medium-sized cavity a few goblet-cells could be seen.

The cysts contained a thick (clear when the cysts were small) mucous fluid (mucin precipitated from it by H_2O, alcohol, &c.), but this in the older cysts was frequently mixed with blood and the products of fatty degeneration of the epithelium.

The next point of greatest importance clinically is the fact that in this, the primary growth, there were numerous hæmorrhages, not only (as just mentioned) into the cysts, but also into the sarcomatous part of the stroma.

Now, in the secondary growths in the liver and lung, out of some fifty sections there was practically none of the original cystic formation, but the masses consisted of the same sarcoma tissue as that described above, into which hæmorrhage had taken place. As these growths were all precisely similar, a few words will describe their microscopical appearances before mentioning the macroscopic.

In the lung the nodules were composed simply of the same sarcoma tissue, each nodule being surrounded by a zone of broncho-pneumonia, and the pleura outside being covered with recent adhesions. The nodules were riddled with hæmorrhagic foci.

In the liver the additional fact of commencing cirrhosis was noted, with apparently increase in number and size of the branches of the portal vein, while in the growing connective tissue were seen the elongated bile-ducts. The increase in vascularity was most marked in the neighbourhood of the masses of new growth. The same appearances were met with here as in the lung, except that

in the liver there was extremely little sarcoma tissue to be found, the cavities filled with blood, and tumour *débris* being frequently walled round by the remains of Glisson's capsule.

The secondary growths were found *post mortem* to be situated as follows:

In the abdomen the liver-substance was riddled with masses of different sizes; from one of the largest in the anterior margin hæmorrhage into the peritoneal cavity had taken place, which caused death from syncope. Beneath the right lobe, above the duodenum, was situated a large mass, which pressed upon the bile-duct, but left the other vessels uninjured, though in contact.

There was a small nodule situated in the muscular wall of the bladder on its outer surface, just below the left obturator artery.

Remaining abdominal viscera healthy, but both spleen and kidneys were lobulated; while the right testicle was very small—two thirds normal size—but when microscoped did not show any embryonic tissue. No connection could be made out between the growths and the venous system, and the lymph glands were dark, but normal in appearance and consistency.

In the thorax the growth was present in the upper lobe of the right lung as a round mass, one and a third inch in diameter, and two small nodules in the middle and lower lobes respectively. In the left lung there were also a few subpleural nodules.

It will thus be seen that no channel of communication could be shown to connect the testis tumour and the secondary growths.

Summing up the case, it would seem that we had a man in whom the potentiality of developing sarcoma tissue was considerable, and that this was started into activity by traumatism, resulting in the production of growths throughout the abdominal viscera. (It is obvious, however, that the small growths in the lung were probably secondary to those in the liver.) *April 17th*, 1883.

13. *Case of testicle in the perinæum, with congenital inguinal hernia and acute hydrocele.*

By W. Roger Williams.

The subject of this disease, a child two years old, was admitted into the Portsmouth Hospital on September 15th, 1882, under the care of Dr. Lloyd Owen. For the report of the case and the wax model illustrating it I am indebted to my brother, Mr. J. Alexander Williams, house surgeon to the Portsmouth Hospital.

On admission, a large sausage-shaped swelling was observed in the right inguinal region, extending downwards into the perineum to within half an inch of the anus.

At the junction of its upper two thirds with its lower third there was an obvious constriction. The upper portion was tense, resonant, and presented the appearance of an ordinary inguinal hernia; the lower was of ovoid shape, dull, fluctuating, and translucent; it evidently contained fluid.

The scrotum was well formed and symmetrical. The left testicle seemed normal in every respect, but the right was absent from its side of the scrotum, and its whereabouts could not then be ascertained. The examination caused much pain. According to the mother's account, there had been noticed since birth, absence of the right testicle, and a movable lump in the right inguinal region, about the size of a bantam's egg, which occasionally slipped up out of sight. A doctor had told her that the child was ruptured.

He had previously enjoyed good health, but was of a fretful disposition.

Shortly before the child's admission into the hospital his cries caused the mother to examine the swelling in the groin. Finding this unusually large and tender, she became alarmed, and brought him to the hospital. She said she was not aware of the child having received any injury in the part.

Such being the case chloroform was administered, and an attempt was made to reduce the upper part of the swelling. As this failed, the lower part of it was punctured, and about an ounce of straw-coloured flaky fluid, evidently of inflammatory origin, for it coagulated shortly afterwards, was evacuated. This caused considerable reduction of the swelling, and on gentle manipulation its upper

part was steadily reduced with distinct gurgling. A swelling in the perineum, not of great size, was all that then remained.

Next morning the skin at this spot was red, and a hard, very tender lump, about the size of a bantam's egg, could be felt there, which was plainly the displaced and inflamed testicle. The thickened spermatic cord could be traced up from it to the external abdominal ring.

The application of ice, after a few days, caused considerable reduction in the size of the swelling, and it became less tender. Neither the hernia nor the hydrocele subsequently returned whilst the child was under treatment. In this condition he left the hospital on October 1st, and nothing has since been heard of him.

This form of congenital displacement is rare; and the complications existing give additional interest to the case. The tunica vaginalis was evidently perfectly formed, and completely separated from the funicular process of peritoneum, which, however, was patent above that point, and contained a hernial protrusion. The latter no doubt formed the "movable lump" occasionally noticed by the mother in the child's groin ever since birth.

Probably shortly before admission the child received some injury to the displaced testicle, which caused the orchitis and the inflammatory effusion into the tunica vaginalis, for which he was brought to the hospital. *November 21st*, 1882.

---

14. *Incipient cystic disease of the parovarium and broad ligament.*

By Alban Doran.

[With Plate XI.]

These specimens are brought forward with the intention of throwing some light on the earlier stages of all cystic tumours of the uterine appendages that are not truly ovarian nor partly ovarian.

As the parovarium plays such a prominent part in the pathology of cystic tumours of the broad ligament, it is better that an actual

dissection of that organ be first examined before any researches are made for the purpose of tracing the origin of minute cysts in its vicinity. We have trusted far too much to diagrams and to second-hand information for our knowledge of the parovarium. It is not sufficient for us to think of the parovarium as something also termed the organ of Rosenmüller or epioophoron; some obscure, insignificant structure beautifully figured in two or three foreign works on anatomy, so that no further notice need be taken of so "worked-out" a subject. It is equally unscientific to despise it as a "relic." Every part of the human body is a relic of what once was embryonic; most organs develop, it is true, and increase in functional importance, whilst the parovarium does not normally develop in the adult, and its functions, if there be any, are unknown. To the pathologist the parovarium should be of great interest, since, from or near it, cysts of the simplest and of the most complicated type may take their origin, and undoubtedly some such cysts actually arise from it, whilst others are merely associated with the parovarium by accidental proximity. To procure a good pair of uterine appendages suitable for the dissection of the parovarium, it is best to remove the internal organs of a young adult virgin who has not suffered during life from any disease of the pelvic viscera that tends to cause thickening of the broad ligament or long-standing congestion of its vessels. A still more suitable opportunity for examining the parovarium occurs when a multilocular glandular (and not papillary) cyst of the ovary is removed, provided that the operation be uncomplicated; then, if no local inflammatory processes have existed, the broad ligament will be found lying, with the Fallopian tube, upon the cyst, very much stretched and thinner and clearer than in a healthy subject. The parovarium will be plainly detected on holding the tube and the ligament up to the light. If, however, the specimen be preserved in spirit, the tissues of the ligament become semi-opaque and obscure the view of the parovarium. It is necessary, therefore, to dissect off the posterior layer of the broad ligament at once. This can be readily effected if the tube and ligament, with a small portion of ovarian tissue, be pinned on a flat piece of cork and placed in a saucer filled with cold water. When the entire outline of the parovarium is exposed methylated spirit must be added; in a few hours the tubes of that structure will be sufficiently tough for further dissection.

This specimen[1] was thus prepared. The vertical tubes of the parovarium are plainly to be seen, and not only the horizontal canal into which they run is exposed, but that canal can be traced into a white fibrous band running in the direction of the uterus. This band is the "duct of Gaertner." In fact, this specimen demonstrates all the remains of the Wolffian body, excepting the commencement of the vertical tubes, which are lost in the hilum of the ovary, and the end of its duct, which is lost in the walls of the uterus. Some of the innermost vertical tubes that are generally obliterated are to be traced in this second specimen (fig. 1, *w r*). They may, according to Coblenz,[2] become the seat of those papillary cysts sometimes found between the parovarium and the uterus.

The second specimen (fig. 1),[3] dissected in the same manner, is interesting as showing several small cysts, all in different parts of the broad ligament and its vicinity. The long pedunculated "hydatid of Morgagni' (*h m*) represents the blind extremity of Müller's duct, which in the process of development breaks open near that extremity, and develops the Fallopian fimbriæ along the borders of the line of dehiscence.[4] At the outer extremity of the horizontal tube of the parovarium is a very similar cystic body (*t c*) also pedunculated. This terminal cyst of the parovarium, which is lined with cells that are endothelial in character and not with ciliated epithelium, is occasionally non-pedunculated, forcing apart the layers of the broad ligament as it increases in size. As a rule, however, it hangs from the ligament by a pedicle. Since pedicles

[1] The preparation is in the Museum of the Royal College of Surgeons. As it does not illustrate a morbid condition, I have not figured it. As a rule, the fibrous relic of Gaertner's duct is not so distinct as in this particular specimen.

[2] "Zur Genese und Entwickelung von Kystomen im Bereiche der inneren weiblichen Sexualorgane und ihre Behandlung," 'Virchow's Archiv,' Band lxxxiv.

[3] It should be clearly understood that the uterine appendages are represented in this sketch as in their conventional and not in their correct position and relations, since the different structures could not be well demonstrated if they were drawn in their normal position, as described by Professor His, of Leipzig, in the 'Archiv für Anatomie und Physiologie,' 1881.

[4] The term "hydatid of Morgagni" is exclusively employed by some anatomists to signify the well-known pedunculated cyst found in connection with the testicle; this cyst is likewise believed to be a vestigial relic of the uppermost extremity of Müller's duct, the lower portion of which is represented in the adult male by the tissue round the sinus pocularis in the prostatic part of the urethra. The use of the name "hydatid of Morgagni" for homologous bodies in both sexes is to be encouraged, being scientifically correct.

of this type are poorly supplied with blood and readily become twisted, neither this terminal cyst, when pedunculated, nor the hydatid of Morgagni ever attain large dimensions.

On one of the anterior vertical tubes is a minute cyst (fig. 1, *p c*), and close to the point of entry of an adjacent tube into the tissue of the hilum of the ovary is a similar cyst, partly embedded in the ovarian tissue. Far away from the parovarium are some minute cysts (*b c*), adherent to the anterior layer of the broad ligament. They are more plainly visible anteriorly, through the ligament, when the specimen is fresh. When developed beneath the reflection of peritoneum on the upper border of the Fallopian tube they are often pedunculated (fig. 2), as they can more readily push the serous membrane upwards than insinuate themselves between its layers below the tube. In some cases these non-parovarian cysts become pedunculated, even when they are developed in the folds of the broad ligament below the tube, as in this specimen, where minute cysts project from the ligament above the parovarium (fig. 3). As a rule, however, these cysts, when they increase in size, push apart the layers of the broad ligament. They are lined with a layer of endothelium, and never bear ciliated epithelium nor solid growths. It is from a cyst of this type, free from the parovarian tubes, that is developed the cyst commonly but erroneously termed "parovarian," with its thin, transparent wall, its single cavity lined with flat or low columnar epithelium, and its clear, watery contents. This non-parovarian cyst often arises close to the ovary, under the ovarian fimbria of the tube (fig. 5); as it develops it pushes the parovarium inwards, and rises, between the folds of the ligament, as high as the tube, which becomes stretched to an indefinite extent. The entire parovarium may often be found outside the wall of such a cyst posteriorly. The terminal cyst of the parovarium, which bears a layer of endothelium, may, as I have already observed, become enlarged without developing a peduncle. It then forces the layers of the broad ligament apart, and becomes a large unilocular cyst that is truly parovarian. As it enlarges it first comes in contact with the ovarian fimbria of the tube, which it stretches to an indefinite extent.

We will now take into further consideration the cysts in connection with the vertical tubes of the parovarium. These tubes are lined with ciliated epithelium; so are the walls of certain cysts in the ovary and the broad ligament. Such cysts have a tendency to

DESCRIPTION OF PLATE XI.

Illustrating Mr. Doran's paper upon Cysts in Relation to the Broad Ligament From drawings by Mr. Doran. (Page 170.)

FIG. 1.—The right uterine appendages, showing several varieties of cyst. The posterior layer of the broad ligament has been partly removed to expose the parovarium.

t. c. Terminal pedunculated cyst of the horizontal tube of the parovarium. *p. c.* Cyst developed from the side of a vertical tube of the parovarium. Below the outermost tube a small cyst projects from the hilum of the ovary. *W. r.* Relics of Wolffian tubes, internal to the parovarium (no trace of Gaertner's duct exists in this specimen). *H. m.* Hydatid of Morgagni, with an unusually long pedicle. *b. c.* Non-pedunculated broad ligament cyst, not connected with the parovarium or tube; two other cysts lie close to the tube, under the posterior layer of the broad ligament.

FIG. 2.—A pedunculated cyst developed under the broad ligament at its point of reflection over the upper portion of the Fallopian tube. The cyst is only apparently connected with the tube.

FIG. 3.—Portion of a left tube and broad ligament. The tube bears a true accessory fimbria some distance behind its extremity. Two pedunculated cysts and one that is sessile, project from under the posterior layer of the broad ligament. They are all separate from the parovarium.

FIG. 4.—The fimbriated extremity of the Fallopian tube. The hydatid of Morgagni has a very long, flat pedicle, bearing a fringed process.

FIG. 5.—A thin-walled cyst lying between the outer extremity of an ovary and the end of the ovarian fimbria of the tube, which crosses the cyst. (Twice the natural size.)

Fig. 1.

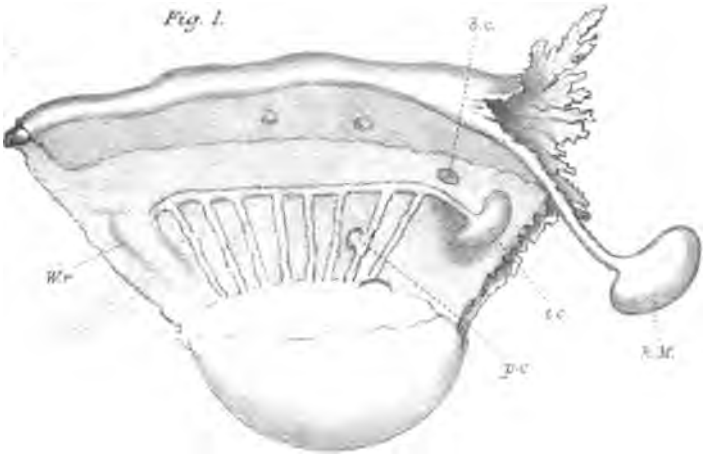

Fig. 2.

Fig. 3.

Fig. 4.

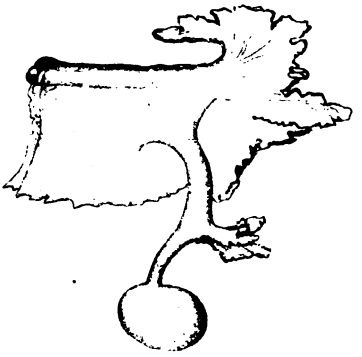

Fig. 5.

develop solid papillary growths from their inner walls, and usually contain a clear watery fluid; when they have grown to a large volume the epithelium generally ceases to be ciliated. When they commence in the ovary they first appear in the tissue of the hilum, where relics of the Wolffian body exist, and grow to some size before involving the stroma of the parenchyma of the ovary; on the other hand, they tend to grow into the broad ligament, forcing apart its layers. I exhibited specimens of incipient papillary cysts of the ovary, illustrating their manner of growth, at the Pathological Society in the course of last session.[1]

In that communication to the Society I discussed at length the question of mixed papillary and glandular cysts in ovarian tumours. As Wolffian elements extend into the tissue of the parenchyma of the ovary, and, on the other hand, follicles may grow into the tissue of the hilum, these mixed growths are readily accounted for. Even the typical glandular ovarian cysts may, in rare cases, push into the hilum, and force apart the layers of the broad ligament. But histologically it is only the ovarian cysts with papillary contents that need consideration in discussing cysts that spring from the parovarium. No case of multilocular cystic disease of the broad ligament, with glandular intracystic growths and no implication of the ovary, has ever been described, but large papillary cysts of the broad ligament, entirely free from the ovary, which remains healthy, yet presenting all the characters of similar ovarian cysts, are now well known to pathologists. The incipient stage of such cysts may be seen in my second specimen springing from a vertical tube of the parovarium (fig. 1, *p c*); the cyst below it, partly in the ovarian tissue, would be still more likely to develop, under unfavorable circumstances, into a papillary cyst. From the generally obliterated tubes, of which a faint indication may be found on dissection (fig. 1, *w r*), similar cysts may develop between the parovarium and the uterus.

These cysts with papillary contents spread over the broad ligament with great rapidity. If once a cyst-wall bursts, papillary masses sprout freely into the peritoneal cavity and soon grow over the tube, the fundus uteri, and the visceral and parietal peritoneum. In these spreading cases I have found perfect cysts, filled with the characteristic growth, on the peritoneum of Douglas's pouch, far from ovarian or parovarian tissue. It is, from this fact,

[1] 'Trans. Path. Soc.,' vol. xxxii, p. 33.

easy to understand how similar papillary cysts may also be found between the layers of the broad ligament, at the site of the above-described minute cysts of non-parovarian origin (fig. 1, *b c*); but whether, in such cases, these minute cysts themselves receive some morbid stimulus which causes their unperforated lining membrane to produce papillary growths, I cannot say, only I doubt this possibility. In mixed glandular and papillary multilocular tumours of the ovary, each loculus generally produces one of the two forms of solid growth alone, excepting when a papillary mass perforates a compartment loaded with purely glandular growths.

These papillary cysts of the broad ligament are, after all, not very common, whilst the small cysts, bulging from the vertical tubes of the parovarium, are far from rare. This is not to be wondered at, for the chance of any one such minute cyst ever growing large is very slight. The parovarian tubes, and everything associated with them, tend to atrophy and not to enlarge; it is unusual to find one single tube thoroughly patent in an adult, and its lumen is always more or less choked with broken-down epithelium. The cavities of cysts directly connected with the tubes generally become filled with a similar material, and all growth ceases, as a rule, before such cysts attain the size of a pea.

It is the presence of papillary growths, springing from the inner walls, that is the essential feature of cysts derived from the vertical tubes of the parovarium and their prolongation into the tissue of the ovarian hilum. Too much importance must not be placed on the presence or absence of ciliated epithelium. Dr. Fischel, in a paper, "Ueber Parovarialcysten und parovarielle Kystome," in the fifteenth volume of the 'Archiv für Gynaekologie,' discusses this epithelial question at great length. He admits that on the inner walls of many of these cysts with papillary growths, ciliated cells are absent, or only found in places, and is diffident with regard to Klebs's opinion that the ciliated epithelium may become changed into other forms, nor does he fully accept Spiegelberg's theory that the pressure of the fluid contents can flatten ciliated epithelium till it loses its cilia and becomes pavement epithelium. Dr. Fischel is more inclined to believe that when ciliated epithelium is not found under these circumstances, the simpler type that replaces it was never ciliated at all. Waldeyer has shown that the epithelium of the Wolffian body is not originally ciliated; the simpler non-ciliated epithelial cells covering the papillæ in these cysts represent

this earlier type of Wolffian epithelium. On the other hand, it must be clearly understood that the inner lining of all the other cysts described in this paper is endothelial—that is, made up of a single layer of flattened epithelial cells; this I have often verified by nitrate of silver staining. The usual condition of a vertical tube of the adult parovarium renders microscopic examination of its epithelium very difficult, but I have far oftener found flattened or simple columnar cells than ciliated epithelium. For the reasons just given, I believe it to be better to trust to the anatomical position of cysts of the broad ligament, as seen by the naked eye in their earliest visible stage, rather than to any blind reliance on the presence or absence of a kind of epithelium not always found in the very structure on which the whole question depends.

It might be contended that some of the minute non-parovarian cysts are developed from Müller's duct, which ultimately becomes the Fallopian tube. There is no evidence, however, that any true Fallopian cyst has ever been found, excepting such as are developed within its canal from obstruction, papillary growths, or extra-uterine gestation. The minute cysts found on the upper border of the tube, under the serous membrane, are quite free from the tube and identical in character with the non-parovarian broad-ligament cysts found below the tube. The small shreds or tags that often project from the upper border of the tube, and are duly covered with a layer of serous membrane, are not cysts but abnormal fimbriæ (fig. 3). They result from an exaggeration of the process of dehiscence which normally takes place near the extremity of Müller's duct, when the orifice of the tube and its fimbriæ are developed. If the split be prolonged backwards, a fringe may be formed some distance behind the normal fimbriæ, as in this specimen. But a cyst could hardly be developed in the course of this process, excepting the hydatid of Morgagni, which is almost constant, as the dehiscence never extends to the extremity of Müller's duct, and that extremity always tends to close at the point of dehiscence, so as to become at once a cyst hanging from the fimbriæ. The pedicle may be very long (fig. 1, *h m*), or even bear a second fimbria, as in this singular specimen (fig. 4). It often undergoes hypertrophy and elongation in cases of cystic disease of adjacent structures, or when chronic inflammation of the tube and ovary has existed for a prolonged period. In one case of long-standing suppuration of an ovarian cyst treated by excision, I found, when the entire cyst was ultimately removed,

that the pedicle of the hydatid was six inches long, although the hydatid itself was not a quarter of an inch in diameter.

October 17*th*, 1882.

---

15. *Pigmentation of the cervix uteri.*

By Robert Barnes, M.D.

Dr. Barnes exhibited the two lips of the vaginal portion of the cervix uteri removed from a Hindu woman, aged 50, on account of hypertrophic elongation. The part which had protruded beyond the vulva had become dry, as is usually observed, and on the dry skin-like part a patch of black pigment had formed, resembling the woman's skin; the parts of the mucous membrane which remained moist, which were partly enclosed in the vulva, remained of the ordinary rose colour.

Microscopical examination of the pigmented os uteri by Dr. Ewart.—A microscopical examination was made of a slice of the os uteri, including the pigmented and also part of the unpigmented surface.

Under a low power the leading characteristics of healthy skin are recognisable in the specimen. The external surface is free from papillation, but presents a broad wavyness or corrugation (probably due to the shrinking of the specimen in spirit.)

The horny layer is thin and has become separated into two or three fine horizontal laminæ; here and there the homogeneous epidermal substance has acquired a distinct staining with logwood.

The rete Malpighi is well furnished with closely packed cells, indistinguishable from those of the normal *mucous layer*. Its lowermost boundary is formed by a layer of thin, vertical, pointed cells, abundantly provided with a rich brown pigment (excepting at the unpigmented extremity of the specimen).

Papillæ, deeper and more numerous in the *pigmented* area, project freely from the *corium* into the rete Malpighi, carrying vessels (obviously of new formation) which can be followed for some distance into the substance of the uterus. Several of the papillæ, hit

transversely by the section through their apex, form as many laminæ in the specimen, simulating gland ducts. But neither sweat glands nor hair follicles are discoverable.

In the unpigmented zone, where the vessels of new formation are fewer, a *corium* is, practically speaking, absent, the rete Malpighii abutting upon the dense structure of the uterine wall; but the pigmented portion is provided with a narrow clear space traversed by loose fibres, which gradually become denser and more largely intermixed with unstriped muscular elements towards the uterine tissue.

Examined under a higher power (No. 7 Hartnack) the pigment is seen to consist of deep brown granules filling the lowermost cells of the rete Malpighii, also thinly scattered throughout the mucous layer, and not altogether absent from the epidermis. The pigment particles appear to be contained within the nuclei of the cells of Malpighi, or to cling to the surface of the nucleus. In the horny layer they are arranged in fine striæ, in accordance with the flattened condition of the cells in this situation.

November 7th, 1882.

---

16. *Fibro-myoma of the uterus, becoming sarcomatous, with secondary growths in pleura, heart, and kidney.*

By David W. Finlay, M.D.

[With Plate X, figs. 1, 2, and 3.]

The patient from whom the specimen was removed was a single woman, aged 59, admitted into the Middlesex Hospital under my care on October 4th, 1882.

She first noticed a hard swelling in the lower part of her belly fifteen years since, but suffered no inconvenience from it until quite recently, when it had seemed to increase more rapidly in size. The catamenia ceased more than ten years ago, having been always normal, both as regards times of recurrence and quantity.

On admission, a tumour, which was hard, rounded, and prominent, was found occupying the lower part of the abdomen up to the level of the umbilicus. On either side of the umbilicus a small hard nodular mass was felt attached to the summit of the tumour.

On vaginal examination the os uteri was found low down, and pointing somewhat to the right.

The sound entered about the normal length. A small nodule was found beneath the skin in the second left intercostal space, and another in the back of the neck; the glands in the left groin were also slightly enlarged and hard.

Eight days after admission she was seized with great pain in the back and vomiting, the abdomen became distended and tender, and she died of peritonitis on October the 17th.

The following were the *post-mortem* appearances found twenty-one hours after death.

On opening the abdomen the great omentum and intestines were found glued together by recent lymph. The hypogastric and lower umbilical regions were occupied by a large tumour of globular form, and for the most part smooth, attached to the fundus of the uterus by a pedicle about an inch in width. It was adherent to numerous coils of intestine, and in separating it from these a part of the investing capsule on its posterior surface was ruptured, and gave exit to a quantity of blood-stained fluid. On the summit of the tumour were found the two nodular masses which had been felt through the abdominal wall during life, and between and behind these a part of the small intestine, to which the tumour was adherent, was penetrated by the growth, which appeared in the interior of the bowel as a rounded mass about the size of a sixpence.

The tumour, when removed, measured 6″ × 4½″, being about equal in size to a fœtal head.

On section its upper part was found to have undergone degeneration and softening, and consisted in great part of an irregular, ragged cavity, containing much soft *débris*. The lower half was comparatively firm, presenting the appearance of a fibroid, with here and there fleshy tracts of rather firm consistence. The whole was whitish in colour, and was surrounded by a distinct capsule.

At its lower part the growth had perforated the fundus of the bladder, appearing on the mucous surface as a small fungating mass. Behind and to the right side of the uterus was attached another tumour, about the size of a walnut, which on section presented the ordinary appearance of a uterine fibroid. The cervical canal of the uterus contained some very small polypi. The ovaries appeared normal.

At the base of the right lung and adherent to the diaphragm

DESCRIPTION OF PLATE X.

Figs. 1, 2, and 3.—Illustrating Dr. Finlay's case of Fibro-myoma of the Uterus becoming Sarcomatous. (Page 178.)

FIG. 1 represents a section of the growth under a low power. (× 50 diam.)
A. Refers to areas of round-cell growth. B. Refers to areas of spindle-cell growth. The section is also traversed by bands of fibro-myomatous tissue.

FIG. 2 represents a portion where an area of spindle-shaped cells closely adjoins a portion of the normal structure of the fibro-myoma. (× 420 diam.)

FIG. 3.—A portion of Fig. 1 (A *a*) showing round-cell growth, more highly magnified. (× 250 diam.)

From drawings by Dr. Finlay.

Figs. 4 and 5.—Illustrating Dr. Silcock's case of Phlegmonous Gastritis after Gastrostomy. (Page 90.)

mu. Mucous membrane.
sm. Swollen and infiltrated sub-mucous tissue.
mus. Muscular coat seen in section.
p. Roughened visceral peritoneum, which was adherent to the parietal peritoneum at the margin of the wound.

From drawings by Mr. S. G. Shattock.

Fig. 1.

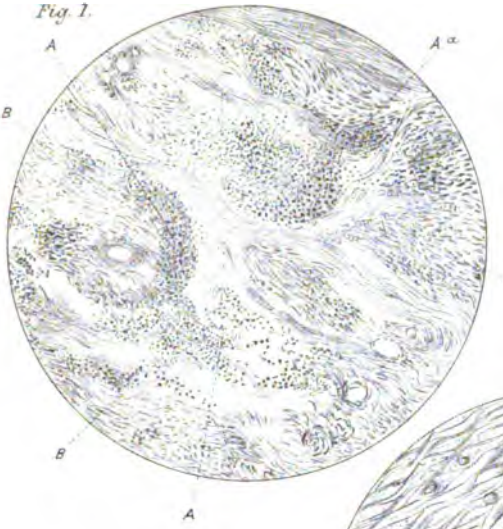

Fig. 5.

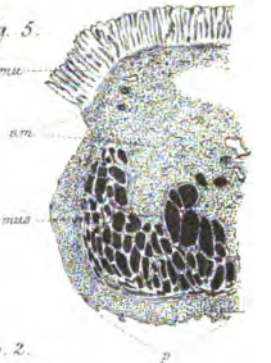

Fig. 2.

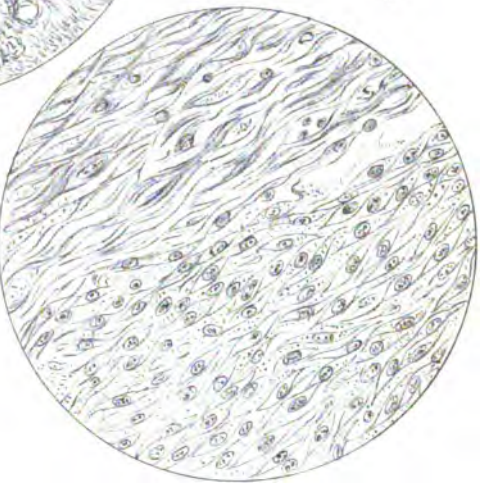

Fig. 4.

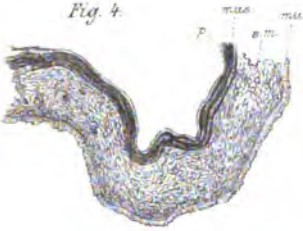

Fig. 3.

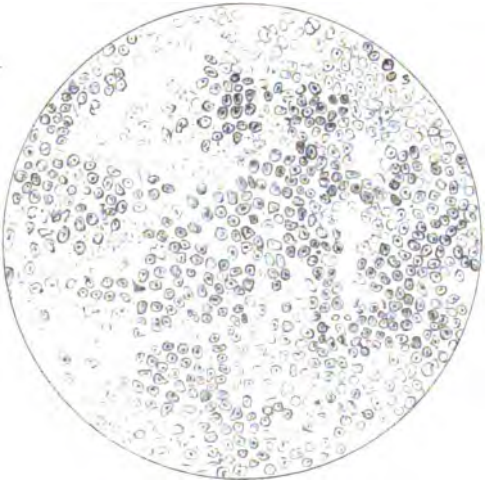

D. W. Finlay & S. G. Shattock del.

R. Huth Lith. Edinr.

there was a secondary growth as large as a crown-piece, and in the wall of the left ventricle of the heart another about the size of a small pea. There was also a similar nodule in the left kidney.

A small, hard nodule, which on section looked like an infiltrated gland, was removed from under the integument below the left clavicle.

From its microscopic appearance the tumour may, perhaps, be best described as a myo-sarcoma, the sarcomatous part consisting, in some places of round, and in others of spindle-shaped cells. In the same microscopic specimen may be seen tracts in which round-cell growth predominates, adjacent to and often apparently mixed up with typical spindle-cell growth. Separating these areas of cell growth, there are tracts of the normal constituents of the fibro-myoma, with here and there patches which present the appearance of mucous degeneration. In some parts there is a considerable development of new blood-vessels, their walls being closely surrounded by the new cell-formation.

The most important of these appearances are shown in the accompanying drawings (Plate X, figs. 1, 2, and 3), made from a microscopical section of one of the nodular masses on the surface of the primary tumour. The secondary growth from the base of the right lung presents the same characters, except that here the round cell predominates over the spindle-cell variety of growth; and the same remark applies to the nodule from the heart's wall.

The subcutaneous nodule and that from the left kidney were unfortunately mislaid.

Such tumours as the one shown are generally regarded as degenerated fibro-myomata, and it would seem difficult to account for them on any other supposition. The length of time during which they exist, and the fact that the pedicle may present no degenerative change, traverse the idea that they are malignant in their beginnings.

That no other explanation of the present case could be entertained will appear, if regard be had to the fifteen years' history, to the appearance of the growth itself, and to the coexistence of the smaller benign growths.

Few cases of such a change from a benign fibroid to a malignant sarcoma have been reported, and these, so far as I have been able to ascertain, have been almost invariably of the submucous or intra-uterine variety. Schroeder figures two such cases in Ziemssen's

'Encyclopædia of Medicine,' the growth in each being of the spindle-cell variety.

Two cases which would also probably be included in the same category have been recorded in the 'Transactions' of the Society under the name of "recurrent fibroid" tumours of the uterus.

One of these, brought forward by Mr. Hutchinson, and reported on by Drs. Bristowe and Priestley, will be found in vol. viii, p. 287. It is designated a "recurrent fibroid tumour of the uterus assuming a polypoid shape." It was a submucous growth, had lasted for three years, and had been several times removed. Microscopically it was described as "consisting of fibroid and organic muscular tissue with round or ovoid nuclear bodies united with one another by means of a very indistinct and delicate fibroid network," and, in addition, a part of the tumour which was of a soft consistence presented here and there "fusiform cells containing elongated nuclei." No secondary deposits were noted.

The other is reported by the late Mr. Callender in vol. ix, p. 327, and is entitled "recurrent fibroid tumour of the uterus with growths of a similar character in the pericardium, the lungs, and the body of the sixth cervical vertebra."

In this case a large tumour, measuring five and a half inches in its chief diameter, was found growing from the posterior wall of the uterus, to which it was connected by a base two and a half inches in breadth; and in the interior of the uterus was another tumour, also attached to the posterior wall, through the substance of which it was continuous with the former. The disease had lasted for six and a quarter years. It is stated that these growths "were composed of characteristic oat-shaped cells, mingled with others of a flattened fibroid form, each containing a single nucleus, having within it several clearly defined nucleoli, with fibrous septa extending through all portions of the growths." The metastatic growths presented similar characters.

These two cases were placed on record five and twenty years ago, and, so far as I know, none resembling the present have appeared in the Society's 'Transactions' since that time.

March 6th, 1883.

17. *Extreme prolapse of uterus, bladder, and vagina, beneath the pubic arch; consequent obstruction, with dilatation of ureters and pelves of kidneys, producing structural changes in the latter.*

By ARTHUR E. BARKER.

THE specimen exhibited requires but few words of description, illustrating as it does only a variety (though an interesting variety) of a condition well known. It consists of the uterus, vagina, bladder, and urinary tract, removed from a patient who died at University College Hospital on January 22nd, 1883, of erysipelas starting in the foot.

It illustrates, in the first place, a very marked prolapse of the uterus and vagina, but with the addition in this case, that even the bladder, too, has been carried out of the pelvis with the uterus beneath the pubic arch, so as to lie quite between the thighs covered by the extroverted vagina. The latter formed a large tumour of the usual appearance, and when a catheter was passed into the urethra it took a direction backwards and downwards into this tumour between the thighs, and did not enter the pelvis at all. The ureters were, of course, also dragged down with the bladder into the extroverted vagina, and the alteration of the direction of their angle of entry into the bladder, as well as probably some pressure against the pubic arch, had given rise to marked obstruction to the flow of urine from the kidneys. But it is in the changes induced by this obstruction that the chief interest of this specimen appears to lie. The first thing noticed is dilatation of the ureters and pelves of the kidneys, on both sides together, with flattening of the pyramids, so that they are much reduced in depth. Besides this, there is evidence on both sides of bygone interstitial nephritis in the production of puckered depressions all over the surface of the kidneys, corresponding to a fibrous change in the part of the cortex lying underneath. All this is only what might be expected when we remember the effects of obstruction to the flow of urine from other causes; but I am not aware that attention has yet been called to this condition as a source of danger to females who suffer from prolapse of the uterus. That the condition may be dangerous is, I think, shown by an examination of the kidneys in this case;

and that the kidney lesions were the result of obstruction, and the irritation of intra-renal pressure only, is, I think, clear from an examination of the case, for neither in the bladder, ureters, pelves, nor, indeed, in the history of the case, can we find any evidence of inflammatory changes such as are so usually associated with obstruction. In the ordinary forms, such, for instance, as that due to stricture or stone in the bladder, we cannot generally separate the changes due to the pressure alone from those attributable to a simple extension of the inflammation upwards from the bladder; but here there appeared to be no trace of the latter, present or past, and whatever structural changes are present in the kidney may be assumed to be simply the result of intra-renal pressure. Cases which give us an opportunity of studying these effects of pure and simple obstruction to the flow of urine from the kidney without inflammation are not very common, and I have thought that this specimen of an otherwise common condition might not be without interest to the Society. *March 20th*, 1883.

---

18. *Double hydrosalpinx.* (*Card specimen.*)

Exhibited by NORMAN MOORE, M.D.

BOTH Fallopian tubes are greatly distended with clear fluid. The distension, which makes each tube as large as the little finger, is greatest at the ovarian end. The tubes are adherent to the ovaries. One ovary has a small cyst; the other is natural, as is the uterus.

The specimen is from a woman, aged 33, who died of phthisis in St. Bartholomew's Hospital. *November 7th*, 1883.

19. *Primary cancer of the undescended testis; cancer of thymus; vacuolation of liver and kidneys.* (*Card specimen.*)

Exhibited by F. A. MAHOMED, M.B.

THIS was exhibited as a card specimen. The case was one of much clinical as well as pathological interest.

R. R—, a man, aged 53, was admitted under Dr. Moxon, on September 2nd, 1882, but he passed for some weeks under my

own care. The patient presented a tumour in the hypogastric region, occupying the position of a distended bladder, semi-elastic to the touch. There was no evidence of secondary infection of the peritoneum. The exact nature of the tumour was not recognised, nor was the absence of the right testis observed. The tumour rose and fell with distension and evacuation of the bladder. An exploratory puncture was made, and fragments of a highly cellular growth were removed with the canula. An operation for removal of the tumour was contemplated on September 22nd, but the left leg had become œdematous, and there was some enlargement of the inguinal and iliac glands; this indicated a probable secondary infection and negatived operation. A large retro-peritoneal mass of glands was subsequently detected during life and found at the *post-mortem*. Death occurred on December 30th, 1882, about five and a half months from the first appearance of symptoms.

The right testis was undescended; it formed the primary cancerous mass, and weighed 36 oz. It occupied the position of a distended bladder; the body of the testis was turned upwards, its long axis transversely across the pelvis; the organ still retained its characteristic shape; the *globus major* projected beyond the body of the testis towards the right side, and could be felt during life. The mass was semi-fluctuant to the touch; it was completely non-adherent to surrounding parts, which were not affected by disease; it was pedunculated, and could have been easily removed during life, the pedicle being formed by the *vas* and vessels of the organ; the cord was not thickened or cancerous; it followed its normal course and position except where it should have passed through the internal ring; about two or three inches away from this it projected from the brim of the pelvis, or rather from the upper surface of psoas and iliacus; it had its normal covering of a single layer of peritoneum, but appeared never to have reached the ring, which was closed; the pedicle was about 1¼ inches wide and ⅛th inch thick. On section the mass was white and very juicy. No cartilage. Several colloidal patches. No vestige of structure visible. The epididymis was more inclined to a cystic appearance than the testis, the loculi containing colloid material. Under the microscope it exhibited the ordinary appearances of medullary carcinoma.

There was a large mass of retro-peritoneal glands affected by the disease, which pressed upon and caused dilatation and ulceration of the duodenum, compressed but did not completely obstruct the bile duct. There was a remarkable dilatation of the smaller branches of the duct in the liver, giving that organ a honeycombed appearance, which suggested vacuolation of Gruyère cheese type; it may indeed have been affected by this disease, for the larger ducts were not so conspicuously dilated; moreover, the gall-bladder contained only 2½ oz. of thick dark bile, and there was no jaundice, while the smaller ducts or vacuoles contained clear, greenish-yellow fluid; they measured from 1 mm. to 2 mm. in diameter. Under

the microscope there were no structural changes in the liver tissue beyond some compression and atrophy of the cells by these cyst-like cavities, whose walls were structureless. That there was some obstruction to the common duct is certain; it appeared that a slightly increased resistance to the flow of bile in the smaller ducts had caused this peculiar dilatation of them, or vacuolation by dilatation of lymphatic spaces. The liver was otherwise healthy, and weighed 53 oz.

The thymus was enlarged and cancerous, forming a tumour, resting on the transverse aorta, pyramidal in shape, the apex pointing upwards; height 2½ inches, base 2 inches. It was white in colour, and presented the same appearance as the growths in other parts. Several cervical glands were cancerous. The bronchial glands were affected by the disease, and through them the left lung had been invaded. There were some nodules in the pleura, but the peritoneum was free from cancer. Both kidneys contained many cysts; they were most numerous in the right, and varied from the smallest size to that of a marble, probably they were affected by the same disease as the liver; the kidneys were otherwise healthy, and weighed 11 oz. Spleen 6 oz., healthy. Heart and pericardium healthy. The left testicle was healthy.

February 6th, 1883.

Note.—I should mention here that the importance of this vacuolation of the liver and kidneys did not occur to me till I heard the paper by Dr. Hale White on vacuolation of the brain at a later period of the session. Unfortunately the brain was not examined in this case.

VI. DISEASES, ETC., OF THE OSSEOUS SYSTEM.

1. *Diaphragm in a case of rickets.*

By Norman Moore, M.D.

A cast and drawing showing how considerable may be the depression of the diaphragm and local pressure upon the liver in a case of rickets. Three large beads cause as many projections from the under side of the diaphragm.

It seems possible that local thickenings of the capsule of the liver, otherwise difficult of explanation, may be produced by the continued pressure through the diaphragm of large beads in rickets. The specimens were from a girl aged 1 year and 8 months, and the beads, of which the largest was equal in size to a hazel nut, were on the seventh, eighth, and ninth ribs. There was a well-marked pigeon breast. *October 17th*, 1882.

---

2. *Living specimen of hypertrophy of the left ramus of the lower jaw.*

By Christopher Heath.

[With Plate XII.]

E. B—, aged 36, a healthy, well-nourished woman, was the subject of great deformity of the face, the chin being pushed over to the right side (fig. 6). Eleven years ago she had left hemiplegia, and the mouth was drawn over to the right. She gradually recovered power on the left side, but the face has become permanently distorted, the alteration having slowly come on without attracting special attention.

Present condition.—The chin is well to the right of the median plane. There is considerable thickening about the left side of the

lower jaw, the left ramus of which measures 3 inches against 1¼ inch on the right side. The distance between the angle and the symphysis is the same on both sides. The teeth of the lower jaw are protruded to the right of those of the upper jaw. The left temporo-maxillary articulation is enlarged but movable; the right is normal, and there is a fair amount of movement of the whole jaw.

Mr. Heath regarded it as a case of hypertrophy of the bone, and

WOODCUT 6.

proposed to remove a portion of the ramus, including the condyle, so as to restore the "bite" and diminish the deformity. This was done, and the following is the *description of specimen* by Mr. Victor Horsley.

Chronic enlargement of the upper end of the left ascending ramus of the lower jaw. (*? Rheumatoid arthritis.*)—The portion of jaw excised (Pl. XII) consists of the upper end (the enlarged condyle) and the neck of the left ramus, together with a small portion of the posterior border of the coronoid process. The lower end of the specimen—*i. e.* the surface divided at the time of operation, presents the ordinary appearances of the vertical ramus as seen on section, and is of the usual thickness.

The bone, however, is widened antero-posteriorly in its whole extent, starting from the sigmoid notch, and it expands superiorly into a broad oblong mass with a rough flattened surface, measuring 1¼ inch from before back and about 1 inch across.

DESCRIPTION OF PLATE XII.

Illustrating Mr. Christopher Heath's case of Hypertrophy of the Neck and Condyle of the Lower Jaw. (Page 186.)

FIG. 1.—Outer aspect.
FIG. 2.—Inner „
FIG. 3.—Upper „

From drawings by E. S. Gibson.

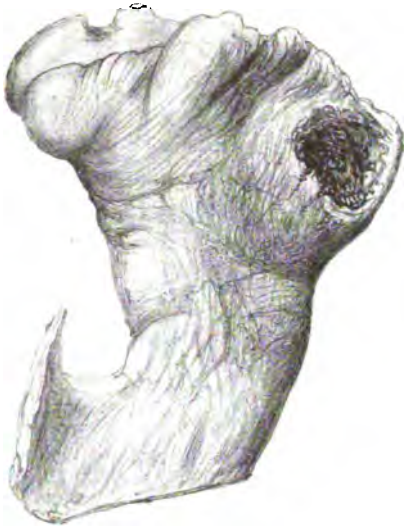

Fig I

Fig II

Fig III

E Burgess Lith

The outer surface of the mass, although nodular over the upper half, is smooth, and presents a layer of dense bone, varying in thickness from 1—2 mm. in front, to a mere space along the posterior border.

The anterior extremity of the margin of the upper surface terminates in a boss, with the under surface convex, but the upper irregularly concave and covered by fibro-cartilage.

The cancellous tissue filling the interior of the mass is in greatest quantity at the upper part, but the spaces are everywhere small (none more than 1 mm. in diameter), and the spicula of bone are thick, so that the tissue as a whole is dense and heavy.

March 6th, 1883.

---

3. *Hypertrophy of condyle of lower jaw.*

By FREDERIC S. EVE.

THE following specimen was lately presented to the Museum of the Royal College of Surgeons by Mr. Jeremiah McCarthy, and I am indebted to him for the history of the case and for his kind permission to show it.

The jaw was taken from the body of a man, about forty years of age, who was admitted into the London Hospital in a state of coma from apoplexy. There was a remarkable deformity of the face, owing to the deviation of the symphisis from the middle line; the right condyle of the jaw projected considerably, and at once suggested rheumatic arthritis. The patient died shortly after admission. The brain was not examined, and nothing more than generally diseased vessels was found in the *post-mortem* examination.

Mr. McCarthy made inquiries of the patient's friends and, as he had served in the artillery, at the War Office. It was stated that nothing had been noticed about his mouth as a child. There was no history of any injury, and the only peculiarities his comrades had observed about him were excessive deafness and an enormous appetite.

The lower jaw presented the following peculiarities:—Projecting from the thickened neck of the right condyle was a mass of bone about an inch in length, and having somewhat the form of an inverted pyramid. Its upper surface, corresponding to the base of the pyramid, was flat and smooth, as if covered with a thin layer of fibro-cartilage. Upon the inner side of the mass, near its attachments, was a deep indentation from which a fissure extended outwards and downwards nearly to the external surface of the bone. The indentation and fissure together formed the upper boundary of a process of bone occupying the usual position, and bearing the form of the condyloid process slightly enlarged. The pyramidal mass described, therefore, appears not merely an overgrowth of the condyle itself, but something super-added and occupying relatively the same position to the jaw as the quadrate bone of some animals.

The left half of the jaw was smaller in all its dimensions than the right half, the horizontal ramus being only half the width of that on the right side.

The nature of the osseous outgrowth is very uncertain. Its position and peculiar form with the absence of other joint affections are unfavorable to the diagnosis of rheumatism, while the history appears equally decisive against congenital hypertrophy, although the general enlargement of the right half of the jaw points to a congenital affection. The suggestion may be thrown out that a slight and unnoticeable enlargement of the part existed at birth, and that rapid growth did not take place until later life, as in the instances of congenital hypertrophy of limbs described in the miscellaneous specimens towards the end of this volume of the 'Transactions.' *May 15th*, 1883.

---

4. *Photographs of a case of osteitis deformans.*

By Henry Morris, M.S.

[With Plate XIII.]

John A—, aged 42, a painter, living in South Kensington, was admitted into the Middlesex Hospital on June 26th, 1882. The following notes of him were taken at the time by my dresser, Mr. H. J. Thornton.

DESCRIPTION OF PLATE XIII.

Illustrating Mr. Henry Morris's case of Osteitis Deformans. (Page 188.)

Three photographs, reproduced in autotype, representing a case of Osteitis Deformans in the erect, sitting, and recumbent postures. The curvature of the lower limbs and back is shown in all.

BARRAUD PHOTOGRAPHER.

About twelve years before admission he noticed a crampy sensation in his right thigh, which caused him to limp, and soon after that his right thigh-bone and tibia were bent forwards and outwards. The bowing first affected the femur, and then the tibia, and as soon as the bones began to bend they also became nodular, and enlarged in circumference. The foot and ankle were unaffected. Rheumatic pains came "on and off" in his leg; his general health remained good.

Subsequently his left leg and thigh-bones were affected in a similar way.

During the last three years he has suffered much from cramps in his legs, and during the last twelve months with pains in his back; these pains are always worse in damp weather.

Latterly his legs have become so weak that he has been obliged to use a stick or umbrella in walking. On several occasions he has been seized with sudden loss of power in the right leg, these attacks have occurred chiefly in damp weather.

During the last six or seven years he has at times observed his urine to be thick and muddy.

He has had no severe illness for twenty years, but during the last five or six years he has been losing flesh considerably, and his stature has shortened five inches. His natural height was 5 feet 8 inches; he is now 5 feet 3 inches. Of late his sight has been impaired. Two years ago he had an attack of gout in the metatarso-phalangeal joint of the left great toe. He has never had rheumatism, lead colic, wrist drop, nor any paralytic attack beyond the loss of power in his leg referred to above. No personal history of syphilis, nor of enlarged glands when young. No family history of phthisis, scrofula, or cancer, or of any affection of the bones. His father had gout and lead colic. He himself has been married twenty-nine years, and is the father of three healthy children. His wife has never miscarried. He has been a painter since his early youth.

On admission the following description was written of him:— A rather emaciated and pale-complexioned man, with dark-brown hair and beard, just beginning to turn grey. His attitude and mode of progression are strikingly peculiar. His head is bent forwards and downwards to the chest; his legs and thighs are bowed outwards. When he stands as erect as he can the feet touch, the knees are widely separated with an interval of 5½ inches between the condyles, and there is a marked stoop in his back. He walks with

the toes pointing inwards, so that he has to lift one foot over the other; he has considerable difficulty in stooping down.

The deformity of his legs is almost exactly similar in the two limbs; the tibiæ are greatly thickened and uneven on their surfaces; the shins are widened, and present elevations and depressions; the upper ends of the tibiæ are much enlarged, the lower ends are unaltered. From the lower extremity of the patella to the tip of the inner malleolus on the left limb the measurement is 15¼ inches, on the right limb 16 inches. The fibulæ appear normal. The ankle-joints and the bones of the feet also appear normal. There is crackling in both knee-joints, but the movements are unimpaired. The patellæ are slightly enlarged; the femora are thickened and much curved outwards and forwards; the circumference of the thigh is the same in the two limbs; and from the anterior iliac spine to the lower end of the patella the distance is 19½ inches on both sides. The iliac crests are broader and rougher than normal.

The muscles of the fronts of the thighs and those of the legs are firm, and contract into hard masses; the glutei, hamstrings, and adductors of the thigh are very flabby and weak. The smaller veins of both legs are varicose. He has had an inguinal hernia on the left side for many years.

From the junction of the lower with the middle portion of the dorsal region the spine makes one long continuous curve up to the third cervical vertebra. The curve is a steady and uniform one with the convexity backwards.

The ribs are so nearly approximated that it is not possible to make out any appreciable intercostal spaces in the lower half, nor in the posterior segment of the chest; in front of a vertical line from the axilla the spaces are better marked.

From the front the chest looks in no way abnormal, excepting that the individual costal cartilages and the front ends of the ribs are larger than usual.

Both clavicles are much increased in size and in curvature, so that the inner half projects forwards in one large prominent curve. The left clavicle, which was fractured seven or eight years ago, is neither more nor less altered than the right. No change can be detected in the lower jaw.

The head presents no marked abnormality, but the occipital and mastoid processes appear somewhat exaggerated, and the patient says that he requires a larger hat than he used to do. From mastoid

to mastoid equals 13 inches; from occipital protuberance to the root of the nose equals 14½ inches. The ophthalmoscope revealed no change in the fundus of the eyes.

The urine was fully examined on several occasions; he passed sometimes an average daily quantity of from 50 to 60 ounces; sometimes as much as 82 ounces in twenty-four hours; it had a specific gravity of 1025-30, was clear and of normal amber colour, acid reaction, and free from albumen, sugar, or pus; the phosphates and chlorides were normal in amount; there was a slight deposit of mucus. Microscopically there was nothing abnormal. Examined by the hypobromous acid test, for estimating the amount of urea, it was found that the quantity passed was frequently less than normal. Thus, on one occasion, when 52 ounces had been voided in the twenty-four hours, $1\frac{7}{10}$ grammes of urea were found in 100 c. c. of urine, making about 26 grammes or 410 grains of urea excreted in twenty-four hours, instead of 33 grammes or 500 grains, the amount passed in health. Other examinations, on several occasions, gave similar results.

At times he complained of great pain in his back. A few days after admission his feet and ankles were swollen, and œdematous so that they were ordered to be bandaged. After four or five days the swelling subsided, and the œdema gradually passed away. There was a mitral bruit with the first sound of the heart, heard best at the apex.

On June 6th Sir James Paget saw him, and declared the case to be a typical one of "osteitis deformans." On this day the subjoined photographs were taken. When asked to stand in the easiest position possible to himself he at once placed the palms of his hands on his thighs just above his knees, whereby he conveyed the weight of his head and shoulders to his legs through his extended arms, thus relieving his weak, curved, and often aching back. This attitude at once suggested to me the idea of supporting him in a Sayre's jacket, and he wore one with much comfort during the rest of the time he was in the hospital. He expressed himself as much relieved by it from the pain in the back and limbs.

May, 1883.—The man is still living, and following his occupation as a painter. *December 5th*, 1882.

5. *Two cases of curvature of the femur, one due to osteitis deformans, the other to an injury followed by chronic inflammation.*

By Anthony J. Bowlby.

Case 1.—W. H—, aged 64, was admitted into St. Bartholomew's Hospital on September 13th, 1880, suffering from advanced heart-disease and chronic nephritis, from the effects of which he died on December 9th. The lower extremities were of equal length, but the right thigh was much curved in a forward direction, and its muscles wasted, the knee-joint of the same side was partially anchylosed. No history of the curvature of the limb was supplied by the patient during life, but after death his wife said that he had met with an injury when ten years old, and that for a long time afterwards there was a constant discharge from openings on the inner side of the knee, the sites of which when he came under notice were marked by three depressed and adherent cicatrices. She also said that for so long as she had known him—a period of over thirty years—the bent condition of the limb had not altered and caused him no trouble, though for many years after the original injury he had had very bad health.

A *post-mortem* examination revealed partial anchylosis of the knee joint.

After maceration, the right femur shows the following conditions. It is very little greater in circumference than natural, but is bowed forwards in one uniform curve, fairly equally distributed over the whole length of the shaft, so that when the bone rests by its two extremities on an even surface, the under portion of the centre of the femur is raised $2\frac{3}{4}$ inches above the subjacent plane. There is absolutely no external curvature. The surface is slightly roughened by the deposit of thin, irregularly placed laminæ and spicula of new bone, widely diffused over the entire shaft, but most abundant at the inner and posterior portions of the same. The head and trochanters are natural, the condyles are flattened, and around their margins and on the surface of the external one are nodular outgrowths of new bone. A longitudinal section shows considerable thinning of the compact osseous tissue of the shaft, a condition which is most

marked in the lower third of the bone. Immediately above the condyles is a small cavity containing masses of a soft material exactly resembling cheese (? adipocere), and above this the spaces of the cancellous tissue are much widened and filled with a substance having the consistence of soft mortar. At first sight the medullary canal appears filled up with sclerosed bone, but a closer investigation shows that this is only the case to a very limited extent, and that the material that mainly blocks it up readily receives the impress of the nail, and is apparently of the same nature as the mortar-like substance already mentioned.

An inch below the small trochanter is a cavity similar to, but smaller than, that of the lower end of the bone, not bounded by any distinct walls, and containing a like cheesy material.

Case 2.—C. G—, aged 64, a cabman, was admitted into St. Bartholomew's Hospital on August 23rd, 1882, suffering from an injury to the head which caused death fourteen days later. No measurements of the thighs were made during life, and the patient was not in a condition to give any history of his previous health; it was noticed, however, that the right femur was much curved in an outward and forward direction, and was shorter than its fellow. After death, his son, who was an intelligent man, told me that his father's leg had very gradually become curved during the last ten years of his life, that it had not caused him any pain, and that he had frequently measured both limbs with the view of ascertaining the amount and progress of the shortening, which a few months before death amounted to two and a half inches. He had often suffered from gout, mostly in the great toe, but was otherwise healthy.

A *post-mortem* examination showed that the only bone affected was the femur of the left side. The periosteum was natural, and was neither unduly thickened nor adherent. After maceration, the most striking characteristics noted are the following:

The whole bone is curved in an outward and forward direction, the curvature affecting the entire length of the shaft, though most marked in its upper half. The shaft itself is much increased in circumference, and very flattened in its antero-posterior diameter; the girth of the thickest portion measures as much as six and a quarter inches; measurements of normal femora at the same level averaging about three and a half to three and three quarters inches.

The entire surface is rough and uneven from the presence of flattened, nodular growths of new periosteal bone, most marked in the upper third and along the linea aspera, and almost absent from the lower sixth of the shaft.

The articular surface of the condyles is natural. The neck of the bone is placed at right angles to the shaft, but is not shorter than normal; the canals for blood vessels about its base are unusually large, as is also the case in some other portions of the femur, especially on its posterior surface. Some parts of the head and neck present changes exactly similar to those noted in an early stage of rheumatic arthritis, the bone being smooth and porcellaneous, with growths of nodular osteophytes, and with the worm-eaten appearance so common in this disease. On making a longitudinal section, the first thing noticed was the very unusual ease with which the bone might be sawn. The medullary canal is irregular in shape, and its calibre is encroached upon by new bone, sometimes of a hard, porcellaneous appearance, and again of a more cancellous nature. The compact tissue is immensely increased in thickness, and there is a general tendency exhibited to a separation of its constituent laminæ.

At about the centre of the shaft, in the anterior portion of the sawn bone, is a cavity, about the size of a nut, which contained a small, hard sequestrum of dead bone. (This has, unfortunately, been mislaid.) Similar irregularly-shaped cavities may be seen in other parts of the shaft, head and neck, but they were empty. The compact tissue of the upper articular surface is much increased, and the normal arrangement of its cancellous tissue destroyed. The same may be said of the condition of the condyles.

It will thus be noticed that, though in each of these specimens there is an undue softening and curvature of the bone, and that the manner in which the periosteal new bone is deposited is in each similar, yet in every other particular they have nothing in common. In one case there is increase of length, in the other shortening; in one the compact tissue is thinned, in the other hypertrophied; in one there is the formation of a soft caseous material, in the other of new bone; in the one there is no evident increase of vascularity, in the other the canals for blood-vessels are greatly enlarged; in one the head and neck are normal, in the other they are diseased. But in both the same process appears to have been at work, and the cause of the curvature in both I believe to have been inflammation.

The cause of the difference of the results is to be sought in the patients themselves, not in the process.

As regards the first case, it appears certain that the pathological appearances are the result of inflammation, the presence of cicatrices adherent to the bone, the history of the accident, and of the subsequent long-continued suppuration. The character of the periosteal new bone, the anchylosis of the knee-joint, and the fact that the deformity was evidently completed early in life, scarcely leave room for doubt. The only other disease, indeed, namely rickets, which could well occur in so young a boy, was evidently not the cause of the present malformation, for all the other bones were normal, and the characteristic thickening at the junction of the epiphysis with the diaphysis is conspicuous by its absence.

But even regarded as the result of inflammation, the curvature of the bone is of itself a rarity. Lengthening of the femur following on any abnormal condition which causes an increased vascularity at the epiphysial ends is of course sufficiently well known, and is undoubtedly present in the case under consideration, for despite the bowing forwards of the thigh the limbs were of the same length.

But though I have seen several instances of this condition, including one in which the lengthening amounted to an inch and three quarters, in none have I seen a curvature such as is presented by this femur, nor have I found any record of a similar case. On this point the experience of Sir J. Paget is naturally of great value, and while writing of this increased length of bones from excessive blood supply, in his account of osteitis deformans (in vol. lx of 'Med.-Chir. Trans.'), he says: "With the exception of the tibia they do not become curved," and further, goes on to explain that this is the result of the inflamed bone being attached to the unaffected fibula, which acts as a splint. But in most cases of chronic osteitis or periostitis there is an excessive formation of new bone, and we are at once struck with the fact that in this specimen the curvature is combined with an almost complete absence of sclerotic changes, and with the presence of the soft mortar-like or cheesy material already mentioned.

It is almost impossible not to link these two facts together as cause and effect, and to conclude that had the usual sclerotic changes taken place the bending of the bone would not have occurred. Again, in the chronic inflammations which result in lengthening of bone, the morbid processes are seldom spread over so large an

extent of surface as in the present case, and from a purely mechanical point of view such a diffusion of the softening of the osseous tissue (which is always present to a greater or less extent in inflammation) would be more likely to result in an increase in the curvature of the affected bone than would a more localised disease.

The soft, mortar-like, and cheesy material found in the present specimen most probably consists of degenerated inflammatory effusion which has undergone caseous changes, such as are more common in other parts of the body. The reason for this degeneration is to be sought for in the debilitated state into which the patient apparently passed, as the result of the profuse and long-lasting suppuration, for it is in such conditions that the products of inflammation are least prone either to become organised or to suppurate, so that if they have been poured out in quantities too large to admit of absorption the only remaining course open to them is degeneration.

Lastly, I would draw attention to the entire absence of any external curve, for this is almost invariably present in all cases of bowing of the femur, from whatever cause arising, and, indeed, in the present bone, even the slight natural curve in this direction appears obliterated. For this anomaly I am unable to suggest any explanation.

In the second case there can be no doubt that the bone was the seat of the disease known as osteitis deformans, of which, indeed, it is a very typical example. The most interesting points in connection with it are the following:

1st. It is the first specimen yet described in which the femur was the only bone affected.

2nd. As in other cases, the patient was a sufferer from gout.

3rd. There appears to have been a coincident rheumatoid arthritis.

4th. The presence of a small sequestrum, the separation of the laminæ of compact bony tissue, the enlargement of the vascular canals in the bone, the softening of the osseous tissue, and the appearance of the subperiosteal new bone, all lend weight to the already established theory as to the inflammatory nature of this disease.

February 20th, 1883.

6. *Extensive hyperostosis of skeleton, with bone softening and rickety changes, probably of syphilitic origin.*

By JAMES F. GOODHART, M.D.

ARABELLA T—, aged 1¼ years, was admitted to Guy's Hospital under Dr. Hilton Fagge on July 4th of the present year. She was brought for prominence of the spine, swelling of the neck, legs, arms, and abdomen.

The following condensed report is from the very careful notes of Mr. L. J. Kidd.

There are two other children, one appearing to have rickets. The mother has had no miscarriages, but contracted a gonorrhœa from her husband before this child was born. The confinement was a severe one, and she recovered only after three months. The labour was natural. On the second day after birth the child had a considerable discharge from the eyes, and this has never got quite well. It was nursed for three weeks only, and then brought up by bottle on diluted milk and beef tea; cod-liver oil being also given by the doctor's orders. For some months constipation was troublesome, and castor oil given for it. The child gained flesh well, but has always slept much and perspired profusely. Has had thrush badly, and occasionally spots on the nates. The abdomen was always large. During the last three months the spine has become curved, and since then the child has been in the habit of crying when moved. About a month before admission the legs became swollen, and then the arms and the neck.

It was noticed to be an ill-developed child. It had internal strabismus and nystagmus. The nose was flattened, and there was slight desquamation of the lips at the angles of the mouth. Craniotabes over the occipital bone was well marked; the ribs were beaded, and the thorax flattened laterally. A large lump could be felt on the inner surface of each tibia and over each radius—like nodes—and there was enlargement of the lower epiphysis of each radius. It was too irritable to allow of any careful examination of the chest. The spleen reached as far as the umbilicus. It appeared to be of good intelligence and took food well, but soon after admission bronchitic symptoms supervened and with these it died.

Autopsy.—A puffy, pale body, but with nothing characteristic of congenital syphilis about it. The tibiæ were considerably curved, and a diffused swelling thickened the centre of each shaft. A similar swelling was found on the left femur, the right humerus, and the radius on each side.

On removing the calvaria a remarkable state of things presented itself. The bones were enormously thickened and heavy, the walls being about fifteen millimètres thick, gradually lessening till the occipital was reached and where the bone was easily depressed by the finger (craniotabes). The pericranium stripped easily from the surface and appeared natural; the bone beneath was of a more livid colour than natural and granular looking. The surface was soft so that it could be depressed somewhat, and gave a sensation such as that imparted by very firm velvet under compression. The entire bone was very soft being easily cut by a knife, but the section showed that the inner table was comparatively healthy in appearance, while upon it had grown, with some appearance of lines parallel to the inner table, a mass of new bone for the most part arranged in closely-set vertical lines, and evidently of the nature of a periosteal growth. These ran from the inner table to the pericranium obliterating the diplöe, and this arrangement it was, no doubt, that gave the velvety sensation to the touch, its anatomy being practically the same as that of velvet, viz. vertical fibres closely set upon a firm fibrous base. This arrangement, too, gave the peculiar, spongy, porous appearance which the section possessed.

The base of the skull was in a similar condition. The roof of each orbit measured 10 millimètres in its thinner part to 15 millimètres in its thickest, and the alæ and body of the sphenoid were thickened in like manner; the sphenoidal cells being in great part filled up by this new spongy bone. Of all the parts of the skull the petrous bones alone appeared not to have suffered; they could not be cut with a knife. The remainder was cut into with ease in this manner.

The cavity of the skull suffered somewhat no doubt, but the greater part of the disease was external to the cavity. This could hardly, however, have been so at the base, and the prominent nodular roofs of the orbits were quite noticeable. The eyeballs were not unduly prominent. The brain weighed 27 oz. and was quite healthy.

The spine was less evidently, but not less certainly diseased. On making a vertical section of the bodies of the vertebræ, the healthy

chocolate-coloured porous marrow was only visible in many at the hinder part. More or less of the anterior part, and in many cases most of the body, was converted into a white or pink, fleshy, homogeneous, soft, granular bone, more like an infiltrating new growth. In addition to this many of the intervertebral substances were thickened in front from the anterior common ligament inwards, and on section looked as if a wedge of cartilage or bone had been driven into the disc between the bones. The cord and its membranes were healthy, the canal being undiminished. The sacrum and pelvic bones were healthy.

The ribs were much deformed by large beaded ends, and the beading was rendered much more apparent by a sharp knuckle-like bend inwards, at the junction of the cartilage and bone; the lateral part of the chest being thus depressed and the sternum pushed forwards.

Sections of the ribs showed that the cartilage was much swollen and sago-like, with islands of bone in parts; in fact, perfect specimens of rachitic changes. But in addition the medullary cavities were converted into close textured granular bone as in other parts, and the periosteum was much thickened from the epiphysial lines along the diaphyses.

The middle of the shaft of the right humerus was entirely converted into a firm fleshy mass of similar porous or granular bone to that in the skull, the medullary canal being entirely obliterated; the left femur in like manner. Pieces were cut from each with the greatest readiness by a scalpel, and the bone cut like a piece of potato with sand in it. A section of the bone still showed the line of the original shaft, much thickened outwards by periosteal growth, and inwards to the complete obliteration of the medullary canal.

The radii and tibiæ were in a similar condition, and one tibia was fractured in addition, owing to the extreme disease.

Summary.—The bones shown to be affected were the skull, spine, ribs, both tibiæ, left, femur (probably both), both radii and the right humerus. The clavicles and sternum were not examined, nor were the bones of the face particularly, it being impossible to expose them without disfiguring the body beyond all reasonable limits. They were, however, not altered in shape so far as the features were concerned.

It may be added that, as regards the long bones, the disease could be detected before the bones were removed, by the extensive

pallor and wasting of the muscles covering them in. The other viscera may be dismissed in brief. There was no glandular enlargement. Both lungs had suffered much from a general atelectasis.

The spleen was very large, 3 oz. It looked quite healthy save for its size, and was *soft* rather than firm. The other organs were healthy.

The microscope showed undoubted rachitic changes in the costo-chondral articulations, but there was a close similarity in all the diseased structures, whether periostal or medullary. The disease consisted of trabeculæ, of embryonic-looking bone—that is to say, hyaline and the lacunæ badly formed — and between these a quantity of loose-looking connective with granulation-like cells scattered sparsely through it.

Remarks.—The case is a very remarkable one, and probably present perhaps the most extreme instance of its kind yet recorded. Dr. Barlow has recorded and figured ('Path. Soc. Trans.,' vol. xxx) a calvaria, in many respects very similar, but the extent of disease in the base of the skull and in the long bones of the skeleton surpass the changes described there. The association of the bone disease with pronounced and even extreme rachitic changes made me doubt at first whether the whole process might not be one of extreme rickets, but a reperusal of M. Parrot's paper, published in vol. xxx of our 'Transactions,' clears up any doubt upon that point, so far at any rate as the views of that writer are concerned, and makes it quite clear that this is a good example of his spongy, or rachitic, hypertrophy of congenital syphilis.

But allowing this much, it seems to me that the pathological interest of the case does not end there, for no one can look carefully at these bones without asking himself whether they do not throw some light upon the thick skull and chronic forms of bone hypertrophy of later life which are discovered often accidentally upon the *post-mortem* table. Such a generalised disease as this comes indeed very near osteitis deformans in some of its characteristics. More of a periosteal disease than that, it yet, in affecting the bodies of the vertebræ, and the medullary cavities of the long bones, and in the softening and consequent alterations of shape of the bones trenches upon some of the special characters of that disease.

Perhaps, too, from another point of view, osteitis deformans may throw light upon this case, or each upon the other.

It is well known that osteitis deformans appears liable to some as yet obscure relations with cancer, or the growth of tumours to

speak more generally, and some have thought—myself amongst the number—that the change might not be inflammatory but some generalised tumour of the bony skeleton. Have we here in like manner some generalised growth akin to tumour? Such things are not unknown in syphilis. I may instance the occasional occurrence of large masses in the mediastinum, which possessing many of the characteristics of gummata and associated with a syphilitic history have yet nevertheless lost their syphilitic curb, and have run riot as infiltrating tumours. Have we in this bone disease an affection which, starting as syphilitic, has lost its syphilitic curb and now poses as a bone tumour? *December* 19*th*, 1882.

Report on Dr. Goodhart's specimens.—We have examined the series of bones submitted to us, and have further perused the detailed clinical report of the case.

There can be no doubt that the extremities of the bones generally, show pronounced ricketty changes. Along with these, there is a very marked degree of generalised bone softening, such as is not found in ordinary cases of rickets, and which, rightly or wrongly, Dr. Rehn has recently described as infantile osteo-malacia.

There is enormous development of imperfectly formed bony material, which reaches its acme in the basis cranii, and in some parts of the shafts of the long bones where the medullary canal is obliterated, and both medulla and compact tissue are converted into a soft spongy bone, in which most of the earthy material has disappeared and which can be cut with a knife. Further there is an extensive development of sub-periosteal material of similar nature such as we are not acquainted with in human rickets pure and simple.

We are of opinion that the detailed clinical report justifies the strong presumption that the child was the subject of congenital syphilis. Further, we find it difficult to understand in the light of other cases that a "bone suffering" and new bone formation so extensive as this could have been induced by feeding alone, which in this case, although artificial, appears to have been tolerably satisfactory.

Bone changes in many respects resembling these have been found in unquestionably syphilitic infants by M. Parrot and others, but that such are necessarily and solely syphilitic appears to us in our present state of knowledge not proven. The apportionment of the

effects produced severally by rickets and syphilis in this and other cases cannot, in our opinion, as yet be determined.

C. Hilton Fagge.
Warrington Haward.
Thomas Barlow.
James F. Goodhart.

---

7. *Extreme deformity from rachitic (?) osteomalacia.*

By Richard Barwell.

I have placed in the heading to these remarks a note of interrogation after the word rachitic, but have retained the nomenclature because there is at present, as far as I know, none other that can be used; but I do not believe the disease producing extreme distortions, such as those of this child, and such as I have seen in two other cases, to be the true rachitis, so commonly and frequently observed.

S—, aged 17, has been more or less under my supervision for the last four years, and when I first saw her the distortions were very much as now—perhaps not quite so much pronounced in the left thigh, and certainly not so marked in the back. She has grown broader, stouter, and heavier, and the length of the tibiæ has increased.

The condition is not congenital. She was up to the age of two and a half or three years perfectly well formed. Her father, though now dead, was a healthy, well-built man; her mother, still alive, is a strong, rather tall woman; her brother, only a few years older than herself, is in a regiment (97th Foot) in which only tall, well-built men are received.

The girl enjoys fair health and a remarkably good appetite, is merry, and easily moved to laughter; she has hardly the mental development of her years, but is by no means deficient; her mind is juvenile rather than weak; she is as yet non-pubic; very few if any of her bones have escaped the deforming influence, some being bent and curved to an extreme degree, and apparently also short; others, as the tibiæ, are greatly curved and disproportionately long. The head is large, the face small, the body of the lower jaw so slight

the teeth so short, that the chin comes near the upper jaw, giving to this part of the face a senile look. The head and face are symmetrical, as also the hands and feet. No other part of her is so, the bones of opposite sides being unlike each other. It would be quite impossible to give a comprehensive description of this little figure. I will only name one or two of the chiefly distorted bones.

WOODCUT 7.

Both humeri are bent, the right one to an S shape, the left with an indescribable double curve and at the lower part, a peculiar twist; the olecranon of the left arm is greatly prolonged, and is bent at a right angle, so as to nearly surround the humeral trochlea, and to rise some distance up the arm. The right tibia is about the lower fourth

bent back upon itself, that lower portion running at a very acute angle upward behind the rest of the bone, while the sole of the foot looks nearly directly upward. Some approximate idea may be formed of the amount of curve by comparing the length of the bones with the distance in a straight line between the joints.[1]

	Length.		Distance.
Left humerus	7¾ inches	from shoulder to elbow	6½
Right „	7½ „	„ „	4½
Left tibia	10 „	from knee to ankle	7½
Right „	9½ „	„ „	4½

Of course the girl cannot walk or stand, but is carried from place to place; she sits about 1 foot 8 inches high. The spine is much twisted and curved; the chest greatly malformed, but it has not the well-known shape of rickets, and it is to be particularly remarked that the ribs are not beaded, nor are the epiphyses large and swollen, as in that disease.

The bones were a few years ago remarkably brittle. When she was between nine and thirteen she broke her arms four times, and her lower limbs on several occasions, but I do not know how often. In April of this year she broke her right humerus; it healed rather quickly, but not remarkably so.

Although it is difficult to fix on a different nomenclature, I would beg to say that my experience leads me to believe that these excessive deformities are not produced by true rachitis nor by malacia in the ordinary sense of the term. The form of the curves, the shape of the chest, the condition of the epiphyses, and of the ribs, are all different from that disease, nor do the bones ever attain that stony hardness which succeeds to the soft stage of rickets. I have seen three such cases; two were boys—this, the third, a female. In one of the former I was several years ago especially desirous to try and improve the form of a greatly distorted femur. I cut down to the bone and placed a chisel on it, which at the slightest force went through the whole structure. Out of the wound flowed a quantity, that was estimated at five ounces, of pure oil. I passed the tip of my little finger into the wound, and found that the case of the bone was almost as thin as an egg-shell. The bone reunited

[1] The length of the bones is measured on one aspect, thus in S-shaped or twisted bones, the measure is alternately on concave and convex portions of the curve.

without accident, and in the usual time. This boy, and a few years ago the girl now shown, had ostitic pains on the convexity of the bony curves.

I believe, therefore, these extreme bony distortions to arise from hypertrophy of the medulla at the expense of the bone substance—a condition which may be called eccentric atrophy; that while these subjects are still youthful very little bone-earth is deposited, or at least remains in the very thin layer of osseous shell that subsists. The relationship between infantile ostitis and extreme development of intra-osseous fat, though well known, is still occult; neither should we lose sight of the possibility that the softening process of ostitis may be due to a fatty acid.[1]

Now, fatty ostitis usually occurs in epiphyses. In these cases the shafts were affected, and that throughout the larger bones, the hands and feet, being free of deformity; I would not affirm identity, but would suggest a close analogy. *December 5th*, 1882.

---

8. *Juvenile osteo-malacia.*

By Richard Barwell.

The object of this communication and of the exhibition of living specimens is to suggest

1st. That the causes of rachitic bends are probably not understood, and that they are not merely produced by the body-weight acting on soft or softened bones.

2ndly. To insist that there are, besides rickets, other juvenile diseases producing in the bones a tendency to bend, and that for these we want some other name than osteo-malacia, which denotes merely a symptom common to many diseases malignant or other wise.

For illustration of the first proposition I have procured the attendance of two children whose cases elucidate each other.

William P—, aged 8 years, first came under my notice in October, 1882, when on returning to town I found him in the Alexandra Ward of Charing Cross Hospital. During September he had been

[1] Billroth assumes the lime salts to be dissolved by lactic acid during osteitis. This idea seems to me rather far-fetched, and no such acid has ever been found.

in the charge of Mr. Cantlie, who finding an enlarged and thickened tibia had trephined the bone in search of sequestrum or abscess, but without avail.

On my return I found in this case several points of interest, especially that the tibia besides being thicker, is an inch longer than the other (right eleven inches, left twelve inches). The inflammatory osteo-sclerosis which surrounds an abscess or sequestrum does not, as far as I am aware, cause additional growth in length. Moreover the bone is bent, and is becoming perceptibly more crooked. The bend is forwards, therefore is not likely to depend upon the bone being bound by the fibula in which case it would be inward, while the fibula would remain straight in the chord of its arc.

The bend may be more properly ascribed to the hyperplasia affecting the front more than the back aspect of the bone,[1] the surface which grows quickest must become convex and force the more slowly growing one to the concave. This case is certainly not rachitic, but we may read by its light the next one.

Sarah A—, aged 4½ years, came under my care in October, 1882, with sloughy sores on the legs produced by the over-zeal of some instrument maker. She is a strong, healthy-looking child, save for certain signs of rickets, beaded ribs, bent upper half of the femora and lower third of the tibiæ. In these last-named bones is something very peculiar, the right one is very much more bent than the left and is becoming more crooked, although the child is kept in bed and therefore puts no weight on the limb. Moreover, if this extra bend were produced by body-weight acting on a tibia softer than the other or by any additional weight thrown on that limb the bone would probably be shorter; it certainly could not be longer, whereas, on the contrary, we find that it is considerably longer.

	Right.	Left.
Measured straight from upper and inner tuberosity to tip of malleolus	5¾	5½
Measured in concavity from same points	8¼	7

that is to say, there is in the right tibia an overgrowth affecting the convex, the outer side of the bone, more than the concave side. Most likely there is a similar hyperplasia also on the convex side of the left bone, but not sufficient to produce such marked lengthening nor any unusual degree of deformity. The probability of this view is increased by observing that often, and for several consecu-

[1] The boy and his parents attribute the condition to frequent blows and falls sustained while learning to walk.

tive days, the outer side of the right tibia is tender—not from injury as the child is kept in bed—therefore this tenderness indicates a condition of hyperplasia akin to inflammation.

Now, in the former case of non-rachitic hyperplasia of the tibia the bend does not take the form peculiar to that malady; in the case of rachitic excess in growth the hyperplasia produces the characteristic curve.

In the face of these facts I would submit that rickets does not merely connote soft or insufficiently calcified bones bent by the weight of the body, but, on the contrary, that the abnormal curves are produced by a hyperplastic malady which affects by preference certain districts of particular bones.

In support of this view I would point out that the movements, attempts at locomotion, and attitudes of weakly children are exceedingly diverse, and that it is impossible for such very different conditions to inflict upon soft skeletons so great a uniformity of abnormal shape as is characteristic of rickets unless the softening were limited to special localities.

In support of my second proposition that besides rickets other diseases for which we want distinctive names cause bending and deformity of bones, I would, firstly, refer to the case of the girl or dwarf that I showed here on the 20th January. It is quite possible that members now present were absent on that occasion. I have, therefore, brought with me photographs and drawings of that case.

In corroboration I also beg to exhibit another patient: Jesse H—, aged 22 years, was born healthy and well formed. He continued thus until five years of age when he was attacked with a fever, after which his bones became soft and bent. This is the case to which I referred a month ago, on whom I had performed osteotomy, and found the femora mere thin shells of bone surrounding cavities containing great quantities of medulla which flowed out of the wound as oil.

The legs are both deformed (genu valgum) especially the right; the patella of that limb is permanently dislocated upon the outer face of the external condyle, yet the shafts of the bones are but very slightly bent, only the epiphyses are bent on them very obliquely. The tibiæ have not that flattened shape usually found in rickets. I would especially direct attention to the left radius which is so twisted that the distance in a straight line between the head and the styloid process measures only six inches, but the

bone measured along the curves is one third longer, namely eight inches. Along the convexity he has frequent pains (inflammation).

This is certainly not a case of rickets. It is one of those diseases, inflammatory, I believe, for which we have no name. Perhaps ostitis deflectens might be suggested.

It appears to me that valuable information might be acquired if all this class of disease were subjected to "collective inquiry," and I should be happy to take part in such an investigation.

February 20th, 1883.

---

9. *Case of severe syphilitic disease of the facial bones and viscera.—Death from Pyæmia.*

By Victor Horsley, B.S.

The patient, R. F—, was admitted into University College Hospital, under the care of Mr. Berkeley Hill, with well marked necrosis of the facial bones (described below), and suffering from pyæmia. Abscesses developed peripherally and were opened antiseptically, but the patient died of exhaustion on November 25th, 1882.

Post-mortem. Skull.—Frontal bone covered in the middle line and on each temporal ridge with irregular white rounded eminences (bosses), between which ran sinuous scar-like depressions, the pericranium being closely adherent in many places. The whole calvaria was sclerosed, but this was especially marked in the frontal bone, which measured $\frac{1}{2}$ in. thick just above the orbits.

The centre of the outer margin of the left *orbit* consisted of a dry, round sequestrum imbedded in a mass of foul granulation tissue, and the body of the left malar, in a similar way was excavated by absorption, and the cavity filled with granulation tissue and an irregular sequestrum.

In the *nasal* cavity, the spongy bones were almost wholly destroyed on both sides, but especially the left, the inferior turbinate on this side lying as a loose sequestrum, attached only by a fold of mucous membrane.

Viscera. Thoracic.—Larynx normal. Bronchi congested; both

upper lobes of lungs showed considerable fibroid thickening with caseous purulent foci at the posterior margin of the lung. *Abdominal.*—*Liver* enlarged. Close to inner limit of left lobe a depressed scar was situated, ¼ in. deep. On section it was found to be wedge-shaped, and to consist of dense fibrous tissue.

The *spleen* was interesting as being greatly enlarged, viz., 7 in. long by 4½ in. by 2 in. This increase in size was due to chronic fibroid change throughout the organ, the trabeculæ of connective tissue being increased in thickness. Pulp of a chocolate-brown colour.

Kidneys were both larger than usual, and showed some cirrhotic change as in the spleen.

Bladder, testes, intestines and *pancreas*, normal.

Brain.—The membranes at the base (especially the arachnoid) were thickened and opaque. The thickening extended to the fissure of Sylvius on either side, and to the upper surface of the cerebellum.

Cerebellum.—Left flocculus absent.

Vascular system.—The *heart* was especially interesting, since the aortic valves showed small patches of ulceration on the ventricular surface of the corpora Arantii covered with fibrine, this being no doubt a pyæmic lesion, and therefore the heart is described here instead of with the thoracic organs. There was also some sub-endocardial fatty degeneration in the left ventricle.

In connection with the pyæmic condition, there were about nine abscesses in the most dependent parts of the limbs and trunk. These will be referred to hereafter. *December 19th*, 1882.

---

10. *Deep ulceration of cranium.*

By Norman Moore, M.D.

Calvaria, from a man, aged 42, who died in St. Bartholomew's Hospital of abscess of the brain. The scalp was entire, but for many months had felt puffy over an extensive area. When raised a quantity of pus was found beneath it, with loose pieces of necrosed

bone and much greyish œdematous granulation tissue. The calvaria was easily cut with a knife, and was ulcerated over its whole outer surface. There were also several patches of necrosis. A lesser degree of the same condition existed on its inner surface. The dura mater was entire, but there was a superficial abscess in the right cerebral hemisphere at its posterior part.

In the museum of St. Bartholomew's Hospital there are many similar calvaria collected by Mr. Stanley from cases of syphilis, and the condition is probably attributable to that cause in this case; but after careful inquiry no such history could be obtained from the patient, and the viscera were free from gummata and from amyloid disease. *Feb. 6th*, 1883.

---

11. *A case of multiple exostoses.*

By Frederick Churchill.

The patient is a girl, aged 15. *Family history.*—Mother's father and mother living, and in good health.

Father's father alive. He is said to be *double-jointed* at ankles and wrists.

Father is said to have had rheumatic fever five years ago, but has had no affection of any joints since.

The mother is in good health; she has had three miscarriages; six of her children have died in infancy—five from diarrhœa, one from scarlet fever.

The patient has had measles, but has not had rheumatism.

First signs.—At the age of seven years the patient's mother noticed for the first time hard swellings about the knees.

Two years later a number of hard swellings appeared on the collar-bones and fingers. At this time the patient had pain in the legs, thighs, and collar-bones, which was increased by pressure over these parts. The pain was not worse at night.

For the last two years the tumours in the legs have grown quickly, and for the same time knock-knee has been apparent. The girl is stunted in her growth. She is crippled, and the deformity of the bones interferes with her ambulatory movements. She feels tired on slight exertion.

Condition.—Hand, right.—All the metacarpal bones, excepting the first, have small pyramidal hard growths springing from them. Similar growths exist upon the first and second phalanges of each finger, and upon the proximal phalanx of the thumb.

Hand, left.—There is the same distribution of growths upon the bones of the left hand.

Forearm.—There are growths from the lower epiphyses of the radius and ulna in each forearm.

Arms.—The humeri appear to be free, except at the upper and inner extremity of the shaft.

Clavicles.—There are growths on the anterior surface of each clavicle at the junction of the outer and middle thirds; that on the left is very prominent; on the posterior surface, at a point just internal to the acromio-clavicular articulation, is a prominent growth on each bone.

Scapula.—There are outgrowths at about the centre of each spine, and on the vertebral borders of both bones.

The margin of the iliac crest is irregular at its central portion on both sides.

Feet.—The phalanges, excepting the terminal ones, are the seat of numerous growths, similar to those on the hands.

Legs, right.—Both malleoli are thickened and nodulated.

There is a growth springing from the inner and back part of the inner tuberosity of the tibia. An irregular hard mass springs from the fibula at the junction of the shaft with the upper epiphysis.

Thighs.—There is a growth over the internal condyle, and one just above the external condyle of the right femur.

The situation and number of the growths on the left lower extremity correspond with those on the right side.

There is genu valgum on the right side, apparently due to the large growth from the inner tuberosity of the tibia, gradually causing dislocation of that bone.

There is no irregularity of any rib or vertebra to be felt.

May 15th, 1883.

12. *Alveolar sarcoma of skull; secondary growth of bladder.*

By H. H. Clutton.

[With Plate XIV.]

The patient from whom these *post-mortem* specimens were obtained was a man 62 years of age, and a dyer by trade. He first came under my observation in September, 1877. He had then noticed for three months a swelling on his skull. This I found to be situated over the left parietal, quite fixed to the bone, with a soft fluctuating centre and infiltrating indurated margin. It was hot and tender, and he complained of neuralgic pain on that side of the head.

There was no history of any injury, nor were there any evidences of syphilis to be obtained. As there was room for doubt as to whether this was not a gummatous periostitis of the skull, he was placed under the influence of iodide of potassium for two or three weeks. This produced no alteration in the size or appearance of the swelling, which was then tapped with trocar and canula. The fluid examined by the microscope gave very little information beyond the presence of small round cells.

In October the skin became thin and red, and, as it was evident it would soon spontaneously open, the swelling was incised, with the result of letting out some thick, curdy-looking matter. On introducing my finger I found an aperture in the skull of about the size of the tip of the index finger. The margins of the aperture were exceedingly rough and ragged, and both tables appeared to be perforated, for the pulsation of the brain was very distinct. No symptoms of head mischief followed, but he steadfastly refused admission into St. Thomas's Hospital till January 10th, 1878.

On admission there was very profuse offensive discharge from a large excavated ulcer of the scalp. In the centre of this the dura mater was exposed, but appeared healthy. The margins of the ulcer were exceedingly hard, and the bone beneath was dead and crumbling away.

This ulcer continued slowly to increase in size and the margins to fungate, forming small excrescences round the central depression.

He died in May, having been an out-patient for four months, and

DESCRIPTION OF PLATE XIV.

Illustrating Mr. Clutton's case of Alveolar Sarcoma of the Skull. (Page 212.)

From drawings by Mr. Charles Stewart.

FIG. 1.—Secondary growth of bladder.

a. Strand of muscular and connective tissue, probably part of wall of bladder.

b. Alveolar network of connective tissue.

c. c. Embryonic tissue, chiefly composed of small round cells.

FIG. 2.—Tumour of skull.

a. a. Large collections of cells of irregular form and size, some of them like cartilage cells. That on the left hand has a concentric arrangement.

b. b. Alveolar network of ill-developed connective tissue.

Fig. 1.

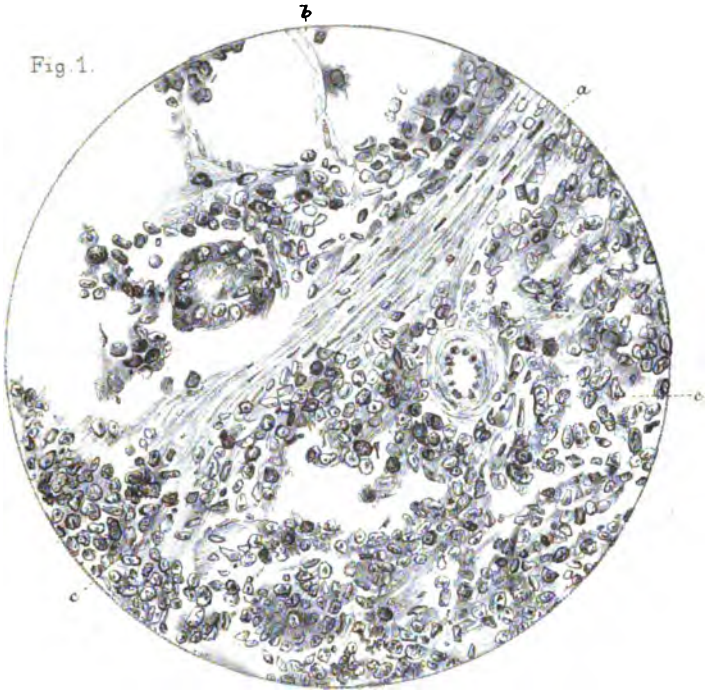

Fig. 2.

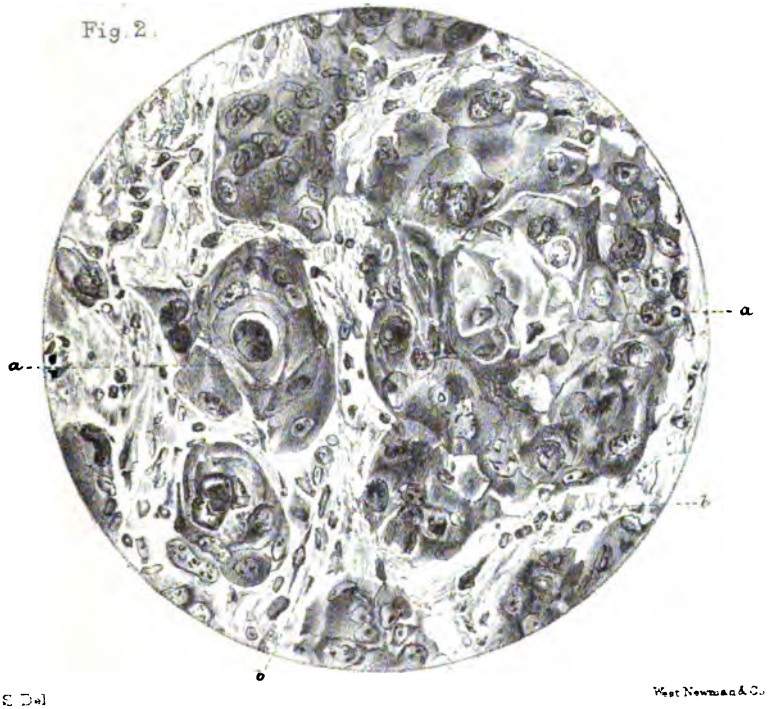

an in-patient of St. Thomas's for five months. During the last month some growth appeared on the surface of the dura mater, but the brain was never seen to be exposed. No paralytic symptoms were ever noticed. He seemed to sink from the profuse offensive discharge and the hectic temperature which it induced. He suffered severely from neuralgic pain in the scalp, requiring the constant administration of morphia. He had no bladder symptoms whatever.

Post-mortem.—A tumour was found in the bladder, but no new growths were discovered in any of the other viscera. The specimens are on the table mounted in three bottles. The first one shows the vertex of the skull with a portion of the scalp attached. The aperture in the bone is about three inches in diameter, while the scalp has been itself removed by a process of ulceration, extending five inches by four. Outside this the scalp is infiltrated with new growth, which has, on the left, broken down, leaving several cavities filled with the remains of the disintegrated tissue. The edges of the bony aperture can be seen to be light, spongy, and in part dead, but they do not appear to be much thickened.

The second bottle contains the portion of the dura mater and brain affected by the new growth. They are separately mounted. The area of dura mater exposed to the invasion of the new growth from the bone is well marked. In the centre there is an aperture of about the size of a florin. The rest of the surface, measuring about three inches by four, is thickened, rough, and irregular. The new growth is so circumscribed by the part which corresponds to the aperture in the skull that, on comparing the two specimens and their respective stages of growth, no doubt remains that the dura mater was secondarily involved. The portion of brain which occupied a position immediately beneath this aperture in the dura mater is seen to be just beginning to throw out a hernia cerebri. Two broken-down cavities are also seen in the immediate neighbourhood.

The third bottle contains the bladder. The left side of this organ is occupied, both on its inner and outer surfaces, by a tumour of about the size of an orange. It is irregularly nodular, and projects into the interior just above the orifice of the left ureter. It stands out abruptly, and is not in any way diffused along its walls. On its outer surface it is equally circumscribed, and appears to have involved the left vas deferens. The left ureter is also considerably

dilated. The bladder and prostate seem healthy and of normal size.

The *post-mortem* was made by Dr. Greenfield, and he has kindly supplied me with information as to the other organs. No new growths were discovered in any of the other viscera. There was hypostatic pneumonia of both lungs, and the right kidney contained a few cysts, whilst its cortex was wasted.

The left kidney was removed with the bladder, and examined at a later period. Of this examination there is no record, except that the absence of new growth was confirmed.

The heart and aorta showed slight commencing atheroma.

The liver was fatty, and the spleen rather soft and greasy.

The stomach and intestines, the larynx and trachea, were all healthy.

The microscopical examination of the new growth, which had its origin in the skull, reveals a great diversity of form in different parts. The most striking feature is the presence of an alveolar arrangement of the cells. These are collected together in larger and smaller groups, and are as large as cartilage cells, with very large and distinct nuclei and nucleoli. The inter-alveolar tissue is scanty, and composed of small round and spindle cells. In other parts of the growth these large cells are scattered about without any definite arrangement or relation to the young, ill-developed connective tissue, *i. e.* without any definite alveolar arrangement.

Again, in another part these large cells are scattered irregularly in a retiform tissue, resembling the medullary tissue of bone. The resemblance is still further shown by the presence of large masses of protoplasm, some of which are similar to myeloid cells, whilst others show a faint differentiation into separate cells around the nuclei. In still another part of the same section will be seen a bundle of small spindle-cells.

Considering the great variety of cells seen in this specimen, and the presence throughout of embryonic connective tissue, I think we must look upon the case as one of sarcoma, and as the alveolar arrangement rather predominates, it might be called an alveolar sarcoma.

The bladder tumour presents on section quite a different appearance. It is chiefly composed of round and oval cells of varying sizes, such as are seen in a round- and oval-celled sarcoma. None of them approach the size seen in the tumour of the skull, nor

are they grouped together in a similar fashion, but there is a faint indication of an alveolar network.

Microscopically these two tumours present some difficulties, and I have brought them forward in the hope that others may, perhaps, express more decided views (1) as to their relation to one another, and (2) as to their position in the nomenclature of tumours.

Clinically, the tumour of the bladder might well be a secondary growth, as there were no symptoms during life; and microscopically, for myself, I think its structure, although differing greatly from the tumour of the skull, is not inconsistent with that view of its origin. *March 20th*, 1883.

Report of the Morbid Growths Committee on Mr. Clutton's case of tumour of the skull.—We have no hesitation in agreeing with the opinion of Mr. Clutton, that the tumour submitted to us has the characters of an alveolar sarcoma, and not of an epithelioma. Independently of the fact that the clinical history of the growth is inconsistent with its epithelial origin, we believe that no doubt should be entertained of its true nature after a careful examination of the microscopical specimens.

The larger cells, which are very unequal in size and shape, and often possess more than one enormous nucleus, are in most places certainly arranged in groups or masses, separated more or less distinctly from one another by strands of very imperfectly-developed connective tissue—an arrangement which, under a low magnifying power, has a close resemblance to that of a cancer; but when more highly magnified it appears that the separation between the two main elements of the growth is most indefinite. At the edges of the groups or masses the two are found intimately blended together, while at other parts, again, there is no alveolar arrangement at all. It may be taken as a confirmation of this view that some parts of the tumour present a structure closely resembling that of cartilage.

The arrangement of sarcoma elements on the alveolar type may be, perhaps, considered accidental, as is, we conceive, illustrated by Mr. Clutton's specimens; for it can hardly be doubted that the tumour in the bladder is genetically related to that of the skull. One of us has in his possession sections of two tumours of the thigh, one of which is a typical alveolar sarcoma, and the other a

typical round-celled growth; yet both were developed in the same limb, and at the same time, as recurrences after the removal of a sarcoma from the heel.

MARCUS BECK,
April 30th, 1883. RICKMAN J. GODLEE.

---

13. *Sarcomatous blood cyst of spine, causing paraplegia.*

By W. H. KESTEVEN.

THIS case is that of a clerk in an army agent's office, aged 35. He was a tall, scrofulous-looking individual, with a decided stoop. He sent for me to see him on account of severe pain in the hypochondrium.

His history was that about three months before my seeing him he had had a blow on the back, which at the time caused him great pain. This, however, passed off, and he noticed nothing wrong for about a month, when he began to feel ill, and pain in the right side came on. He went on with his occupation as long as he could, being under medical treatment meanwhile.

This history was elicited from him after an examination of his case had led me to suspect spinal mischief. The pain of which he complained was in the right hypochondrium, and seemed to be more of a neuralgic nature than due to hepatic mischief, although there was increased hepatic dulness and some amount of flatulent distension of the abdomen.

On examining his back I found that the spinous processes about the eighth dorsal vertebra were much displaced, and there was tenderness on pressure.

Shortly afterwards he found that he had great difficulty in walking. On examining his legs they were found to have lost some voluntary power and cutaneous sensibility, but that the patellar tendon-reflex and the ankle clonus were rather exaggerated. From this time his paralysis increased. This was more marked in the right than in the left leg; the reflex irritability was exaggerated in both legs, and they were liable to severe jumpings.

From the time when the paralysis of the limbs became confirmed,

he commenced to pass his motions involuntarily but not frequently; he had considerable painful flatulence; the motions also were grey in colour. He also lost the power of voluntary micturition, it being necessary to use a catheter. After a while the bladder became inflamed, and the catheter was obstructed by the quantity of blood and pus which collected, with a decidedly scanty amount of urine in the bladder.

For a week or so before his death large bedsores formed on his buttocks and thighs, from which however he experienced no pain, although the tissues were destroyed deeply enough to expose the femur.

Taking the view, confirmed by Dr. Ferrier on consultation with him, that in this case there was some inflammatory thickening around the cord causing pressure thereon, it was determined to try the effect of the actual cautery. This, however, and all other remedies, failed to give relief. He had several severe rigors, rapidly lost flesh, and finally died in about four months from the time that he received the blow.

On examining the back after death the seventh dorsal vertebra was found out of place. A portion of the column, from the fourth to the eleventh vertebra, was removed. Around the seventh, beneath the pleuræ on each side and adherent thereto, was a tough swelling, completely covering the vertebra. It was of a dark colour and slightly lobulated.

The spinous processes were removed, and the spinal cord lifted out. The seventh dorsal nerves gave way while the cord was being removed, being utterly softened. The other spinal nerves required cutting. At the seventh dorsal vertebra the spinal canal was much narrowed, and the cord compressed by the tumour, which seemed to penetrate between the bodies of the vertebræ. The swelling had extended round the canal, between the bone and the common ligament, and consequently in cutting away the spinous processes the mass was cut into. The section showed that it consisted of what appeared to be extravasated blood in a partially coagulated condition. The spinal cord was placed in a solution of chromic acid and reserved for examination.

The tumour in the front of the vertebræ covered the bodies of the sixth, of the seventh apparently, and of the eighth vertebræ. But on sawing through the bodies of the vertebræ in a vertical direction it was found that the body of the seventh

had entirely disappeared. Between the sixth and eighth vertebræ were two layers of intervertebral cartilage.

On dissecting further it was found that the heads of the seventh and eighth ribs were in contact on either side, each more or less

WOODCUT 8.

necrosed and deeply stained with infiltrated blood. No trace of the seventh dorsal pair of nerves could be found.

Anteriorly the sympathetic ganglia were unaltered, but the rami communicantes between the seventh dorsal spinal nerves and the seventh pair of ganglia were destroyed, the ganglia themselves being forced forward into the posterior mediastinum by the hæmatoma, on the surface of which they may be seen in the specimen I have sent round.

Numerous sections of the cord were made, and stained with various reagents.

With the exception of some softening which rendered the making of the section rather difficult, and which chiefly affected the posterior roots of the nerves in the substance of the cord, no signs of general degenerative or inflammmatory change were discoverable.

The nerve corpuscles and the connective tissue, both in the anterior cornua and in the posterior vesicular columns, were quite healthy.

About the commencement of the lower third of the dorsal portion of the cord there was marked atrophy of the left anterior cornu of the grey matter, and the number of nerve corpuscles was diminished in comparison with the right cornu.

From inquiries which I made among the patient's relatives I elicited certain facts which led me to conclude that the spinal column had been distorted or curved to some extent for his whole life, and it would seem that the blow on the back which he received actually caused some amount of movement of the already distorted vertebræ, this not being accompanied with much further displacement, but causing the rupture of some small vessels. The subsequent growth of a sarcoma at this part had affected the spinal cord by the pressure it exerted.

Practically it was as though a transverse section of the cord had been made in the middle of the dorsal region, entirely shutting off all connection with the centres concerned in voluntary motion or conscious sensation, and leaving intact the simply irritable and reflex centres below the point of injury. The difference being that in this case the pressure had simply shut off the nervous current without interfering with the nutrition of the conductors of that current, or only so to a very limited extent. The absence of signs of degenerative change in the nervous elements would seem to show that the diminished size of the left anterior cornu was of old standing, probably contemporaneous with the original curvature of the spine.

One other feature of the case was interesting, viz. the disturbance of the sympathetic nervous system, or rather of the solar plexus and its offshoots, as evidenced by the altered condition in the hepatic secretion, the diminished peristaltic action of the intestines, and the scanty secretion of urine. The actual conditions giving rise to these symptoms were a vitiated condition of the tone of the hepatic and renal vessels, and a loss of power on the part of the circular muscular fibres of the intestines.

It is of course difficult to separate the results respectively due to disturbance of the sympathetic and of the cerebro-spinal system; but we may fairly conclude that the destruction of the rami communicantes of the ganglia would cause impairment if not practical obli-

teration of the functions of those ganglia. This impairment of the sympathetic influence would be transferred by the splanchnic nerve to the solar plexus, and, disturbing at that point the balance between the sympathetic and the cerebro-spinal inhibitory influence, would give rise to the retardation of peristaltic action, and the disturbance of the circulation in the liver and kidneys which we saw in this case. *November 7th*, 1882.

Report of the Morbid Growths Committee on Mr. W. H. Kesteven's specimen of blood-cyst of the spinal column.—The specimen submitted to us consisted of a portion of the spinal column taken from the centre of the dorsal region. In the middle of the preparation (Woodcut 8), two intervertebral substances are in contact with one another, or at most are separated behind by a little of the dark material, to be presently described, which in this situation contains minute spicula of bone. It is thus clear that the body of one vertebra is absent. The spines of one vertebra have been removed.

In this part of the spinal column, is a tumour of considerable size, limited by a dense fibrous capsule. Anteriorly it forms a mass, half an inch thick at the thickest part, which has separated the anterior common ligament from the two vertebræ which are now in contact with one another, but does not extend beyond the

WOODCUT 9.



intervertebral substances which limit them respectively above and below. Posteriorly it forms a mass a quarter of an inch thick which projects into the spinal canal, but does not extend more than

half way along the bodies of the two contiguous vertebræ. On the left side the mass appears to be about three quarters of an inch in thickness and is almost regularly circular in shape, though at the lower part a small knobby projection exists. There has apparently been a similar but smaller mass on the right side which has been removed.

The structure of the tumour to the naked eye has very much the appearance of altered blood-clot, it is of a dark reddish-brown colour, but is very spongy in texture and is traversed by numerous fibrous trabeculæ. It has evidently partly involved the intervertebral substances referred to, as they are dark in colour, fibrous in appearance, and have lost their natural elasticity, for they do not bulge on section in the usual manner.

The microscopical structure was investigated from sections taken from the cut surface. It is clearly that of a sarcoma, consisting in parts of an almost pure spindle-celled growth, but mostly of cells of various shapes and sizes, round, oval, and spindle shaped. In other parts of the mass sections of the fibrous trabeculæ are met with; they are made up of ordinary fibrous tissue, and a finer fibrous stroma pervades the mass. In other parts again the sarcoma cells are separated by masses of yellowish-brown pigment, and in others by altered blood-clot.

Many of the vessels are filled by plugs of a material which stains with logwood and which, on examination with a high power, is seen to consist of masses of minute micrococci. Without venturing to express an opinion on the cause of the symptoms described by Mr. Kesteven, we would submit that this is probably evidence that the patient, before his death, was the subject of some septic infective process.

We append drawings (both naked eye and microscopic) to illustrate our description. (Woodcuts 8 and 9.)

MARCUS BECK.

Jan. 8th, 1883. RICKMAN J. GODLEE.

14. *A case of comminuted fracture of the tibia, with impaction of the anterior tibial vessels and nerve, followed by gangrene.*

By F. Swinford Edwards.

This specimen was taken from a woman who was deaf and dumb, aged 67, and who had sustained a comminuted fracture of the right tibia, having been run over by a van. The anterior tibial vessels and nerve are caught between the fragments of bone and thereby compressed. This in time led to gangrene of the foot and lower part of the leg, and for which amputation in the upper third of the leg was performed.

The history of the case is as follows:

The patient was admitted into the West London Hospital on the evening of October 23rd with a fracture of the right tibia at the junction of the lower and middle third. There was some bruising about the part, but very little displacement. The foot was warm and the patient not suffering much. The leg was placed on a McIntyre splint, and lead lotion used to the seat of injury.

On October 25th small bullæ appeared on the foot and lower part of the leg.

On the 28th, five days after the accident, symptoms of gangrene set in, viz. discoloration and coldness of foot.

By November 2nd a line of demarcation was formed about two inches above the seat of fracture, and through one of the broken bullæ a probe could be passed down to the bone. About this time a bedsore formed over the left buttock.

On the 4th I amputated just below the knee without the spray, though employing Lister's dressings.

The temperature two days after the operation became normal, it never having risen above 101°. The flaps united well, with the exception of a small piece of one, about an inch square, which sloughed. The bedsore becoming larger the patient was slung on canvas with an aperture over the buttocks.

No bad symptoms occurred till the 12th December, more than a month after the operation, when her appetite began to fail her, and

sickness set in. Soda-water and hydrocyanic acid were given with marked benefit, the patient being much better on the 14th.

Death occurred suddenly at 11 p.m. on the following day.

The *post-mortem* revealed fatty degeneration of the heart, liver, and kidneys. There was extensive atheromatous disease of the aortic valves and arteries (the patient had a slight aortic murmur at the time of the operation). Calcification of the arteries was well marked, especially of the abdominal aorta, which for about two inches and in its entire circumference was occupied by a calcareous plate as hard as a stone.

The lungs and pleurae showed signs of former inflammatory mischief.

Fibrinous blood-clots were found occupying both the pulmonary arteries and the abdominal aorta at the seat of the calcareous plate.

The body was well nourished.

The dissection of the leg after its amputation showed, in addition to the occlusion of the anterior tibial vessels, extensive extravasation of blood at the back of the leg, under the deep fascia, pressing upon the posterior tibial vessels.

The middle metatarsal bone was also found to be fractured.

May 15*th*, 1883.

---

15. *Fracture of sternum, with costo-chondral dislocation.*

By W. Arbuthnot Lane, B.S.

[With Plate XV.]

I have no history of the injury, as the specimen was obtained from the dissecting room. The sternum presents at the back, at the junction of the first and second pieces, a circular boss of bone having a diameter of three quarters of an inch, and a thickness of one third of an inch. It evidently indicates that the sternum has been fractured transversely at this point, and there has been no displacement of fragments.

None of the ribs or vertebrae were fractured.

The second and third left costal cartilages have been dislocated backwards from the ends of the ribs. There is a thin covering of cartilage on the ends of the ribs, showing that the condition is

rather one of fracture of the outer extremity of the cartilage than of true dislocation. The cartilaginous end is unchanged. The displaced extremities of rib and cartilage are bound to one another by bone, processes of which project upwards and downwards to the adjoining articulations, having been bound to them and to each other by dense ligamentous tissue. The pleura over this area was also thick and cartilaginous.

Extending inwards from the costo-chondral articulations along the upper and lower borders of the cartilages is much irregular bony growth. Bone also sheathes many of the inner extremities of the cartilages.

This, I think, shows that many of the cartilages were fractured at their junction with the ribs, but that the extremities had not been displaced. I find few published cases of this form of dislocation. The late Mr. Poland in his article in 'Holmes's System' published four instances, one of which was a very interesting one, related by Sir Charles Bell in his 'Surgical Observations,' in which all the ribs were dislocated from their cartilages by the thorax being compressed between two objects. With the exception of this case, the injury has been limited to the lower true ribs, the second suffering in no instance.

I will now refer more particularly to the condition of the cartilages of the first ribs, which are sheathed in bone.

On examining their surface I found on the right side apparently two articulations, by means of which the inner extremities of the cartilage could be rotated slightly at right angles to the axis of the end of the rib.

On the left side there was one articulation, which allowed of more movement than those on the right side.

On making sections of these cartilages I found on the right side the cartilaginous core continuous and surrounded by a sheathing of bone, which was thicker and divided at the seats of articulation (or rather of movement), the ends being united to one another by ligamentous tissue, each forming a mixed articulation.

On the left side the bony capsule was divided in only one place, but the cartilaginous core was also divided, and a complete arthrodial joint was formed, explaining the free movement on this side.

On making sections of many first costal cartilages that had become sheathed in bone I found—

DESCRIPTION OF PLATE XV.

Illustrating Mr. Arbuthnot Lane's Case of Fracture of the Sternum. (Page 224.)

From drawings by Mr. Lane.

FIG. 1.—Posterior surface of sternum.

FIG. 2.—Vertical section through first rib and cartilage of an elderly man, showing a complete arthrodial joint with a thin fibrous capsule allowing of free movement.

FIG. 3.—Vertical section through right first rib and cartilage of the same subject. On this side the cartilage is not completely divided at the back part. Where continuous it has lost its cartilaginous appearance and consistence, and become fibrous, allowing of very free movement.

FIG. 4.—Horizontal section of the same rib, showing the incomplete division of the cartilage at the back part of the joint.

FIG. 5.—Horizontal section of a right first rib and cartilage, showing incomplete articulations, the cartilaginous core being continuous.

FIG. 6.—Vertical section through left first rib and cartilage, showing a complete arthroidal articulation.

Fig. 1.

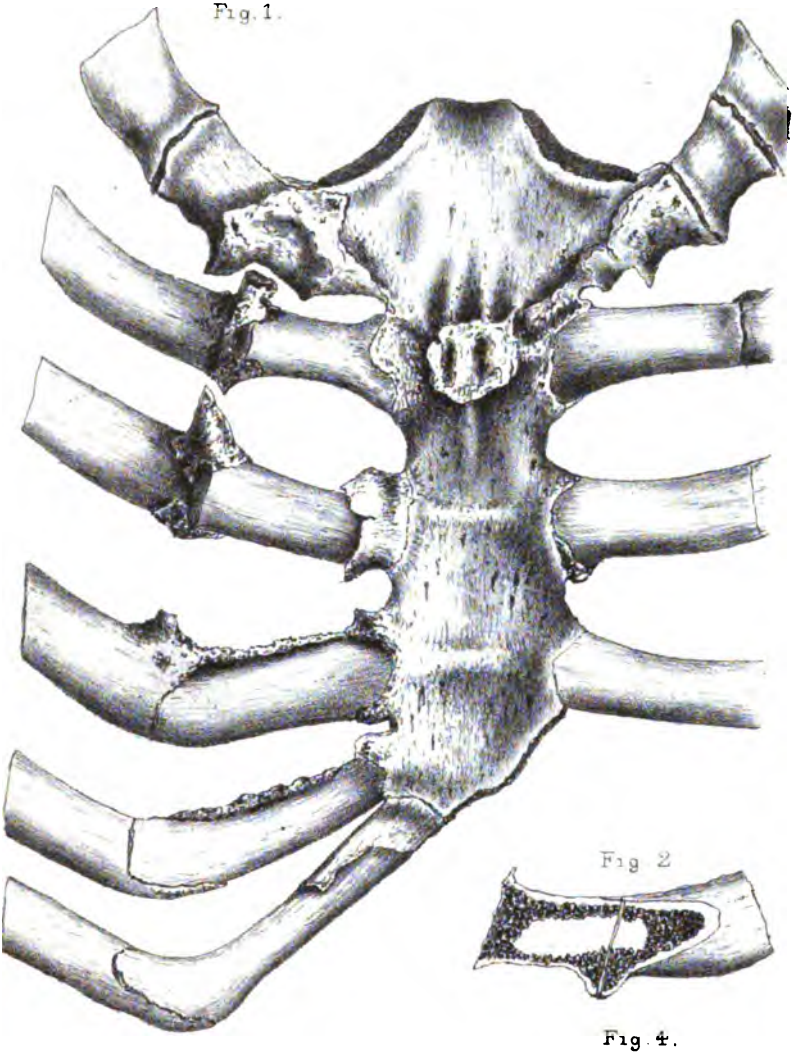

Fig. 2

Fig. 4.

Fig. 3.

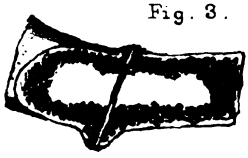

Fig. 5.

Fig. 6

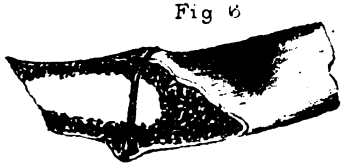

W.A.L. del.

West, Newman & Co. lith.

1st. That the first costal cartilage never becomes completely sheathed in bone without the formation of some kind of articulation to compensate for the absence of the flexible cartilages, and to allow of the slight rotation which must occur in it on account of the movements of the sternum in respiration.

2nd. That there may be one or more mixed articulations, as in the right costal cartilage in the specimen shown, or there is a more or less complete arthrodial joint, as in the left cartilage.

3rd. The division of the cartilage appears to ensue after the formation of the outer or bony part of the joint, and to proceed from before backwards, so that in some cases the cartilage is seen incompletely divided.

4th. The arthrodial joint occurs more frequently on the left side than on the right, and is always more perfect on that side.

I have made sketches of each form from specimens in the dissecting room.

I find no reference to this condition in any of the anatomical works. A similar arthrodial joint is formed in the cartilages of the lower true ribs when calcified.

From the large amount of irregular bony deposit on the first costal cartilages in this specimen, it would appear that they had suffered some injury at the time of the accident, but what the condition then was would now be difficult to decide. *March 6th*, 1883.

---

16. *Elbow-joint from a case of scarlet fever.*

By NORMAN MOORE, M.D.

THE joint was that of a girl, aged 6, who died of scarlet fever, under the care of Dr. Gee, in St. Bartholomew's Hospital.

Desquamation was in progress at the time of death. There were no abscesses about the fauces and no disease of the ears. There was a small pneumonic (but not suppurating) tract in one lung, but there was no inflammation of the pleuræ or of the meninges. Slight pericarditis and general peritonitis were present. In each kidney there was an infarct, and that in the left was

suppurating. There were some minute growths on the mitral valve.

Both elbows and the terminal joint of the right forefinger were swollen and contained pus. The left elbow (the one exhibited) was full of pus. The synovial membrane was thickened, and showed roughness in two places and one narrow adhesion.

The child had been taken ill on September 28th. On October 10th she had rheumatic symptoms which rapidly became worse. On admission to the hospital on October 19th, both elbow-joints were found to be much swollen. The temperature was 100° on admission, and twice rose to 104·9°. The child grew weaker and died on October 23rd. The case in its anatomical features was clearly pyæmic, and is of interest in its bearing on the question of the nature of scarlatinal rheumatism. *December 5th*, 1882.

---

17. *Rheumatic arthritis from a Roman tomb.*

By Norman Moore, M.D.

Vertebræ from a Roman tomb, discovered in 1877 in digging the foundations of the library at St. Bartholomew's Hospital.

The vertebræ are the lower dorsal and upper lumbar, and show lipping of the edges of the centra, irregularity on the intervertebral surfaces, and in some places ankylosis with considerable formation of osseous tissue. There was nowhere any loss of substance. The middle of the three vertebræ belonging to the dorsal region showed bony union on both sides. Lower down, though the centra were lipped on both sides, there was bony union on the right side only.

The skeleton to which the bones belonged was entire and lay in a stone sarcophagus preserved at St. Bartholomew's. Della Chiaje has described rheumatic arthritis as shown by bones found at Pompeii, but the St. Bartholomew's tomb, ascribed by antiquarian authorities to the fifth century, perhaps furnishes the earliest example of the disease in England. *March 6th*, 1883.

18. *Abnormality of bones and muscles near the shoulder-joint.*

By C. B. Lockwood.

The specimen was obtained from a body brought for dissection. The subject was a female, aged about 45. No history could be obtained. The left shoulder presented the following abnormality:—Attached to the external surface of the surgical neck was a process of bone about an inch and a quarter long; it extended upwards to give attachment, by its apex, to the infra-spinatus. The teres minor passed partially beneath the process to be attached to the neck of the humerus, partially to the posterior edge of the process. The supra-spinatus muscle did not appear to be attached to the humerus at all, but was inserted into the capsule of the joint. The long head of the biceps did not exist within the joint, but was fastened to the margins of the bicipital groove. The greater tuberosity of the humerus was deficient. The scapula presented no abnormality. The capsule of the shoulder-joint was considerably thickened, as if by inflammation. The articular cartilages were slightly eroded and fibrous, presenting the appearance commonly met with in rheumatoid arthritis. It may be remarked that there had been a fracture of the left humerus.

Taking into consideration the absence of the greater tuberosity, and the way in which the muscles were attached, it seemed possible that the greater tuberosity had been broken off and afterwards become united by bone. *Feb. 20th*, 1883.

---

19. *A peculiar bony outgrowth from the fibula.*

By W. Hale White, M.D.

The fibula exhibited to the Society was taken from a dissecting-room subject. About an inch from the upper extremity of the bone, on its internal surface, there is a bony process just above the oblique line. This projection is an inch long, a quarter of an inch wide at its origin, a trifle wider at its extremity; it

is directed downwards and inwards, flattened and twisted on itself, so that whilst its surfaces at first look chiefly forwards and backwards, towards its termination they look mostly inwards and outwards. It consists principally of cancellous, with a thin layer of compact tissue outside this; its free extremity was tipped with cartilage in the recent state, and it lay embedded in the soleus muscle, some of the fibres of which arose from it. At its origin there is a sort of groove between it and the fibula on its anterior surface, but no vessels or nerves lay in this. As far as I know, this is a unique specimen, there being no mention of it either in the ordinary text-books, 'Henle's Anatomie,' or in Professor Flowers' 'Osteology of the Mammalia.'

Comparative anatomy does not, I believe, help to explain its presence, as there are no animals in which it is a normal process; in fact, it would seem to be nothing more than an excessive development of the rough surface usually present for the attachment of the fibres of the soleus. *March 6th*, 1883.

---

20. *Congenital malformation of the skull.* (*Card specimen.*)

Exhibited by FREDERICK TREVES.

THAT part of the vault of the skull formed in membrane appears to be entirely absent. The scalp is represented by a thin membrane, resembling that seen in some cases of spina bifida. There is a median fissure in the head (? longitudinal fissure of brain), at the bottom of which the base of the skull can be felt.

The child lived twelve hours. It had external strabismus of both eyes, free movements of the arms, but no movements in the legs. It died cyanotic. Pressure upon the vertex produced stertor, &c.

Nov. 7th, 1882.

21. *Bossy calvaria.* (*Card specimen.*)

Exhibited by D. B. LEES, M.D.

IT exhibits the swellings of the frontal and parietal bones ("bosses"), which often occur in syphilitic infants. The centres of ossification are, as usual, spared.

On the under surface of the posterior part of the right parietal bone are two or three small circular pits of craniotabes.

It was taken from an infant of fourteen months, under treatment on account of very numerous convulsions and attacks of laryngismus.

The father admitted having suffered from gonorrhœa and from chancre, but denied secondary symptoms. *Dec. 5th*, 1882.

22. *Dry caries of the knee-joint.* (*Card specimen.*)

Exhibited by H. A. LEDIARD, M.D.

THESE portions of bone were removed from a youth who, three and a half years previously, had fallen and injured the joint.

At the time of excision there was starting at night, and subluxation, together with fixation at a right angle. There was no scar or trace of sinus about the joint, and no discharge had ever come away.

The patella for three quarters of its articular surface is carious, the upper border of the bone being fringed with slender osteophytes; the rest of the under surface is in a porous condition; the bone was semi-fixed to the external condyle.

The external condyle of the femur is considerably ulcerated, exposing the cancellous structure both widely and deeply; the posterior extremities of both condyles are also excavated where they came in contact with the tibia; elsewhere the femoral articular surface is porous.

The condyloid surfaces of the tibia are wholly diseased, the inner one being deeply hollowed out.

At the operation no pus or fluid escaped from the joint, neither was there any trace of pus remaining, and it would appear that the extensive destruction of the joint had been associated with absorption of the products of inflammation, such a condition as is recognised by Virchow and Volkmann as caries sicca.

April 3rd, 1883.

VII. DISEASES, ETC., OF THE ORGANS OF SPECIAL SENSE.

1. *One-sided anophthalmos in an infant (living specimen).*

By Rickman J. Godlee, M.S.

The patient exhibited is the subject of a rare congenital deformity known as *one-sided anopthalmos*. It was brought to me by the mother at the North-Eastern Hospital for Children six weeks ago. It is now fourteen weeks old, and is well formed in every particular, except that the globe of the left eye appears to be completely absent. The orbit on the left side is as good as the right, which is quite normal; the lids also are well formed and present papillæ lachrymales and puncta lachrymalia, and a complete set of cilia. They appear, however, to be shrunk, from the absence of the supporting eyeball, and are occasionally inverted, so that the lashes project inwards and cause some inconvenience to the patient. The palpebral fissure leads into a deep slit lined by rather red conjunctiva, and showing at the bottom a little whiteness, which, it has been suggested, may correspond to some sclerotic tissue; there is no projection as of a dwarfed globe, however; and the only part at which anything resembling this is to be felt is beneath the lower lid. The orbicularis palpebrarum is well developed, but it is impossible to say anything about the ocular muscles. There is reason to believe that the lachrymal gland is absent or deficient, as, when the child cries tears flow only from the right eye.

The eye was not opened till the child was six weeks old, and up to this time there had been no discharge. After this a thin mucopurulent secretion was seen for some time, which was subdued by bathing the part with boracic acid lotion; and now there is little or none at any time.

The term *one-sided anophthalmos* may be criticised as implying

to some extent an hybernicism; but, notwithstanding, I think it is the best to apply to such cases. *Monophthalmos* suggests itself as a more suitable name, but this includes equally, and applies better to, the comparatively common Cyclopean monster, which has one median organ of vision, formed by the fusion of two eyes, while the palpebral fissure is obviously made up of three or four eyelids amalgamated together. These Cyclopses have, I believe, always other extensive defects; the cerebral hemispheres are very small, and there is no corpus callosum, while the greater part of the anterior portion of such cranium as exists is occupied by a large cyst containing fluid. There is also usually a median proboscis or snout, generally over, but sometimes beneath the eye; these monsters seldom or never live beyond a few hours or days.

The term *one-sided anophthalmos* is also a good one because it associates this condition with the commoner cases of anophthalmos, in which both eyes are absent, and thus links it with another class, that of *microphthalmos*, in which the eyes (either from arrest of development or intra-uterine disease) are more or less badly developed or dwarfed.

Cases of *double anophthalmos* present a great variety of conditions. In most of them there is very great cerebral defect, and this of various kinds; in others, the orbits and lids are perfect, as in my case, and in others again the lids are absent and the orbits badly developed, and the skin passes continuously from the forehead on to the cheek. The amount of development of the optic nerves differs much in different cases.

The information about these various conditions I have principally obtained from Dr. Wilde's 'Essay on the Malformations and Congenital Diseases of the Organs of Sight,' 1862, p. 33, and the 'Handbuch der gesammten Augenheilkunde,' vol. ii, part i. In chap. vi, at p. 119, Professor Manz of Freiburg, writing in 1875, was aware of only six recorded cases of absence of one eye. He gives a few details of each case, from which it appears that of the six, three were alive at the time of report, having reached respectively the ages of 3 months, 5 years, and 11 years.

Of the three cases which had been dissected, two presented a more or less considerable amount of cerebral deformity, but the other must have resembled mine very closely; and it is interesting to note that, in this instance, most, if not all, of the ocular muscles

were present, as well as the lachrymal gland. The rest of the orbit was occupied by cellular tissue.

Mr. Nettleship informs me that he has seen two cases presenting an almost precisely similar defect, one of which has been exhibited at the Ophthalmological Society. Another, presumably not one of the patients already referred to, has apparently presented himself recently at St. Bartholomew's Hospital.

It is probably still premature to theorise on the etiology of this peculiar defect, but it may be pointed out that of the two probable methods of causation that have been suggested, one presupposes an arrest of development and the other an early intra-uterine disease of the eye-ball. *February 6th*, 1883.

---

2. *A piece of the petrous portion of left temporal bone, including part of external semi-circular canal and roof of external auditory meatus, which exfoliated from a girl aged* 17 *a year after the removal of a polypus.* (*Card specimen.*)

Exhibited by WALDEMAR J. ROECKEL.

THE specimen in question weighs five grains and measures five eighths of an inch in length and three eighths in breadth. It is of very irregular shape and presents the commencement of the external semicircular canal; a groove at the internal extremity of this marks the common opening of the superior and posterior canals, and below this is seen the quadrilateral surface, which formed part of the roof of the external meatus. The piece of bone exfoliated, and was removed from the external meatus of a girl at Charing Cross Hospital a year after the removal of a polypus under anæsthesia at St. George's Hospital. The only symptoms were *pain* and *discharge*. *May* 15*th*, 1883.

VIII. MORBID GROWTHS AND TUMOURS.

1. *Mediastinal tumour; rapid growth; sudden death.*

By Samuel West, M.D.

W. H. G—, aged 15, a telegraph boy, was in active work until two months before his admission into the Royal Free Hospital. At the time he had a cough, and pain in his left arm, which was thought to be rheumatic. Three weeks before admission his mother noticed a swelling in the chest, a peculiar ring in his cough, and that he suffered much from dyspnœa, and occasionally had a difficulty in swallowing. The patient had been a little hoarse for the last week, and had lost flesh rapidly for a month. There was no history of injury, of rigors, or night sweats. The pain felt in the arm followed the course of the intercosto-humeral nerve, being felt in the upper part of the axilla and along the inner side of the arm as far as the elbow.

On admission, the upper part of the left side of the chest was bulging, and over the tumour the veins were dilated, radiating outwards from the central and most prominent part. The small subcutaneous veins were also dilated, and the skin discoloured as if after a bruise.

Dulness extended over the whole upper part of the left lung down to the fourth rib in the nipple line, becoming continuous here with the heart, and reached an inch to the right side of the sternum.

Over this area the vocal vibration, the vocal resonance, and breathing sounds were absent except immediately under the sternum, where tracheal breathing was audible.

A lump was felt in the episternal notch.

The cardiac apex was difficult to define, but apparently the heart was in the normal position. Pulsation was felt over the whole pericardial region indistinctly, and also slightly to the right of the

sternum in the fifth and sixth spaces. The sounds were normal though distant. In the left interscapular space there was dulness, extending up to the apex of the lung posteriorly, and here there was loud tracheal breathing and direct and increased vocal resonance. The lungs elsewhere were resonant, but the breathing sounds were feeble over the whole left base.

The pulses (both in the carotids and radials) and the pupils were equal. A faint systolic murmur was audible in the lower part of the left interscapular space and also in the axilla, but this was only occasionally there. There were no other physical signs elsewhere.

The patient preferred to sit half up, with his head inclined to the left shoulder. He suffered much from a dry hacking cough, with occasional stridor.

Though the diagnosis of tumour was the most probable, it was still thought possible that the symptoms might be produced by a localised collection of fluid, and accordingly four days later a trocar and canula were passed into the second intercostal space an inch and a half from the left border of the sternum, but nothing was obtained except a few drops of blood.

At the end of a week the tumour had much increased. The lump in the episternal notch was much larger, and a small boss had developed on the anterior part of the prominence of the tumour. The left pulse was found to be smaller than the right two days before death.

The patient had two or three paroxysms of dyspnœa and occasional paroxysms of pain; both were relieved by subcutaneous injection of morphia.

Fourteen days after admission the patient died, being attacked with a paroxysm of dyspnœa, becoming comatose and dying rapidly.

Post-mortem.—The diaphragm on both sides reached just below the fifth rib. In the second intercostal space on the left side corresponding with the prominence, was a soft cellular growth, continuous with a large mass, nearly the size of the boy's head, occupying the mediastinum. This mass extended chiefly towards the left side, the upper lobe of the left lung being adherent to it, and the contiguous edge involved in the new growth. The growth was pitted to receive the sternal end of the clavicle, and rose into the episternal notch and into the left supra-clavicular fossa. The brachial plexus and vessels of the left side, subclavian and carotid

arteries, the jugular and innominate veins, were completely embedded in the tumour. The left bronchus and the left side of the lower part of the trachea were almost completely flattened out.

The left phrenic and left pneumogastric nerves passed through the mass, and on dissection were found to be much thickened as they ran through the tumour. The pneumogastric measured nearly three times its diameter here, and was pushed aside out of its course, being separated nearly one inch from the carotid. The recurrent laryngeal was similarly thickened as it turned round the aorta, this vessel also being surrounded by the new growth.

The right pneumogastric and phrenic nerves, and the blood-vessels, were only pushed aside and not involved.

The heart was pushed down and in great measure concealed in front by the tumour. It was flattened from above downwards, between the tumour and the diaphragm.

The pericardium contained a few ounces of puriform fluid. Several nodules of new growth were found upon the heart, but not in distinct relation with the vascular supply. They were most numerous on the anterior surface and in the transverse sulcus. Some nodules were spread along all the great vessels (both veins and arteries). These growths lay under the pericardium, which was not inflamed or thickened over them, and they did not involve the muscular substance.

There was no secondary deposit in the lungs, the only part of these organs which was affected being the margin of the left upper lobe, into which the tumour had spread by direct extension.

The spleen and liver were not affected.

In both kidneys secondary growths of small size were found. There was no enlargement of the lumbar glands. The mesenteric were a little large, but not from new growth.

The tumour was microscopically a round-celled sarcoma, and the pneumogastric thickening was found to be due to an infiltration of the nerve by a similar small round-celled growth.

The points of interest in this case are these:

1. The age. The average age given in Reynolds' 'System of Medicine,' by Dr. Douglas Powell, is 24·8 years, and in the cases of Eger quoted in Ziemmsen, out of 55 cases only six were below twenty years, five of them between ten and twenty, and one under ten years of age.

2. The duration, which we may in this case assume to be not

more than two months and a half. This is an extremely short time for so large a tumour to have developed. Virchow quotes one case in which the duration was only two months, and Jaccoud another in which the case terminated in eight days from the first development of symptoms. Walshe mentions three months and a half as the minimum duration in his cases.

3. The thickening of the nerve, was found to be due to a sarcomatous infiltration, and not as in Dr. Quain's case ('Path. Trans.,' vol. xix), to a fibroid induration.

4. The commencement of the case with the symptom of intercosto-humeral neuralgia. *October* 18*th*, 1882.

---

2. *A case of disseminated sarcoma.*

By W. B. Hadden, M.D.

The patient from whom these specimens were taken was a gentleman, aged 38, who was admitted into St. Thomas's Home on the 11th of April, 1882.

A few weeks before admission he had been operated on by Mr. Lister for fistula in ano. His recovery was somewhat protracted. According to the statement of his friends he had for a long time complained of occasional pains in the region of the heart.

On admission into the Home he was dull and heavy, but complained of nothing. There were no physical signs of disease, and the wound in the sphincter ani was quite healed.

During the next few days the dulness and drowsiness increased, and low muttering delirium with partial unconsciousness set in. He was seen, in consultation, from time to time by Dr. Bristowe and Dr. Savage.

Two days before death some œdema of the legs was observed, and the pulse became very rapid.

The temperature for the first four days was moderately elevated, and had an intermittent character. For the next three days it was about normal. The day before death there was a slight evening rise. The highest temperature was only 101·2°. Repeated exami-

nations failed to reveal any organic disease, and there was no optic neuritis.

The patient died comatose on the tenth day after admission.

The *post-mortem* examination revealed the following state of affairs:

The visceral and parietal layers of the pericardium were studded with numerous, slightly-raised, round white masses of new growth, varying in size from about one to three lines in diameter. Some of these were distinctly depressed in the centre.

Similar growths were seen in large numbers throughout the whole of the muscular substance of the heart and on the endocardium. The valves were healthy.

The parietal layers of both pleuræ showed similar masses, but there were none on the visceral layers and none in the lungs, which were quite healthy.

The mediastinal glands were not enlarged.

The new growth was found also on both surfaces of the diaphragm, in the mesentery, omentum, and on the peritoneal surfaces of bladder and rectum.

In the liver and spleen there were several subcapsular growths, resembling miliary tubercles. In the liver a few were seen on section. The right kidney presented a very curious appearance. The capsule was studded with numerous dull white masses, which were depressed in the centre, and surrounded by an elevated ring of gritty material. By treating sections of the kidney with hydrochloric acid this gritty material was found to be of a calcareous nature.

Sections were also examined by polarised light, but nothing more definite was revealed.

The left kidney showed a few small masses resembling miliary tubercles, both beneath the capsule and on section.

In the arachnoid over the upper surface of the brain there were several small bodies like tubercles, but which were apparently only local thickenings, and not new growths.

None of these masses were seen at the base. The vessels, both superficially and within the brain, were injected, but there was no sign of meningitis.

The fistula in ano was practically healed, there being only a little superficial erosion and congestion of the mucous membrane just within the anus.

The intestines were healthy, and there was no enlargement of glands.

Microscopical examination showed that these masses, which were so universally distributed, were really of the nature of round-celled sarcoma. But there were certain peculiarities in the growth, especially as it existed in the right kidney, which call for some remark.

In the *heart* the cells were for the most part round; some were irregular and some fusiform. Most had a single nucleus, but a few had two nuclei. The matrix was amorphous, in some parts very faintly fibrillated. The cells ran up in tracts in the intervals between the muscular fibres. In some places there was a distinct arrangement in alveoli.

In the liver the round-celled growth was interlobular. Some of the hepatic cells at the periphery of the lobules were distinctly fatty.

The capsule of the right kidney was seen to be very irregular.

Immediately subjacent to the capsule was an extensive infiltration of round cells, which passed downwards in tracts between the tubules. In the cortex there were also found rounded cavities with very thick and deeply-stained walls. These cavities were, at any rate in some places, the thickened capsules of the Malpighian bodies and the thickened walls of tubules.

It seems to me probable that the matrix in which the cells are embedded has in some places undergone calcareous degeneration. According to Rindfleisch this is most apt to occur at the periphery of cell districts. Such appears to have been the case in the present instance. The explanation of the fact I do not attempt to give. It is also probable that the right kidney was the original seat of the new growth, and that the changes existed there perhaps weeks or months before the onset of the symptoms.

The following points seem worthy of remark in this case:

In the first place, this gentleman had suffered some weeks previously from anal fistula, and both on that account, and also because of the vagueness of the symptoms, the case was thought likely to be one of acute tuberculosis. To the naked eye, indeed, this seemed not improbable after death. The microscope, however, showed that this was not so.

Secondly, I would call attention to the extremely acute onset of

the symptoms, barely a fortnight elapsing between the beginning and the end.

Thirdly, I must notice the tendency to arrangement in more or less rounded cell groups, and the very peculiar condition of the right kidney. *Nov. 7th*, 1882.

Report of the Morbid Growths Committee on Dr. W. B. Hadden's specimen of Disseminated Sarcoma.—The heart, a portion of the arachnoid, and a portion of the right kidney, all preserved in spirit, were submitted to us for examination, together with excellent microscopical sections of the substance of the heart, the liver, and both kidneys. With the general description of the appearances in the organs given by Dr. Hadden we quite agree, but we have found great difficulty in arriving at a satisfactory conclusion with regard to the real nature of the disease. The distribution and general characters suggested one of the infection tumours; but the only one of these which it closely resembled was tubercle, and the cysts with calcareous walls and the minute structure of the tiny tumours were, as the exhibitor has stated, inconsistent with this hypothesis. One of us was strongly of opinion (Dr. Goodhart) that many, if not all the conditions observed, could be explained by the presence of an animal parasite, and as we could not discover any parasite with which we are familiar, we sought permission to supplement our imperfect knowledge of this branch of pathology by referring the specimen to Dr. Spencer Cobbold. He very kindly examined the microscopic sections, especially of the sacs in the kidneys, and replied as follows:

"I am of opinion that the bodies in question are *psorospermial sacs*. They have a close general resemblance to the organisms of this class, hitherto found within the liver and kidneys of man and various animals, but there are some indications which would imply their specific distinctness from the forms hitherto described. At least they differ considerably from any of the very limited number of psorospermial bodies which I have myself examined."

Some camera drawings of the bodies which were found in the kidney were also submitted to Dr. Cobbold, and he thought that they tended to confirm the opinion he had formed.

Although Dr. Cobbold's examination and report throw great light upon the nature of this most interesting case, the disease is not limited to these parasitic bodies and their immediate effects;

for the microscopic examination of the heart reveals appearances which are not inconsistent with the view which Dr. Hadden took of the whole disease, that of "disseminated sarcoma." In the connective tissue between the muscular fibres are nucleated cells, for the most part round or oval, and two or three times larger than a colourless blood-corpuscle, but varying in shape and size, disposed in irregular groups and cords, and lying generally in a small quantity of intercellular substance. Very little fibrous tissue is present in these cellular masses. In some parts of the kidneys a somewhat similar structure exists, but the cells are generally smaller, and more like leucocytes. We have not observed these characters in the sections of the other organs. It is, of course, possible that these conditions of the heart and kidneys may be another phase of a general parasitic disease, but at present we prefer to regard it as sarcomatous, and possibly an altogether independent affection.

Of the seat and origin of the primary disease, if such existed, we can form no just opinion.

HENRY T. BUTLIN,
Feb. 12th, 1883. JAMES F. GOODHART.

---

3. *A case of disseminated cancer.*

By PERCY KIDD, M.D.

ALBERT O—, aged 55 years, was admitted into the Brompton Hospital, under the care of Dr. Roberts.

The patient complained of cough, expectoration, hæmoptysis and sickness after food.

His history was as follows:

For six years he had suffered from indigestion and epigastric pain after food. Nine months before admission cough, expectoration, and shortness of breath set in. Three months later he became worse and noticed tenderness in the right side. Two months ago he had a large hæmoptysis, and has frequently

coughed up blood since then up to the present time, and has had almost constant sickness after meals, but never hæmatemesis.

His wife stated that for the last month he had been wandering in mind, and had wasted much; and occasionally she noticed some loss of power in his right arm.

It was discovered subsequently that twenty years ago the patient fell down in a sort of fit, but further details were not obtained.

On admission, physical examination revealed signs of disease of the right lung, and a nodular enlargement of the liver. The diagnosis of malignant disease was made.

For three months he lay in a torpid, wandering state, and could rarely give any intelligent answer. At times it was thought there was some loss of power in the right arm and in the right side of the face. He died in a semi-comatose condition.

At the autopsy, hard nodular growths were found in the liver and gall-bladder, pancreas, supra-renal capsules, kidneys and neighbouring lymphatic glands. The pylorus and first part of the duodenum were partially surrounded by a sort of collar of enlarged hard glands, and their walls presented a pulpy, thickened condition, but no ulceration. The duodenum and gall-bladder were glued together by the new growth. Small hard nodules were found in the mucous membrane of the lower part of the œsophagus, but no thickening or ulceration. The bronchial and mediastinal glands were enlarged and extremely hard. Large lobulated cancerous masses, starting from these glands, extended upwards along the trachea towards the root of the neck, and projected above the right clavicle. The mucous membrane of the right bronchus was much thickened, and was beset with numerous firm miliary nodules. The bronchus of the right upper lobe was considerably narrowed owing to the thickening of its lining membrane and to pressure from the enlarged glands. A dense whitish tissue could be seen spreading along the root of the right lung, and starting apparently from the bronchial glands. With the exception of the parts immediately around the root, the right lung appeared free from new growth. In the upper lobe, however, there was some fibroid induration, affecting mainly the lobular and interlobular septa. There were some small cavities, with thin smooth walls, containing pus; and one or two small dilated

bronchi. There was no trace of any caseous infiltration or nodules. The left lung was slightly distended, but otherwise quite healthy. There was no growth in the larynx, but there was well-marked necrosis of the left arytenoid cartilage. A small ashy grey opening over the "processus vocalis" led down to the exposed cartilage. The upper surface of the left lobe of the cerebellum was the seat of a small firm nodular growth of greyish colour. A large cyst, with tough pinkish walls, was found in the left frontal lobe. In addition to the growths in the viscera, there were small, hard, subcutaneous nodules in different parts of the body.

On microscopical examination, the growths in the liver, pancreas, supra-renal capsules, kidney, pylorus, bronchial glands, lung and cerebellum, were seen to be carcinomatous. The harder parts presented the appearance of scirrhus. Sections of the lung in the vicinity of the root showed infiltration of the walls of the bronchial tubes and blood-vessels, but comparatively slight invasion of the lung tissue.

A curious appearance was noticed in some sections of the pancreas, in addition to the carcinomatous disease. In one spot, apparently connected with the new growth, was seen a more or less isolated circular body, about as large as a millet seed on section. This consisted microscopically of a series of regular concentric rings of connective tissue, with numerous nuclei circularly disposed, as in the muscular coat of a small artery. Some of these nuclei seemed as if they had just undergone division. In the middle of this structure was a small cavity lined apparently by an endothelial membrane, suggesting a tubular character. Externally this body was separated from the surrounding parts by a loose sheath of wavy connective tissue. That this body had a vascular origin seems highly probable. It is evidently not an epithelioma-tous globe, the concentric rings are obviously of the nature of connective tissue. Its exact importance and relation to the surrounding new growth are not quite clear, though it would seem to represent a small artery that has undergone some change apparently in its middle coat. This appearance was only found in four or five sections of the pancreas.

The interest of the case lies not so much in the wide distribution of the disease as in the condition of the right lung, in the necrosis of one of the laryngeal cartilages without other disease of the

larynx, in the microscopical appearances above discussed, and in the determination of the seat of the primary disease.

The fibroid induration and cavities were limited to the upper lobe of the right lung. This seems to be explained by the distinct obstruction of the corresponding bronchus, leading to bronchiectasis and fibroid induration. The pleura covering the upper part of this lung was adherent and much thickened. This chronic pleurisy probably contributed to the fibroid induration of the subjacent lung. The laryngeal necrosis was probably the result of perichondritis, but no cause for this was discovered.

In seeking for the seat of origin of the malignant disease, the following facts must be considered:

The hepatic growths were multiple, and the gall-bladder only contained one small nodule. The supra-renal capsules were symmetrically enlarged. The disease of the pylorus and duodenum was evidently recent, and consisted in a uniform carcinomatous infiltration of their walls where they came into contact with the neighbouring cancerous glands. The pancreas and kidneys were comparatively little affected. Primary carcinoma of the mediastinal glands may be excluded.

These considerations show that the primary disease must be sought for elsewhere. In all probability the growth originated in the abdominal glands. *May 15th*, 1883.

---

4. *Multiple ulcerating and sloughing sarcomata in various parts of the body, especially in the limbs.*

By Arthur E. Durham.

John S—, aged 56, was admitted into Guy's Hospital, under Mr. Durham, February 10th, 1872.

Family history good, and previous health good. Had had gonorrhœa and a venereal sore some thirty-five years ago but no secondary symptoms. Married thirty years, eight children. Three years ago a "pimple" appeared on the right leg, gradually

increased in size, scabbed over, and when the scab came off left a raw surface. Under treatment at Margate this nearly healed, but other places formed on the right leg and thigh and both arms, and he has gradually wasted.

On admission.—A fairly nourished and healthy looking man. On the right leg are several brownish stains, irregular, and of different sizes, some scaly but not raised above the surface. On the left leg several nodules beneath the skin, and elevated some half inch above the surface; the cuticle desquamates over them; when close together they coalesce, and in front of arch and inner malleolus are arranged in a semicircular pattern. Over upper part of right tibia a "node" like swelling, and in the calf two similar but more deeply situated masses. About the centre of inner side of left arm a nodule moveable with the skin, and on the right forearm a raised somewhat kidney-shaped ulcer with thick overhanging edges some 2½ by 1½ inches, sloughing in the centre. No scar on penis nor any enlarged glands.

The patient was treated by large doses of iodide of potassium, and then by mercury in different forms, but without effect. The disease continued to spread; fresh tumours formed, one on the lower lip and others on arms and abdomen. After a time these sloughed, so that he became to a great extent covered with the disease in different stages.

On July 9th.—On the left leg there was a large sore reaching from the inner malleolus half way to knee and round to the calf, some 7 or 8 inches by 5; above this, and only separated by a raised rim of skin about half an inch wide, was another ulcer circular in shape, deeply excavated and exposing the tibia, with raised indurated edges. On the foot two similar circular sores, the size of a penny piece. Five or six raised patches on the inner side of the thigh varying in size from that of a penny to a shilling, red and inflamed. On the right forearm the sore is much extended and now more circular. On the abdomen a large open sore the size of a duck's egg, and around it five or six ovoid raised patches, one of which has sloughed.

From this time he rapidly wasted, and died August 13th.

Post-mortem examination.—Body, especially the limbs, more or less covered with manifestations of the disease in different stages. In the early stages as cutaneous or subcutaneous tumours about the size of a hazel nut, not encapsuled. On section reddish and

flabby, having generally the appearance of granulation tissue. Some of the larger ones were mottled with white fleshy matter.

A scraping showed equal sized oval and round nuclei with very bright clear nucleoli, and sections after hardening revealed a typical lympho-sarcomatous structure infiltrating the entire thickness of the skin extending to, and causing separation of the horny layer.

Slight pleurisy and œdematous pneumonia, and superficial ulceration of the larynx. No secondary growths in abdominal viscera. Liver fatty. Spleen large and soft. In left testis a recent nodule of pinkish diseased substance like those in the skin.

Glands of lower limbs enlarged, having the same appearance on section as the tumours.

Wax models showing the appearances presented by the sloughing tumours on the arm and leg were exhibited. Also microscopical sections from several of the tumours, which showed them to be sarcomatous or lympho-sarcomatous in nature.

April 17th, 1883.

---

5. *Extensive sloughing of the neck, "nondescript," ? lympho-sarcomatous tumour.*

By Arthur E. Durham.

[With Plate XVI, fig. 1.]

Alice W—, aged 31, admitted into Guy's Hospital, under Mr. Durham, to whom she had been sent by Sir W. Gull, on June 7th, 1879.

Family history good. Previous health good, except diphtheria when fourteen years old, and jaundice when twenty.

About nine months ago, after sleeping in a damp bed, noticed stiffness and tenderness of the neck, and a few days after several hard cord-like swellings behind the right lower jaw. These increased and were poulticed, and three months ago the largest broke and has continued open ever since.

On admission, there was a large oval ulcer on the right side of neck extending from close to the cervical spinous processes forwards over the sterno-mastoid muscle, which was exposed, deeply excavated, and its surface covered by fœtid, greenish-yellow slough. Edges everted, but not very hard. Skin around hard and tense.

On the left side of the neck was a hard swelling which reached from behind the ear over parotid region. Skin red and tender, and the glands swollen and hard. Under treatment, first by tonics, then by iodide of potassium and mercury, she appeared to improve somewhat in general health, but the ulceration extended.

August 30th.—Surface of ulcer much cleaner, but it has extended deeply under the sterno-mastoid muscle, which stands out in bold relief.

September 6th.—The sterno-mastoid is now ulcerated through, its two extremities hanging loose. Violent diarrhœa set in.

10th.—Death.

Post-mortem.—Adenitis (?) of glands of right side of neck, suppurating and sloughing, terminating in large ulcers, exposing the sterno-mastoid muscle and floor of anterior triangle; thickening of pleura of lower and middle lobes of right lung, which was compressed and œdematous. Liver fatty and lardaceous; capsule thickened and covered with recent lymph in parts. Spleen slightly lardaceous. Irregular masses of enlarged lymphatic glands around upper part of abdominal aorta, behind the stomach and pancreas. Mesenteric and lumbar glands enlarged in conglomerate masses, not caseating or lardaceous, but having more the appearance of hyperplasia than anything else.

A drawing illustrating this case in the earlier stages was exhibited, and has been reproduced in Plate XVI, fig. 1.

April 17th, 1883.

DESCRIPTION OF PLATE XVI.

FIG. 1 represents the appearance of Mr. Durham's case of Lympho-sarcomatous Ulceration of the Neck. (Page 246.)

FIG. 2 represents the appearance of Dr. Frederick Taylor's case of Lympho-sarcomatous Ulceration of the Back. (Page 247.)

From drawings by W. Hurst.

Fig. 1.

Fig. 2.

Mintern Bros Chrom

6. *Sloughing lympho-sarcoma of the back, with other lesions of the skin, and internal organs.*

By FREDERICK TAYLOR, M.D.

[Plates XVI, fig. 2, XXIII, fig. 2.]

GEORGE J—, aged 42, was sent up to me as an out-patient by Mr. Norcott, of Wimbledon, in August, 1882, complaining of weakness of his limbs and difficulty in walking. I was away at the time, and when I saw him on September 8th he was already a little better but still had the following symptoms:—Weakness of the legs so that he was unfit to walk more than a short distance; lateral nystagmus well marked in both eyes; slight tremor of the hands on movement, or in trying to take hold of objects; and imperfect speech, apparently the result of paresis of the tongue and lips, leading to imperfection in labials and linguals, rather than the special kind of high pitched staccato known in disseminated sclerosis.

He was a short man with a big head, with a very large patch of baldness occupying the vertex, left parietal region, and partly the occiput. There was another small patch in front, the hair elsewhere being fairly abundant.

The heart, lungs, and abdominal viscera were normal, and in other respects he appeared healthy, except that his skin presented a condition resembling moderate ichthyosis, which affected chiefly the arms, shoulders, and legs.

He said that, with the exception of smallpox when very young, he had never been ill before. He was single, a gardener by occupation; had never been a drinker, and had never had syphilis.

Towards the end of July, 1882, he began to suffer from vertigo, surrounding objects appearing to move round, and unless he could lay hold of support he would fall. About this time he gradually lost his speech; he knew what he wished to say but was unable to say it, from difficulty of articulation. There was never any definite attack of paralysis or anæsthesia, but weakness of gait and staggering came on, and for these he came up to the hospital. He appeared not to think the alopecia, or the condition of his skin, of

any importance; he said they only occurred at the beginning of this year (1882); he knew no more about them.

He took ten grains of iodide of potassium, and a drachm of Liquor Hydr. Perchl., three times a day.

On September 22nd he was much better, could walk two or three miles fairly well. Voice better, articulation more clear and perfect. The eyes were still rather jerky in their movements, and there was much oscillation of the hands, and more when he attempted to grasp objects.

October 27th.—He was again better, but still had some tremor of the hands on movement. He now shows me some sores on the skin, which discharge what he calls water. They appeared some time after his first seeing me. One is on the inner side of the right knee; it is oval in shape, 1¼ inch by ⅞ inch, elevated above the surface, with a dull red thickened base, and two small circular ulcers upon it, each covered with a brown scab. On the back between the scapulæ is another similar sore, more circular in shape, 1¼ inch in diameter, the margins raised and thickened, an ulcer occupying the centre, mostly red and glazed, but at its right margin scabbed over. On the left shoulder there is a red patch, slightly raised, irregular in shape, about an inch in diameter. The ulcers itch a little but are not painful. There is no evidence of syphilis, but on the view that these might be due to that disease, the iodide was increased to twenty grains three times a day.

November 24th.—The sores are very much worse. That on the right leg is bigger, with a much infiltrated edge and base, so that it is rather a flat tumour-like elevation, with an irregular granulating sore occupying now the whole surface. The same prominence of the whole mass is seen in the sore on the back, which now measures 3 inches vertically by 2 inches in width, and projects ½ inch from the surrounding skin. The ulcer corresponds to the shape of the swelling, has an irregular surface, pale granulations, and thin discharge. The iodide of potassium was now stopped.

December 1st.—There is no essential alteration. Ordered Liq. Ammoniæ Acetatis, ʒss, t. d. During the last few weeks the nervous symptoms have been much less marked.

15th.—He was admitted under my care into Stephen Ward, and a more detailed account of his case was taken by Mr. G. F. Hugill. He is well nourished, height 5 ft. 5 in., brown hair, blue eyes, teeth

fairly good. The pupils are equal. The bald patches present some yellow sebaceous crusts, and here and there short broken hairs, and he says there was a good deal of itching when the baldness began. The ichthyotic condition of the skin is marked at the bends of the different joints. There is abundant growth of hair on the arms and on the chest. The growth on the back now measures 5 inches vertically by 4 inches across, extending from the fourth to the tenth dorsal vertebra, and projects about ¼ inch from the surface. The unbroken skin is continuous up the sides of the tumour to its flat surface; and this surface is partly ulcerated, partly sloughy. A depression in the centre measures 1½ by 2½ inches, and has black slough upon it, while the circumferential part is prominent, and of light greenish-yellow colour. The lower part of the mass projects more from the back than the upper. The surrounding skin is inflamed, the redness and induration gradually subsiding into the natural colour and consistence of skin, but extending farther on the lower side. There is a scanty watery discharge, and a most offensive smell, but no pain. On the inner side of the right knee over the condyle of the femur is a small ulcer with irregular indurated margin, granulating base, and tenacious yellow discharge; and over the inner end of the right sterno-clavicular articulation is a small hemispherical tumour, with a base the size of a threepenny bit, freely moveable on the deeper structures, with a vascular surface, and a scaling epidermis, and not much unlike a sebaceous cyst, though quite solid.

He has a good appetite; tongue clean. Heart and lungs normal. Urine, sp. gr. 1020, no albumen, no sugar. The condition of his nervous system appears now nearly normal; he walks well; sensation is normal; he is free from nystagmus, and, indeed, he says he would be quite well but for the lump on his back. I asked Mr. Golding-Bird to see it; he was of opinion that it was a sarcoma; and suggested a consultation with Mr. Durham. Mr. Durham, on the other hand, thought it still might be syphilitic, and, on his advice, the patient was ordered a calomel vapour bath twice daily, with three grains of quinine internally three times a day, and a terebene poultice was applied.

27th.—The left half of the tumour is somewhat less prominent. The right half more so. He can feel a touch on the surface of the tumour, but he has no pain. The induration of the skin extends for about one inch all round. The sore on the inner side of the knee

is covered with a dark scab. The tumour over the sterno-clavicular joint is smaller.

30th.—There are red, infiltrated patches, covered with small scales, on the middle of the upper lip, the angles of the jaw, and the sides of the chin. He has had considerable pyrexia for some days.

January 3rd, 1883.—At the right margin of the tumour of the back the surface is everting, and overlapping the skin at the side. A thin layer of slough has separated, and exposed large red granulations; the centre is more sunken. The skin is more inflamed around it. The induration has entirely disappeared from the sore over the knee, and there remains only an ulcer with a brown scab; the tumour over the clavicle is again still smaller. He feels well, and is in no pain. He was now under Dr. Pavy's care, and was ordered an application of equal parts of vaseline and balsam of Peru.

8th. — The gums are tender, and the teeth feel loose. The vapour baths have been stopped.

9th.—The clavicular tumour is much smaller; the scab is loosening from the sore on the knee.

11th.—He has a hectic flush on his face, and he has still much pyrexia, but his appetite continues good. The tumour of the back is less prominent, and a slough is peeling from the surface.

17th. — Much of the slough has been removed with forceps. Though the condition of the back is apparently improved, and the sore on the knee has actually healed, the patient is in many ways worse. He is febrile, with flushed face, very much thinner, much weaker, and speaks in a whining, querulous voice. He was sick three or four times last night and has lost appetite. He notices now a stinging pain in the back. For some days there have been patches of erythematous redness over various parts of the body and limbs. A marked example is one on the outer side of the right leg, where the desquamation of the cuticle already described is very considerable. Here is a large, irregularly oval patch of brownish-red colour, deepest in the middle, fading towards the edge, yet fairly well defined. The skin is here thickened, slightly raised above the level, and covered with large flakes of epidermis, which can be easily detached, leaving a shining, but not raw, surface; it is not painful. Above this patch is another, elongated upwards, of paler colour, less raised, with the epidermis in smaller

flakes. On the arms, shoulders, and elsewhere are pink, slightly raised patches, tending to a circular form, one or two ringed, with a few detached flakes of epidermis.

26th.—He has been occasionally sick after food. Pyrexia continues. The urine now contains albumen. He is now taking milk and soda water, six ounces of brandy daily, strong beef tea with peptones, and a drachm of tincture of Calumba in effervescing mixture, every six hours.

30th.—In many respects he seems better. His appetite has improved, and he sleeps well. The sloughs on the back are smaller, and have no smell. More red patches have appeared over the lower part of abdomen and sacrum, on the lip and on the left forearm; they are slight, raised, indurated, with a scaling epidermis. The patch on the right leg has begun to slough superficially. Ordered wine, ʒx, and the following.

℞ Liq. Arsen., ♏v;
Ferri et Ammon. Cit., gr. v;
Ext. Cinchon. Liq., ♏xx;
Tr. Nucis Vomic., ♏x;
Aq. ad ʒj. 4tis horis.

February 1st.—The red patches are still more numerous over his body; and there is a fœtid purulent discharge from that on the right leg. The urine contains albumen, no sugar, has sp. gr. 1007, and is pale.

6th.—The patient is suffering from severe cold and hoarseness. The breath sounds at the right apex are harsh, almost bronchial, and the vocal fremitus is increased. At both bases is some dulness and deficiency of breathing. There is no expectoration. The throat is injected. The face is covered with red patches. The slough has mostly separated from the right leg, exposing pale unhealthy granulations. The sore on the back has not altered much; it still presents much slough. The right leg is œdematous; the urine still albuminous.

8th.—The right arm is to-day œdematous; he has completely lost his voice, and appears very weak.

9th.—He has a little voice to day. The left base is rather dull, and breath sounds are deficient. Some coarse crepitations are heard at the outer side of the right scapula.

10th.—Mucous râles and harsh breathing over upper part of

right lung behind; expiration is prolonged and harsh, especially over the right lung.

14th.—He is very weak, has again completely lost his voice, the face is flushed, and the temperature has been for some time oscillating, about 101°. The sore on the back looks very unhealthy, many granulations having begun to slough, and the patches on the arm are also sloughing. There is much œdema of both legs and of the right hand. Ordered two ounces of brandy daily, and ten grains of iodide of potassium with a drachm of perchloride of mercury solution three times a day.

Numerous red patches are now described in the most varied situations—over the right eyebrow, nostril, angle of mouth, left lower lip, and on the trunk and limbs.

19th.—He is very much weaker and thinner.

20th.—The fibres of the trapezius muscle are exposed for two or three inches at the lower part of the sore on the back. The urine contains a trace of albumen, sp. gr. 1010. Pulse 144, feeble; resp. shallow.

28th.—He was very restless during the night, wanting to get out of bed. His breathing became shallower and more rapid, and he gradually sank, dying quietly about 11.30 a.m. on the 21st. He was conscious up to the last, and free from pain.

His temperature throughout was almost constantly above the normal. From December 21st to January 15th it ranged between 100° and 103°, with considerable evening exacerbations; on the 15th there was a rigor, with a temperature of 105°, and then for a fortnight the record ranged from 99° to 101°, with but slight oscillations. For another week—January 29th to February 5th—it varied from 100° to 102°, and then to the end was very close upon 101°, both morning and evening. The pulse was at first from 120 to 130, but at the end of January rose above 130, and was often 140 or even 150 in the minute.

The following is Dr. Goodhart's account of the *post-mortem* examination made by him:

"Hibernian type. Slight œdema of the legs and arms; muscles flabby; over all parts of the body, face, trunk, and extremities were scattered raised, reddish indurations—some of them simply indurations with a rather cracked or warty or ichthyotic epidermis over them, others having a central furuncular slough, and others a scab. To take the parts in detail: the scalp had a large

patch of alopecia on the back of the left side. The scalp felt thick, but a section did not show any abnormality, save an œdematous-looking swelling. There were dry scabs on the upper lip, and on either side of the chin raised encrusted indurations placed symmetrically. On several parts of the arms and trunk and thigh were either raised red indurations—these were specially on the right forearm—or raised red furuncles. The former showed on section greyish-red thickening of the cutis vera, of very firm consistence, and yielding no juice; the subcutaneous fat was healthy. The furuncles, on the other hand, showed a central, yellow, pappy core of slough, which in some cases had extended from the cutis into the subcutaneous fat, and had undermined the substance of the sore. The legs showed, in addition to patches such as these, a number of superficial, sharp-edged ulcers, with feebly-granulating base, hardly extending to the depth of the true skin, the result of the previous occurrence of superficial sloughing of the skin.

"The most marked cutaneous disease was a large sloughy-looking sore on the right side of the upper dorsal region. Its upper part formed a smooth, rounded eminence, with a sloughy surface, suggesting tumour, and below this came the trapezius on each side, bared of everything superficial to it, save a thin layer of granulations. A vertical section of the thickened mass showed a pinkish, fleshy-looking growth, quite like a tumour, for the most part shut off from the subcutaneous fat by a fibrous capsule, but spreading through it and the subjacent muscle at one spot. A scraping gave no juice, and a small piece teased out showed an indefinite fibroid texture, with ill-formed lymphoid cells in small number in its meshes.

"The skin generally was thick and scaly. At two parts were scars where indurations had been present and recovered. One on the inner side of the right knee showed nothing peculiar on section, but was an ordinary pale depressed scar. The other, over the inner end of the right clavicle, was a small circular depressed scar, with an opaque, yellow, or fawn-coloured centre, which on section looked like a patch of xanthelasma.

"The pericranium of the vertex over both parietal bones near the sagittal suture was thickened, very vascular, and stripped from the bone easily—evidently from early periosteal inflammation. In addition to this there was a circumscribed, soft, and apparently inflammatory thickening of the pericranium near the right frontal eminence, about half an inch in diameter. Neither the skin over

these lesions, nor the bone beneath, had suffered any appreciable change. The skull was thick.

"Both lungs were œdematous and in an early stage of pneumonia at the bases. The tracheal mucous membrane was coated with thick mucus, and at one spot was a depressed area, which had somewhat the appearance of a scar; but on close examination it could not be said certainly that there was any disease there. The mucous membrane of the larynx was thickened behind, and swollen over the arytenoids. There was a very large ulcer, occupying a good part of the left side of the larynx, of great depth and irregular shape. Its depth was due mostly to an unusual amount of thickening of its margins. Behind, it had exposed the arytenoid cartilage, and in front of this it occupied and thickened the laryngeal wall of the sacculus laryngis, which it had converted into a remarkably thick, fibroid, resistant tissue. On the opposite side there was a superficial ulcer running along the vocal cord.

"The heart weighed 11½ ounces. There was acute pericarditis. The muscular fibre of the left ventricle was very pale at the apex; the endocardium was thick; the aortic valves rather thick at their bases; the mitral valve and right side of the heart healthy.

"The abdominal viscera were healthy.

"The liver weighed 57 ounces, and showed a little thickening of its capsule at one part. The spleen weighed 6½ ounces.

"The kidneys weighed 20 oz. The surfaces were smooth; the cortex increased in thickness, of a pale pinkish yellow tint, which suggested acute nephritis on its way towards chronic parenchymatous nephritis, or the large white kidney; the pyramids were deeply congested, and the organs full of blood; there was no lardaceous reaction with iodine.

"The epididymis on both sides was diseased; it was reddish-gray, much swollen, and on one side converted into a mass of almost cartilaginous hardness, apparently from subacute inflammation; on the other side the tissue excess appeared to have undergone reabsorption or replacement by conversion into fibrous tissue. It was more grey and less solid than on the other side.

"The shoulder, knees, and toe-joints were healthy.

"The intervertebral discs were bridged over by bosses of bone along the sides of the bodies; the vertebræ themselves were healthy.

"There was suppuration of the left middle ear; the choroid and

retina were normal on both sides; there was no enlargement of the cervical glands.

"The brain, spinal cord, and meninges were perfectly normal."

The sloughing tumour of the back was removed entire, and is exhibited to the Society. A careful examination of the preserved specimen shows the following: The ulcer is oval, measuring 5½ in. vertically by 3¾ in. transversely, occupying more of the right than the left side. An oblique line from the line of spinous processes above, downwards to the right, divides the ulcer into two equal parts, of which the left and lower part presents the fibres of the two trapezius muscles, entirely denuded, and the right and upper part consists of a firm mass of tissue, measuring 2 inches by 4, incorporated with the subjacent muscle along its inner half, almost free of muscle in its outer half, but inseparable from the neighbouring skin. Where the trapezius muscles are exposed the skin, thickened and infiltrated, terminates in a free margin. On section into its substance it is white, firm, smooth, dry, and in some parts traversed by fibrous bands. Nerve-fibres are found running through it, and at its deepest part the muscular fibres are mixed up with it, and at the inner part it is infiltrating the rhomboidei. Scarcely any vessels are visible to the naked eye.

Portions of this, placed under the microscope, show it to consist of closely packed lymphoid cells almost entirely; nucleus of round, oval, or polygonal shape, and from $\frac{1}{2500}$ to $\frac{1}{3000}$ inch in diameter. For the most part there is but little reticulum, but in places there are bands of fibrous tissue, which are no doubt the representatives of the pre-existing tissue, rather than parts of a new growth. Most of the sections show a large number of small blood-vessels and capillaries, full of blood corpuscles, and some show transverse oblique sections of fine nerve fibrils, while those from the deeper part of the tumour contain short lengths of muscular fibre, entirely isolated from one another by the cell growth.

One epididymis was examined (and I am unable to say which) and sections showed that it presented a structure very similar to the above, consisting entirely of densely crowded lymphoid cells of the same average diameter, with very little special reticulum, but bands of wavy fibrous tissue, probably belonging to the original tissue. The seminal tubules are still patent, but are separated from one another by the new growth, and the cells infiltrate the tissue right

up to the wall of the tubule, which indeed is not obvious as a separate structure.

As to the size of the tubules, I have compared them with those of a healthy epididymis, and they are on an average very nearly, if not quite, as large. As, moreover, the shape of their transverse sections is mostly quite circular, it is fair to regard them as having suffered little, if any, compression. No epithelium is present, and it has probably fallen out in preparation. From some sections made by Mr. Price it is seen that the cell growth has also infiltrated the connective tissue between the tubules of the body of the testis.

A section of one of the inflamed patches on the arm shows a dense infiltration of all the tissues of the cutis with small cells, which extend to the subcutaneous tissue, and occupy the septa between the fat-cells of the adipose layer.

A section from the thickened and bald scalp also shows infiltration with small cells. This is not complete, as in the patch from the arm, but occurs in groups of varying size and irregular distribution.

Remarks.—There are many points of great interest about this case, the nature and connections of which are by no means obvious. Looked at simply from the point of view of the tumour on the back, it must be regarded as a case of lympho-sarcoma of the skin of the back, involving to a small extent the deeper structures, and beginning to cure itself by sloughing; and the change in the epididymis and testis is of the same kind. But these form really a very small part of the disease, which affected the most different organs and parts of the body, so that within the course of twelve months, at the outside, this patient was the subject of the following disorders:—A disorder of the nervous system giving rise to symptoms resembling those of insular sclerosis, of a few months' duration, not explained by anything found *post-mortem;* lympho-sarcomatous new growths with desquamation of the epidermis, erythematous and furuncular inflammations and alopecia of the scalp; lympho-sarcoma of the epididymis; inflammation of the pericranium, and thickening of the skull; ulceration of the larynx; acute nephritis, and acute pericarditis.

Naturally one of the first suggestions was that syphilis was the cause of it, and the discovery after death of periostitis of the scalp, ulceration of the larynx, and an affection of the testicle, shows at

least a most interesting resemblance to the manifestations of that disease. But looked at more closely, the evidence is by no means satisfactory. First, he denied most emphatically having had the disease, and no evidence of primary infection was forthcoming. Then, as a fact, none of the lesions were truly gummatous or typically syphilitic, neither the tumours of the skin of the back and other parts, nor of the epididymis. Moreover, the body of the testis presented none of the new growth of fibrous tissue which is characteristic of this disease. The liver was healthy, and none of the organs were lardaceous. The therapeutical test is rarely a safe one, and here, at any rate, it lends but feeble support to a syphilitic theory. Antisyphilitic remedies were administered as follows:—First period, from September 8th (and perhaps before) to November 24th, iodide of potassium in doses of 10 to 20 grains, with $\frac{1}{16}$th grain of perchloride of mercury. Second period, from December 23rd to January 8th, fumigation by 20 grains of calomel twice daily. During the first period the nervous symptoms, to whatever they were due, no doubt began to subside, and were nearly entirely gone by the end of it. But it was actually during this period that the tumours of the back and inner side of the knee developed, and rapidly grew in spite of increased doses. During the second period the tumour of the back sloughed, and seemed likely to heal by granulation, and the tumours over the knee and clavicle were rapidly subsiding. But, on the other hand, the tumour over the knee had already begun to improve in the interval of four weeks between these periods, and during this second period the erythematous lesions of the skin appeared, the temperature rose to pyrexial height, and the patient's general condition was very considerably altered for the worse. On the whole, I think it must be said that syphilis was not the cause of the various lesions occurring in this patient. As to the other great dyscrasia, tubercle, it is remarkable how little there is in the case that resembles the lesions of this disease. Setting aside tubercle and syphilis, I do not know to what general disease to refer it, and one can only say that there was a profound alteration of the nutrition of this patient's organs and structures, analogous to, but not identical with, that produced by syphilis, and not quite intelligible, either as an antecedent or a sequel, of the lymphomatous growths.

In conclusion, I may draw attention to some remarkable features in the case:—Firstly, to the nervous symptoms, of which I regret I

have not more detailed notes, their complete subsidence and the absence of any discoverable lesion in the nervous centres to account for them. Secondly, the disappearance, which was quite probably spontaneous, of the tumours over the knee and clavicle. Though the former ulcerated and scabbed, it did not slough away, but was in great part absorbed; the small tumour over the clavicle was entirely absorbed, without any breach of surface. Thirdly, the condition of his skin shortly before death was very remarkable, covered as he was with big red blotches all over his face, trunk, and limbs, in every phase, slough, ulcer, and suppuration, of the termination of inflammation. And, lastly, his nephritis was anomalous, in presenting after death all the features of the early stage of a large white kidney, while the urine had a specific gravity of 1010, and contained only a trace of albumen. *April 17th*, 1883.

---

7. *Lympho-sarcoma of the back, accompanied by spreading ulceration.*

By N. Davies-Colley, M.C.

[With Plate XVII, fig. 1; XVIII, figs. 1 and 2.]

Emily G—, aged 27, unmarried, a cook, was admitted into Guy's Hospital under me on September 19th, 1881. Her family history was good. She had never had syphilis, or any other serious ailment. In February, 1880, two lumps appeared upon her back about the size of walnuts, one on each side of the spine, at the level of the first lumbar vertebra. She was treated for them in a cottage hospital, where she remained in bed for about five weeks, and she was told that they were abscesses in connection with the spine. In about four months they disappeared without any operation.

In March, 1881, the present affection began, with a swelling above the left crista ilii; another upon the right side soon followed. They slowly increased with but little pain until July, after which they grew more rapidly, and became very painful. She came first as an out-patient, and the tumours were then thought to be gum-

DESCRIPTION OF PLATE XVII.

FIG. 1 represents the appearance of Mr. Davies-Colley's case of Lympho-sarcomatous Ulceration of the Back. (Page 258.)

Below is seen the ulcer, and above are two swellings, one on either side of the spine, representing tumours with the skin still unbroken over them.

FIG. 2 represents the appearance of Mr. Davies-Colley's case of Anthrax of the Face. (Page 291.)

FIG. 3 represents the appearance of Mr. Bryant's case of Anthrax of the face. (Page 293.)

From drawings by W. Hurst.

Fig. 2.

Fig. 3.



DESCRIPTION OF PLATE XVIII.

FIGS. 1 and 2.—To illustrate Mr. Davies-Colley's case of Lympho-sarcomatous Ulceration of Back. (Page 258.)

FIG. 1.—From the tumour upon the back. (× 400 diam. about.)

FIG. 2.—Lympho-sarcomatous infiltration of psoas muscle. (× 400 diam.)

FIG. 3.—To illustrate Mr. Davies-Colley's case of Anthrax of the Face. (Page 291.)

Serum from anthrax eschar containing bacilli.

From drawings by Mr. Davies-Colley.

Fig. 1



Fig. 2.

Fig. 3.

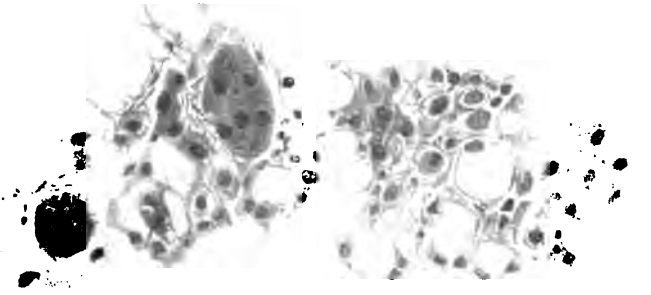

matous. By this time the one which appeared first had begun to ulcerate.

On admission, she was healthy looking and fairly well nourished. On the one side of her spine over the crest of the left ilium was a large crescentic ulcer, 4½ inches from one extremity to the other, spreading rapidly by its lower convex border. On the other side of the spine was an irregular elevation, consisting of three or four low bosses separated by slight depressions, smooth, hard, tense, and shining, 5 inches across, and 1 inch elevated above the surrounding tissues.

I did not see her until about a fortnight later. The crescentic ulcer was then still increasing downwards; its lower edge was abrupt, and the adjacent skin was much swollen, of a livid red colour, and very tender; the surface of the ulcer was covered by a dirty white slough of dead skin. At the upper edge there were some granulations, and the skin was on a level with the surface of the ulcer. At first I looked upon the case as syphilitic, and gave iodide of potassium in 20-gr. doses three times a day, and afterwards a combination of iodide with perchloride of mercury in doses of $\frac{1}{12}$ gr. No benefit resulted from this treatment. She became very weak and emaciated. The swelling on the right side softened and excoriations formed upon it, while another swelling formed above the crescentic ulcer. She complained much of pains in her legs; her temperature was persistently raised; she became very feeble and delirious, and died on Nov. 7th, about eight months from the appearance of the swellings.

Dr. Goodhart made the *post-mortem* examination.

The viscera were all healthy.

The tumour on the left side of the spine was somewhat shrunken, some parts of it having softened down and burst. On making sections of this and the other tumour, the subcutaneous tissues and muscles were found to be infiltrated with a soft, fleshy substance, which was everywhere of a dull yellow or tawny colour, from degenerative changes. The margins of this material were smooth and well defined.

Both psoas muscles were infiltrated with a similar material.

There was some softening of the body of the third lumbar vertebra, but no growth could be seen on section of it. The lumbar glands were rather large and fleshy, but not caseous. There were no scars about the genital organs, or in any other part of the body.

Mr. J. A. P. Price, who was my dresser, made and stained for me some sections of the subcutaneous swellings, the margin of the ulcer, and the infiltrated psoas muscles. They all present the same structure, a delicate, somewhat misty reticulum of connective tissue, in the interspaces and between the fibres of which are embedded round nucleated cells, which closely resemble leucocytes.

At one point in the section of the dorsal tumour, I found some dark-coloured masses containing four or five nuclei, and resembling myeloid cells.

The minute anatomy of these swellings and infiltrations leave me in some doubt whether to consider them some form of chronic inflammatory product or sarcomatous tumours.

My first impression was that they were due to syphilis, but I was led to discard this view from the absence of any history of that disease, from the fact that no benefit followed the administration of mercury and iodide of potassium, and lastly, because there was no fusiform development of the cells in any part of the sections which I examined. It occurred to me also that they might be the result of some other form of chronic inflammatory change, such as accompanies the tubercular cachexia. Against this hypothesis was the absence of tubercle in the lungs and the viscera, and the clearly marked definition of the deposits where they came into contact with the healthy structures. I have, therefore, come to the conclusion that the swellings were really the result of a malignant growth of the nature of lympho-sarcoma, and I have brought forward the case on account of the remarkable spreading ulceration which resulted upon the breaking down of one of these tumours. It seems to me to afford another example of the great difficulty that occasionally arises in drawing the line between malignant and inflammatory disease.

Another interesting point in the history of the case was that the two tumours which were first noticed appear to have improved so much under treatment that the patient thought they had altogether disappeared. *April 17th*, 1883.

8. *Recurrent cartilaginous tumour of the head and neck.*

By GEORGE LAWSON.

THE specimen which I show to-night is the recurrent growth of a cartilaginous tumour of the head and neck. The patient first came under my care in 1878, and her case was reported in the 'Lancet' of June 8th, 1878.[1] But as there have been five recurrences since that date, I decided to bring before the Society the last of the recurrent growths, which I removed on February 10th of this year. The tumours in their rapid growth, recurrence, general appearance and structure, differ from any tumour which I have seen, and I will therefore, with the permission of the Society, refer them to the Morbid Growths Committee for their examination.

The history of the case goes back to 1865, when she first came under Sir William Fergusson's care on account of a large tumour, bulging below the jaw, and pushing into the mouth. He then removed the tumour, and at the same time took away five teeth from the lower maxilla, which appear to have been displaced by it. She made an excellent recovery, and for a time remained well, but the tumour recurred, and after two or three years was again removed by Sir William Fergusson. Unfortunately the patient had kept no account of the dates of the different operations she had undergone. She was only able to say that she was operated on twice between the years 1865 and 1872, and three times between 1872 and 1876; the last operation being in November, 1876, when Sir William apparently succeeded in getting away the whole of the growth.

On December 26th, 1877, the patient, aged fifty-seven, a stout, healthy-looking woman, came under my care in the Establishment for Invalid Ladies for the purpose of having the tumour again removed. Since the last operation the tumour had recurred, and, as she could not have the benefit of Sir William Fergusson's assistance, she had allowed the growth to remain until it had attained such dimensions that she was compelled to seek relief.

[1] By the permission of the Council of the Society, and with the object of making the case more complete, I append extracts from the original report of the case, and also the woodcuts which were used on that occasion.

On admission, the tumour presented the external appearance shown in the woodcut (Fig. 10). It extended upwards to the level of the lower part of the ear, downwards in the neck to within two

WOODCUT 10.

fingers'-breadth of the clavicle, and forwards it was bulging close up to the nose. Looking within the mouth, the tumour was seen to occupy the greater portion of that cavity; and it extended across the pharynx against which and the soft palate it pressed. The mouth could be closed, and she could take food without much difficulty, but her breathing was at times troublesome, and especially at night. Sir James Paget and Mr. Bowman kindly saw the patient with me, and both agreed in advising an operation.

On January 7th, 1878, I removed the tumour with the portion of the lower maxilla from which it grew. The details of the operation were published in the report in the 'Lancet.' The patient rapidly recovered and returned home on February 14th.

Examination of the tumour.—The tumour weighed close upon

eighteen ounces. It was of a firm consistence, but easily cut with the knife. It was intimately connected with the periosteum on the

WOODCUT 11.

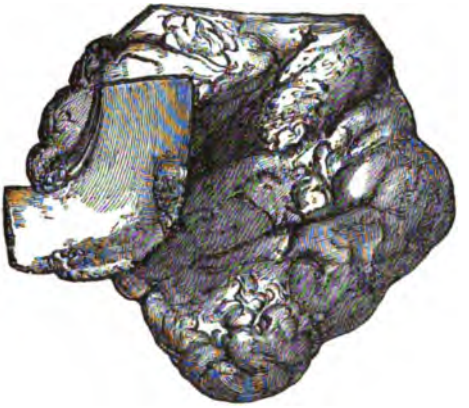

Portion of the lower jaw, with the tumour growing from the periosteum on its inner surface.

inner side of the lower jaw, from which it apparently sprang. A portion of the tumour was given to Dr. Thin immediately after its removal, who kindly gave me the following report of his microscopical examination :—"I examined microscopically the portion of the tumour kindly given me by Mr. Lawson, and I believe the growth to be a chondrome of the class named by Cornil and Ranvier chondromes hyalins lobulés. It has the peculiarity that the cartilaginous tissue is of a very low type, so much so that the determination of the exact nature of the growth was a matter of some difficulty. Successful preparations, however, show that, except in the degree of development of the cartilaginous substance proper, the structure is identical with that described by pathologists as characteristic of these tumours."

Dr. Coupland, the lecturer on Pathology at the Middlesex Hospital, examined the specimen of the growth prepared by Dr. Thin, and concurred in the report.

Since the operation in January, 1878, there have been five operations for extensive recurrences of the disease, and on each occasion masses of cartilage similar to those exhibited were removed. The recurrences have been in the neck, and in the temporo-maxillary region, extending from the glenoid fossa of the temporal bone

towards the base of the skull; and in the cheek between the mucous membrane and the external integument. At each operation the tumour was found to be composed of large isolated masses of cartilage, varying in size from that of the closed fist to a small nut, packed tightly together, and each portion enclosed in a distinct capsule, from which it could with a little difficulty be enucleated. The masses of cartilage were of sufficient density to push before them in their growth all important structures with which they were in contact.

The dates of the recurrences are as follows:

November 23rd, 1878.—Admitted with recurrence of the disease.

December 9th.—Returned home quite well.

November 29th, 1879.—Recurrent growth removed.

January 17th, 1880.—Returned home quite well.

November 25th, 1880.—Recurrent growth removed.

December 22nd.—Returned home quite well.

December 7th, 1881.—Recurrent growth removed.

January 10th, 1882.—Returned home quite well.

February 10th, 1883.—Recurrent growth removed, and patient progressing very satisfactorily.

Since the first operation by Sir William Fergusson in 1865, the patient has had ten operations for recurrences of the growth; four by Sir William Fergusson, and six by myself.

The most extensive recurrence was when she first came under my care and I had to remove a large portion of the lower maxilla.

It is a matter of interest that this poor lady was the last patient upon whom Sir W. Fergusson operated.

February 20th, 1883.

Report of the Morbid Growths Committee on Mr. George Lawson's case of recurrent cartilaginous tumour of the lower jaw.—We have examined sections of the tumours last removed by Mr. Lawson, and have observed the following characters:—A meshwork composed of coarse fibrous tissue, from which finer fibres or bands of fibres are derived; spaces between the fibres and bands of fibres occupied sometimes by a homogeneous or finely granular material, sometimes by cells, the outlines of which were in many places ill-defined, but which in other places presented a rounded or ovoid shape. This was the structure of the central portions of some of the tumour masses. The peripheral portions were much more cel-

lular, and, in one of the tumours, the bands which, in the centre of the mass were composed of fibrous tissue, were, at the periphery, composed of elongated cells. In some sections, which we ourselves made from one of the smallest tumours last removed, the structure was much more cellular throughout. There was scarcely any fibrous tissue, and the bulk of the tumour was composed of elongated fibre-like cells.

In no part of any of the sections have we observed the cells or structure of cartilage.

We believe, both from the clinical and histological characters of this disease, that it is a sarcoma, chiefly spindle-celled, in many parts partly or wholly organised.

JAMES F. GOODHART.
April, 1883. HENRY T. BUTLIN.

---

9. *Enormous osteo-sarcoma of the left femur in a boy.*

By ARTHUR E. DURHAM.

EDGAR B—, aged 9, was admitted into Guy's Hospital, under the care of Mr. Durham, September 18th, 1882.

Five or six months ago, after playing in a yard, he had severe pain in the thigh, and a swelling was found in the upper part of the thigh as large as a fist. He was taken to the Infirmary, and put under medical treatment, but the swelling increased and the pain became very severe, especially at night—"like a knife going into his leg."

On admission, there was found a uniform ovoid enlargement of the whole of the left thigh, extending from anterior superior spinous process of the ilium to the margin of the head of the tibia. The patella was displaced downwards by the tumour, and the boy was unable to flex his knee; the skin over the tumour was stretched, and showed numerous very distinct subcutaneous veins. There was some tenderness on pressure. The greater part of the swelling had a more or less soft, somewhat elastic feeling on manipulation, firmer in some parts than others, and in some parts was hard and resistant. The iliac glands, deep down in the pelvis, were manifestly enlarged.

In the largest part the left thigh measured in circumference,			just below middle	21½ inches.
„	right	„	„	9 „
In the upper part left thigh		„	„	20½ „
„	right	„	„	12½ „

After admission, the tumour continued to increase steadily, and the pain was sometimes very severe.

On November 28th, the circumference of the limb was 24¾ inches.

January 11th.—Pain in femur greatly increased. Skin much distended and glazed in appearance; veins enormously enlarged and anastomosing freely; circumference of tumour 26¾ inches. Boy looks paler and thinner, but is able to sit up in a chair for a change.

The patient was exhibited as a living specimen.

It may be stated that the tumour of the thigh has gone on steadily increasing since the time of exhibition, and fresh tumours have appeared—one in connection with the left zygoma, another on the right tibia.

The patient has died since this report was made, and a *post-mortem* examination made by Mr. John Poland, is thus recorded:

Body extremely emaciated; weight of body, with tumour, 80 lbs.; the tumour, looking as large as the rest of the body, weighed 38 lbs. On section it showed a considerable amount of bony material in its substance near the femur; elsewhere, in the outlying parts, it had a fleshy, in part fibrous, sarcomatous appearance. There were secondary deposits in the calvaria, temporal bone, and in the right tibia; and all were composed of a tough white opaque material, which had a radiating appearance from a centre of bony spicula.

The *lungs* were excessively diseased. Nearly the whole of the right lung was occupied by a dense white growth in tough bony nodules, running together into large masses; and in the left were many similar but smaller nodules. The bronchial tubes were markedly dilated.

Heart.—A mass of white growth occupied the apex of the right ventricle, and projected into its cavity.

The iliac glands were involved on the left side in the main growth in the femur, but elsewhere, and the other viscera, were healthy. *February 20th*, 1883.

10. *Calcified round-celled sarcoma of the bones of the leg.*

By W. Roger Williams.

This specimen was obtained from a young man, aged 21, who was admitted into the Middlesex Hospital on January 1st, 1883, under the care of Mr. Morris, who has kindly allowed me to exhibit it.

A large oval growth, 4 by 7 inches, surrounds the lower half of both bones of the leg, having its long diameter parallel with theirs. Its surface is irregularly nodulated and enveloped in a thick capsule. It is for the most part of firm and elastic consistence, but in some places of bony hardness. The adjacent structures are compressed and wasted by it, but not in the least infiltrated.

On longitudinal section the growth presents a solid, quasi-osseous appearance; the peripheral parts being softer than those more deeply situated. The interosseous space is invaded, and the bones are completely embedded in it. Their cortical substance in this situation is much thinned, and in places quite destroyed, the growth having invaded their medulla and spread along it for several inches. But the cortex of neither bone is distended over the growth like a shell, as usually happens when the disease originates within the medulla; hence I conclude it had a peripheral origin.

Microscopical examination of the capsule revealed chiefly fibrous tissue, except at the surface in contact with the tumour, where a large spindle-celled tissue prevailed. Decalcified sections of the growth itself showed a structure of rounded granular cells, considerably larger than leucocytes, embedded in a finely reticulated matrix, each mesh containing, as a rule, only a single cell. This matrix was the seat of the calcareous deposit.

The patient, a tall young man, of pale, sallow, and emaciated appearance, presented on admission a large swelling of his left leg, due to the growth I have just described. Over its most projecting part in front was a small cutaneous ulcer, from which sharp hæmorrhage had occurred on several occasions. A few enlarged glands were found in the left groin, probably secondary to the

cutaneous lesion, as they subsided and disappeared after its removal. Above the growth both bones were of normal size. The ankle and knee-joints were intact, but the left foot was swollen and œdematous. There were no signs of secondary disease in any part. Urine acid, lithates, sp. gr. 1030, no albumen.

He says that nine months ago, by the upsetting of a barrow of bricks, he sustained a severe contusion of his leg at the seat of the present growth. He is sure there was no fracture, as he was able to walk about on the following day. At the time of this accident he was apparently in very good health.

A month after it he first noticed a slight swelling of his leg at the seat of the injury. This gradually increased, without any pain, except after walking or some other exertion. He continued to follow his usual employment until four months ago, when he had great difficulty in walking and pain. His doctor said he had periostitis. Since this time the swelling has increased rapidly to its present size.

His previous health had been very good, having had no serious illness since childhood. There was no history or sign of any venereal disease. Both his parents are now alive, healthy and well. No history of cancer, tumour, phthisis, bone or joint disease in the family.

Such being the case, Mr. Morris amputated the limb through the knee-joint on January 3rd.

Subsequent progress was slow, for the flaps partially sloughed, and a large abscess formed on the front of the thigh beneath the rectus muscle. Since this has been incised and drained, his condition has steadily improved. He is now quite convalescent, the operation wound having almost completely healed. The enlarged glands in the groin have quite disappeared, and there is no sign of any secondary disease. His general condition has also much improved. *May 15th*, 1883.

11. *Melanotic spindle-celled alveolar sarcoma and gland.* (*Card specimen.*)

Exhibited by HENRY A. LEDIARD, M.D.

THIS tumour was removed from the calf of the leg of a healthy-looking man, aged 23. It had been growing painlessly for two years, and the surface was extensively ulcerated. A diseased gland was taken from the groin at the same time.

A few weeks later the disease recurred in the femoral glands, and a large mass of growth was dissected out exposing the femoral artery for more than an inch. The patient died about three months after the first operation, probably from extension of the disease within the abdomen. There was no history of cancer in the family.

The tumour, which originated in the skin, was the size of half an orange and quite black on section, whereas the glands were of a brown colour.

Structurally it was found to consist of a fibrous stroma with alveolar spaces containing many colourless cells. The stroma showed numerous spindle-shaped cells with elongated and pigmented nuclei. There were also plenty of unpigmented spindle cells. A very large proportion of the cells were pigmented, and these were mostly collected in groups or in lines between the spaces.

April 17th, 1883.

12. *Carcinoma of omentum.* (*Card specimen.*)

Exhibited by BEDFORD FENWICK, M.D.

THIS specimen was obtained from the body of a woman, aged 36, who died in the Hospital for Women, under the care of Dr. Carter, on November 17th. The omentum is transformed into a nearly solid plate by new growth, hard and firm in consistence, in parts nearly 1¼ inches thick. All the pelvic contents were embedded in, and matted together by a similar material, and the omental change appeared to be a direct extension by contiguity. The patient had suffered for some months from the symptoms of uterine carcinoma. The immediate cause of death was extensive left pleuritic effusion, set up by secondary deposits on the pleural aspect of the diaphragm, and sudden cardiac failure. There was no other thoracic or cerebral invasion.

Microscopically, the new growth was made up of a few nucleated and nucleolated cells, and a large amount of fibrous stroma. Everywhere it presented a scirrhous appearance and section.

December 19th, 1883.

IX. DISEASES, ETC., OF SPLEEN, SUPRA-RENAL CAPSULES, AND THYROID.

1. *Addison's disease without melasma causing death by syncope, apparently from seasickness.*

By JAMES F. GOODHART, M.D., for W. WITHERS GREENE.

MR. V—, aged 36 to 40, had been out of sorts, and took the voyage from America for his health. The sea seemed to upset him, and he vomited obstinately. He was taken to his hotel in a very exhausted condition, and Mr. Withers Greene saw him the same night; he had a very feeble pulse and a dilated right pupil. Subsequently he had a little diarrhœa and fainted off dead on the night stool; it being supposed, and very naturally, that the exhaustion of excessive sea-sickness had proved fatal.

The inspection was made on April 21st, 1882, by Dr. Goodhart and Mr. Greene.

General appearance, &c.—Good head, rather bald; rather an excess of subcutaneous fat; muscular development good; slight abrasions about knees, and old scars on foot, but no trace of bronzing in any part; scrotum and nipples were perhaps less pigmented than normal; and forehead was quite free.

The brain was healthy; the vessels at the base rather sodden looking as in chronic Bright's disease; and the medulla oblongata had a little surface pigment over it.

The middle ear contained offensive pus, and the bone was discoloured; the dura mater over it being, perhaps, a little rough. (His pupil on this side was dilated.)

There were old adhesions at the right apex, and the lung corresponding was tough and fibrous, but there was no tubercle. A small mite of cheesy stuff found in the left lung might have been anything. There were a considerable number of ecchymoses in the subpleural tissue.

Trachea and larynx injected.

Heart small; some subpericardial ecchymoses.

Muscle yellow and fatty looking; many of the muscular bands wasted and fatty; left ventricle dilated and empty; mitral valve rather thick.

Stomach remarkably thin; its mucous membrane reddened and pitted over with a number of grey, depressed parts, which looked like old scars.

Liver rather small, healthy looking.

Spleen 6 or 7 oz.; firm, like a heart spleen.

Supra-renal capsules, both very large, perhaps ½ oz. each; they retained their natural shape, but were converted into tough yellow material, more like gummatous tissue than anything, as they were tough and elastic, showing no tendency to soften, although yellow. The entire capsule in each case was affected, but no puckering or notable adhesion to the surrounding parts could be detected.

Kidneys healthy.

Testes healthy.

Spine healthy. *December* 19*th*, 1882.

---

2. *Dissection of the abdominal sympathetic from a case of Addison's disease.* (*Card specimen.*)

Exhibited by J. F. Goodhart, M.D.

Both capsules are small, yellow, and nodulated; the left smaller than the right, the right unnaturally adherent to the liver.

The central ganglia of the abdominal sympathetic are shrivelled-looking and fibrous, and their branches run on to, and become lost in, the diseased capsules.

From a boy aged 17. His illness was only of ten weeks' duration according to his estimate; his symptoms were cold sweats, emaciation, and debility.

He died comatose. There was considerable bronzing of the skin; Acute tuberculosis was the immediate cause of death. The specimen is from the Museum of Guy's Hospital 2020[33].

December 19*th*, 1882.

X. DISEASES OF THE SKIN.

1. *Bromide rash simulating erythema nodosum.*

By P. Horrocks, M.D.

The patient, Margaret S—, is 10 years old, and has been suffering from epileptic fits for nearly two years.

Six months ago she came under my treatment, and bromide of potassium in twenty-five-grain doses twice a day was prescribed. This was on the 21st July, 1882. About three months afterwards, on the 6th of October, a rash appeared on her legs having very much the appearance of erythema nodosum, viz. roundish raised red patches scattered over the extensor surfaces of the legs.

There was a dusky hue about some of them just as occurs in erythema nodosum. Lead lotion was applied and they improved, but a similar rash made its appearance on the back of both arms and the extensor aspect of both forearms.

It is six weeks since the first appearance of a rash, and all this time the Pot. Brom. has been taken in undiminished doses. The lead lotion was stopped, and three drops of Liq. Arsenicalis added to each dose of the medicine. Under this treatment she got quite well of the rash a few weeks after being shown to the Society. There was considerable desquamation, and pigmentary stains were visible for a few months.

There was no rash in the usual acne situations—between the shoulders and on the face. Her age might to some extent account for this, as the bromide rash is said merely to aggravate the ordinary post-puberty acne rash. *November 21st*, 1882.

2. *Unusual bromide rash.* (*Living specimen.*)

By P. Horrocks, M.D.

Lizzie W—, aged 13, has been suffering from fits for about six months. For nearly four months she has been taking bromide of potassium three times a day, prescribed by Dr. Gowers, under whose care she is. After taking the medicine for about three months a rash appeared on the right leg, chiefly in front. It consisted of roundish or oval patches, with intervening healthy skin. The patches varied in size from a mere pimple to a crown piece, and were multiform in character, vesicular, pustular, and squamous. Here and there was a large bulla, and the epithelium was heaped up over some, forming thick ecthymatous-looking areas. They have these characters at the present time. There is no rash on the other leg, and none on the face or between the shoulders. A few acne spots come and go occasionally on her arms.

It is quite open to question whether this rash was really caused by the bromide, but there does not appear to be any other cause for it, except, perhaps, that the girl is in a low condition from bad air and food. It is difficult, however, to explain why it is on one side only.

Since exhibiting her to the Society the bromide has been stopped for a time, and five drops of Liq. Arsenicalis in water three times a day administered. In a few weeks the rash had improved very much, but as the fits were troublesome the Pot. Brom. was again given in the same doses as before, the Liq. Arsenicalis also being continued. The rash has not made such satisfactory progress since then, but is slowly healing. *January 16th*, 1883.

---

3. *Case of keloid following lupus scraping and the subsequent development of keloid in other operation wounds.*

By H. H. Clutton.

In April, 1882, a boy, aged 15, came to my out-patient room with necrosis of the middle phalanx of the right index finger, of two months' standing. The dead bone was removed in my absence by

Mr. Pitts. He had also on the right cheek, just in front of the ear, a patch of lupus vulgaris. This had been treated in various ways by different doctors for seven years. On my return, in the latter part of the same month, I put the boy under chloroform and scraped away the whole of the diseased structures with Volkmann's sharp spoon. After this healthy granulations appeared, and on July 25th the sore was reported in my notes as being soundly and perfectly healed.

In the meantime the boy had noticed for the first time in the latter end of May a swelling below the left knee. This on examination proved to be a chronic abscess. It was tapped with trocar and canula, but the pus was so thick and curdy that an opening had to be made with the knife before the cavity could be emptied. A probe introduced through this opening passed upwards between the tibia and fibula towards the outer head of the tibia, but no bone was struck. The knee was quite healthy.

In the same way the boy informed us in the early part of June that he had just discovered another swelling behind the left shoulder. This also was a chronic abscess causing no pain or inconvenience of any kind, and apparently quite free from the joint. It was tapped and emptied, but soon filled again.

August 23rd.—The boy was placed under the influence of ether, and the sinus in the leg laid open to its furthest extremity. It was then found to lead into the centre of the outer head of the tibia. The cavity was large enough to admit easily the last phalanx of the index finger, and seemed to be situated immediately beneath the articular cartilage of the knee-joint, a thin layer of bone alone intervening. Several fragments of bone were found loose and removed, but there was no large sequestrum. The interior was scraped out with a sharp spoon and sponged with a solution of chloride of zinc 40 grains ad ℥j.

The abscess of the shoulder was then laid freely open, and the finger introduced. A sinus in the bone was found, and a sequestrum of soft carious bone removed. The cavity in which this loose piece of bone was lying appeared to occupy nearly the whole of the interior of the head of the humerus. A drainage-tube was passed into the bone, and the rest of the wound closed with silk sutures.

It is curious that in both these abscesses the respective joints were quite free from disease. The finger was removed at the

proximal phalangeal joint, as the periosteum from which the bone had been removed had produced nothing but unhealthy tubercular granulations.

At the time of the operations above described the lupus scar was first noticed to be thicker than one would expect in such a case. There were a few dilated capillaries, and it had a smooth, shining surface, but there was not that "tucking in" of the skin at the edges, nor were there any spur-like prolongations of the cicatricial tissue. These, however, slowly developed in the course of the next two months.

Now, let us return to the operation wounds. The one behind the left shoulder, and which was quite five inches in length, healed up by first intention with the exception of the place where the drainage-tube emerged. This tube was gradually shortened, and in six weeks there was scarcely any discharge from the sinus. At the end of two months the wound was soundly healed and freely moveable upon the subjacent parts. It was not then noticed to be at all thickened.

The wound in the leg did not do so well. It suppurated throughout its whole length, and produced unhealthy tubercular granulations. A sinus eventually formed in the centre of the leg, some distance from the original wound, with a round, flat, granulating surface. This took place without any swelling or any constitutional disturbance. It was laid open and found to be filled with the same kind of granulations. The large wound resulting from this and the previous operation was thoroughly scraped with a sharp spoon and dusted over with iodoform. It was then dressed with iodoform gauze. In three weeks the same kind of granulations were reappearing. Sulphate of zinc lotion and occasional applications of solid nitrate of silver produced a favorable impression. In a month's time (November 16th) it was nearly healed, and he left the hospital.

By this time (early in November), which was about six months from the date of scraping the patch of lupus, and three months from the extraction of the sequestra, the cicatrix on the right cheek was unquestionably in the condition of keloid. On examining the left shoulder, which had a few weeks before been noticed as a fine linear scar resulting from the union by first intention, I found the whole of it unnaturally thick and glossy. A small patch in the centre, where the drainage-tube had been retained for a few weeks

after the operation, was, of course, the thickest part; but even the remainder, a scar five inches in length, where union had been accomplished by first intention, was slowly assuming the characters of keloid. The suture punctures, which had before been imperceptible, were now indicated by little white spots, which could be felt like shot. The wound in the leg was only partly cicatrised, and the part thus healed was not unnaturally thick. The keloid growths were quite painless.

Through December and up to the present date (January 16th, 1883), he has attended my out-patient room. The scar behind the shoulder has more and more acquired the characteristic features of keloid, whilst the wound below the knee has remained stationary. The finger for a time gave some trouble, but it eventually healed. The scar is rather thick, and will, I think, also develop the other signs of keloid.

It seems as if suppuration in the neighbourhood warded off this growth of tissue, for it is noticeable with the wound in the leg, that in the part which is healed, and has been so for some two or three months, the cicatrix is still quite thin; and during the same time the scar on the shoulder, which was at one time soundly healed, became rapidly thickened. It has now reopened slightly in the centre. In the leg the amount healed is much smaller than the part ulcerated. What influence a part of the same wound remaining unhealed can have upon the rest, I am at a loss to explain. The healed part has had quite sufficient time to undergo the same changes, but it still remains thin.

There are several other curious features about this case. First of all, I think keloid must be an exceedingly rare sequel to the operation of scraping a patch of lupus. I have not been able to find another similar case. Secondly, is the development of keloid to be considered as the result of scraping or merely as a rare sequel to the healing of a sore by whatever means obtained?

In answer to this question we must, I think, look at the causation of keloid generally. It will then be seen that cicatricial keloid follows not only cutting operations but also the most trivial wounds, scratches, &c., and that it is even known to occur after the healing of sores, such as those of smallpox and syphilis, &c., or after the application of a blister. Under these circumstances it is at least probable that the disease would have appeared as soon as cicatrisation had been accomplished, no matter what special treatment had

been adopted to procure the desired result. I do not think that the operation of scraping should be rashly blamed for a disease which appears to arise in the cicatricial tissue of wounds and ulcers alike—wounds that have arisen by accident, as, *e. g.* burns, or been made by the surgeon, or ulcers and sores that have been produced by disease. In the report on Dr. Goodhart's case of keloid, published in the 'Clinical Society's Transactions,' vol. xiii, this view is upheld; and the case that I am now recording seems to me to add additional confirmation, if such were needed, that keloid is essentially a disease of scar tissue. Thirdly, I would ask, is its occurrence due to the individual peculiarity of the patient? A wound made by the knife is followed in this boy by a development of keloid; the healing of lupus effected by scraping is also followed by the same disease. I would submit for the consideration of this Society, whether this is not a case in which one may fairly argue that the development of keloid is dependent upon the idiosyncracy of the patient. If we allow this, it would at first sight seem to explain those cases of spontaneous keloid by supposing that they are particularly susceptible to this change in scar tissue, and that wounds unnoticed at the time of their occurrence eventually develop these keloid growths. On the other hand, if such were the case,—that every trivial injury or scratch has a tendency in it to become keloid, those patients who have this idiosyncracy should have many more similar growths; unless, indeed, the susceptibility to this disease of scar tissue exists only for a time and disappears again. For example, if this boy has this peculiar susceptibility, every wound ought, as soon as cicatrisation has been perfected, to become keloid. I think myself that those which are *now* discharging will become keloid. But are we to suppose that all wounds occurring in the future will develop the same condition? I think not, and therefore I would further ask if this peculiarity on the part of those who are thus liable to this disease is not of a transitory nature? Is it not a sudden outburst?—a tendency which exists for a time and passes away? As far as I have been able to ascertain, there are very few cases bearing on this point.

In the report above alluded to, Mr. Hutchinson is said to have "met with one case in which the scar of a burn took on a keloid growth, and some other scars which had been left by cupping long previously passed afterwards into the same condition." This proves, at any rate, that scars may exist for a long time in a healthy con-

dition and then, on the appearance of keloid elsewhere, themselves become affected in the same way. One would like to know if such patients are liable to further keloid growths with every fresh scar they obtain. It is stated that among negroes this is the case.

Granting, then, that this disease is due to an individual peculiarity on the part of the subject affected, are there any facts to prove that this tendency to the development of keloid ceases to exist after a lapse of time? *January 16th*, 1883.

---

4. *A case of so-called xanthoma tuberosum.*

By Malcolm Morris.

[With Plate XX, figs. 1, 2.]

A case presenting some peculiar points of interest came under my notice this summer, which I have carefully watched and noted, and have the honour of showing to night.

I think I shall do best by at once reading the history of the case before venturing on any comment.

I first saw the patient on May 30th of this year, in consultation with Dr. Dawson of Maida Vale, when the following notes of the case were taken.

Mr. T. S—, aged 48, has been a master builder for fifteen years, and previously to this a stone-mason. During all his life he has been much exposed to the vicissitudes of the weather, especially when engaged as a foreman during the building of one of the Thames bridges some twenty-six years ago. Has been married twenty-five years, but his wife has never been pregnant. He has always had a sufficient quantity of good food and now drinks about a quart of mild ale a day, with an occasional glass of spirits and water at night, but he has never been what may be called an excessive drinker. He has lived in London for twenty-seven years, in his present house four years, and in the one previous sixteen years, and both houses were dry and airy.

He is of medium height but very stout, weighing as much as

EXPLANATION OF PLATE XX.

FIGS 1 and 2.—To illustrate Mr. Malcolm Morris's case of Xanthoma Tuberosum. (Page 278.) From drawings by Dr. G. C. Henderson.

FIG. 1.—Skin containing a small nodule.

a. Stratum corneum.
b. Rete mucosum.
c. Papilla.
d. Nodule.
e. Spots of degeneration.
f. Second nodule represented in outline only. (Hart., oc. 3, obj. 4.)

FIG. 2.—A small portion of margin of nodule.

a. Central portion, showing loose meshwork of connective tissue.
b. Marginal portion, showing round and fusiform cells in matrix.

FIG. 3.—To illustrate Mr. Sutton's paper on Rickets in the Lower Animals. From a drawing by the Author. Microscopic section, showing how the islets are formed. $\frac{1}{4}$ inch. (Page 312.)

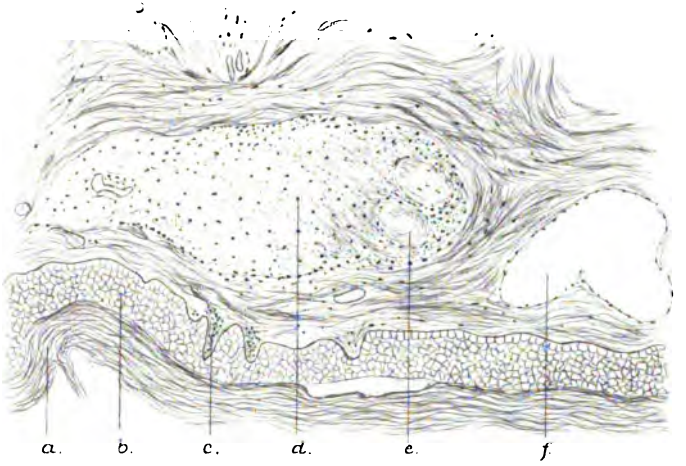

Fig. 1.

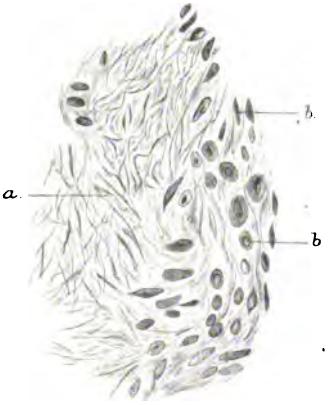

Fig. 2.

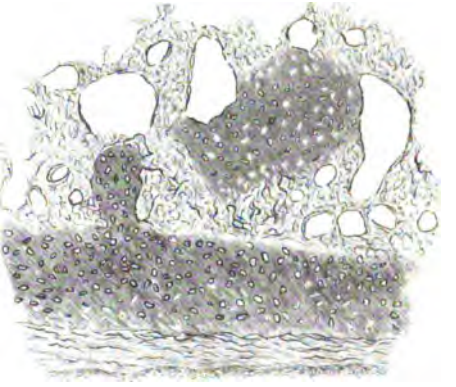

Fig. 3.

Lebert & Co

eighteen stone. Ten years ago he only weighed ten stone, the increase in weight beginning after an accident (fractured patella) which occurred at that time. He seems of cheerful disposition, and his complexion is florid.

Family history.—Father, also a builder, died four years ago, at the age of sixty-two, from decay of nature. He always enjoyed good health with the exception of attacks of rheumatic gout. Was of thin stature. Mother died of dropsy at sixty-one. Enjoyed good health. Father's brother, a farmer, enjoys good health, also his family. Knows of no other relation on father's side. Mother's brother, who is his wife's father, is alive and in good health. Of his mother's two other brothers and sister, he knows nothing. The patient has no sisters; one brother died, he thinks, from apoplexy, another younger brother, a mason, enjoys good health with the exception of severe sick headaches. Has eight children all in good health.

Patient's history.—Has all his life suffered from severe headaches and occasional attacks of giddiness. The headaches have not been so severe of late years. As a young man he was a somnambulist, but on the whole enjoyed good health and strength. When a boy suffered from severe attacks of boils. Never had any form of fever, syphilis, or acute rheumatism. In addition to the accident before mentioned, he broke his left thigh about twenty-six years ago. Has suffered a good deal of dyspnœa on exertion, and palpitation of the heart during the last few years. The eruption suddenly commenced about two years ago on the outer side of the thighs and the extensor surface of the arms, gradually appearing on other parts of the limbs and body. During the last fortnight he says that some of the first swellings have disappeared.

Present state.—He says that now he only occasionally suffers from headaches, he sleeps badly, his sight is dim, and a mist sometimes appears before his eyes preventing him from reading. Other senses are good. Tactile sensibility of feet normal, but there is anæsthesia of the skin of the heel which is most marked on the inner surface. Knee-jerk and skin reflexes normal. Complains of sciatica in left side. Pulse 96, soft; heart weak, the sounds being most distinct at the base, no bruits; lungs decidedly emphysematous. Appetite is fair, but has a continual thirst; bowels regular; has never had jaundice. Liver and spleen normal. Passes a large quantity of urine but is unable to feel the passage of it. It is

pale, turbid, and contains sugar. States that he has lost all sexual desire for some weeks.

The eruption consists of small pink, round, or oval papules, and tubercles, varying in size from $\frac{1}{30}$ to $\frac{1}{4}$ of an inch in diameter, which are mostly discrete, but become confluent on the hands and about the knees. The larger tubercles are of a pale fawn colour in the centre, with a pink margin, and are only slightly raised above the level of the surrounding skin. The smaller papules are situated on the extensor surfaces of both arms, forearms, fronts of forearms, backs of thighs, buttocks, and on the back and shoulders. Some few are scattered on the front of the trunk, and some very minute ones may be seen between the fingers. In addition to those on the skin some papules are to be seen on the tongue and on the mucous membrane of the mouth. There is no itching, but he complains of great tenderness, almost amounting to pain, if the skin of the hands is pressed, also a soreness of the skin generally. A small tumour was removed, with the patient's permission, for microscopical observation.

On the 19th of October I saw the patient again, and found that all the papules on both forearms, and many on the thighs and mouth, had entirely disappeared. The wound caused by removal of the tumour has healed, leaving a brownish scar and no return of growth. He still complains of great giddiness, numbness of both feet, and soreness of the skin generally.

November 6th.—Only very few of the papules are left on the arms and thighs and these are much smaller. Complains of soreness of the scalp and tenderness of the soles and balls of the great toes, but there is no real anæsthesia. Headache more severe. Has a sensation of numbness and soreness on the dorsum of both wrists and over metacarpals, also on the outer part of thighs, just above the knees, which is worse at night. These sensations radiate up to buttocks and down to the calves. Skin dry and harsh, though he sweats on the slightest exertion. Passes a large quantity of water, which is pale, clear, and of acid reaction, sp. gr. 1030, and contains much sugar. There are several papules on the face, which have appeared about a week, but none on the scalp. The papules seen in the mouth on the last occasion are much smaller.

The small nodules when incised and squeezed gave out only a little blood; no pus or oily matter. An incision through a nodule proved it to be firm in texture.

Microscopical examination of nodule.—Sections of the small tumour stained with logwood and eosin, show small nodules in the substance of the corium gradually merging into it, while the more recent nodules are composed of oval and fusiform cells lying in a slightly fibrillated connective-tissue matrix. The central parts stain less deeply than the margin, and have a granular appearance, in which the outline of cells and fibres can be faintly distinguished. The papillary layer and epidermis are unaffected. The developed nodules show no sign of having commenced in connection with sebaceous or sweat-glands, hair follicles, or blood-vessels; there are no blood-vessels to be seen in the growth. In the corium, but entirely separated from the nodules, are seen networks of dilated thin-walled vessels, around which are collections of round and oval cells. It is possible that these collections of cells represent the early stage of the growth, and if so a hypothesis might be suggested as to the subsequent history of it. As the cells become gradually organised into fibrous tissue contraction would take place, reducing the size of the nodule and compressing the vessels in the interior. In this way the absence of blood supply would favour the degenerative changes in the centre of the nodule.

Remarks.—The names Xanthoma, Xanthelasma, and Vitiligoidea have all been used by authors to describe a peculiar disease of the skin. It is usual also to mention two varieties—Xanthoma planum and Xanthoma tuberosum. I have called my case, which I show to-night, by the latter name, not that I think it a good one, but because it is the most familiar. In many particulars, both clinical and microscopic, it seems to me to differ from what I may call true Xanthoma or Xanthelasma. I say "true Xanthoma," because the name is now always associated with a fairly common disease, whereas I think the case under consideration is an example of a very rare variety, as I can only find two recorded cases that in any way seem similar.

In his elaborate paper on Xanthelasma, published in the 'Medico-Chirurgical Transactions' for 1871, Mr. Hutchinson says that the disease to which the term "vitiligoidea tuberosa" is chiefly applicable, having been twice noticed in association with diabetes, and having in both instances come out suddenly, presenting marked differences from ordinary xanthelasma, and also showing a tendency to cure, is in all probability a distinct malady; and in another part of the paper he states that two at least of the cases published by

Dr. Addison in his first paper are not examples of true xanthelasma, and one of them probably belongs to a wholly different category, in which a very peculiar eruption occurs in connection with diabetes.

The following is a short abstract of the case from Dr. Addison's and Dr. Gull's paper in the 'Guy's Hospital Reports' for 1851:

John Sheriff, aged 27, of middle stature, by occupation a tailor. For about six months passed a large quantity of water, and on admission to the hospital presented all the ordinary signs of diabetes. At this time an eruption somewhat suddenly appeared on the arms, at first apparently of a lichenous character. In ten days it had extended over the arms, legs, and trunk, both anteriorly and posteriorly; also over the face and into the hair. It consisted of scattered tubercles of various sizes, some being as large as a small pea, together with shining colourless papules. They were most numerous on the outside and back of the forearm, and especially about the elbows and knees, where they were confluent. Along the inner side of the arms and thighs they were more sparingly present, and entirely absent from the flexures of the larger joints. Some looked as if they were beginning to suppurate, and many were not unlike the ordinary molluscum; but when incised were found to consist of firm tissue, which on pressure gave out no fluid save blood. The eruption continued almost stationary from the end of January to the beginning of March, when many of the tubercles began to subside, leaving no obvious change in the texture of the skin. At the end of March patient left, and the further course was not ascertained.

I may mention here that Dr. Fagge ('Path. Soc. Trans.,' 1868), while speaking of cases of xanthelasma associated with jaundice, says that the above-mentioned case was probably of a different kind.

The other case, which seems to be of the same nature, is reported by Dr. Bristowe in the 'Pathological Trans.' for 1866, as a case of keloid. In bringing it under the notice of the Society, Dr. Bristowe says his object was to put on record a rare and interesting case of skin disease. The following are brief notes:

T. H—, a tailor, aged 43, had an eruption limited to various parts of the hands, wrists, feet, and ankles, the elbows, knees, and buttocks, the rest of the skin being healthy. The eruption consisted of somewhat indurated tubercles of a dull reddish hue, and of roundish or obtusely conical form. Their margins passed insensibly into the healthy skin around, and their apices were often of a

pale yellow colour, as though containing a minute collection of pus. The yellowness was not due to accumulation of fluid, for the apices, like the rest of the tubercles, were solid.

The tubercles appeared microscopically to consist of a kind of dense fibrillated texture, studded more or less with oil-globules of various sizes. The parts affected were tender, however, and the patient complained of a painful pricking sensation in them. After a further description of the eruption, Dr. Bristowe calls attention to the fact that the patient suffered from diabetes.

In a note, published three months after the paper, Dr. Bristowe says that the disease has undergone great improvement, many of the tubercles and patches have wholly disappeared, and all of them are less prominent and less distinct. This improvement seems still in rapid progress.[1]

The three cases are so much alike, I think there is but little doubt that they are examples of one disease, but whether that disease is xanthoma or xanthelasma is a matter for consideration. At all events there are several points in which they differ materially from true xanthelasma. The points that link the cases together are :

1. Diabetes.
2. The character of the eruption and its distribution (the eyelids being free).
3. The sudden appearance and the gradual disappearance of the eruption.

The points that distinguish the three cases from true xanthelasma are:

1. The diabetes.
2. The absence of the disease from the eyelids.
3. The gradual disappearance of the eruption.

As regards this third point, Mr. Hutchinson has given it as his opinion that true xanthelasmic patches never disappear, but either remain stationary or gradually increase. Dr. Frank Smith and Dr. Wickham Legg have each reported a case in which the patches did get smaller; but still the fact remains that in the majority of the cases they are permanent.

It is of interest to note that all the three patients are of the male sex, whereas true xanthelasma is much more common in women.

November 7th, 1882.

[1] Dr. Bristowe wishes me to state that he now considers his case a variety of xanthoma associated with diabetes, and not a form of keloid.—Sept. 13th, 1883.

Report upon Mr. Malcolm Morris's case of so-called Xanthoma in connection with diabetes.—The Committee have examined Mr. Malcolm Morris's case, and have nothing to add to his careful clinical description of the lesions.

The Committee are of opinion that Mr. Morris is so far justified in calling the case xanthoma, as it is closely paralleled by Dr. Hughes' case, which Addison included in his original description of xanthoma, or, as he called it, vililigoidea ('Addison's Works,' Syd. Soc. ed., p. 160).

The Committee consider that two other cases are on record which resemble these, one by Dr. Bristowe ('Path. Soc. Trans.,' vol. xvii, p. 414), already alluded to by Mr. Morris; the other a case in Dr. Hillairet's clinique reported by Gendre in his 'Thesis on Xanthelasma.'

The ages of these patients ranged from twenty-seven to forty-eight years; three were male and one female. They resembled each other in the following particulars:

1. All of them suffered from diabetes mellitus; in one the eruption probably preceded the diabetes.

2. The outbreak of the eruption was sudden in three; in the fourth there is no statement on this point.

3. Involution occurred in all, and was rapid when it once commenced, but the disease was stationary for a long period. The duration varied from three months to five years.

4. In all the elbows and knees were affected, and the eruption was confluent in those positions, though not at first; in three cases the face and buttocks were affected.

5. Dilated vessels upon the lesions are reported in two cases; no mention in the other two.

6. In all the eruption consisted of red, firm papules, some only of which had yellow tops which looked like pus, but incision showed them to be solid.

7. The eruption was confluent in some parts in all the cases.

8. Altered sensations, tenderness, pricking, or irritation, are noted in three; in one shooting pains preceded the eruption.

These features more or less in common suggest that the cases belong to one group, but the Committee have grave doubts whether that group is xanthoma multiplex from which the cases differ in the following points:

1. The sudden evolution and involution of the eruption.

In xanthoma the development of the disease is slow and involution is quite exceptional, it having occurred in four only out of twenty-eight adult cases, and was then very gradual indeed.

2. The lesions are firm and solid, while they are soft in xanthoma.

3. Some only are yellow, and these only at the top; in xanthoma they are always some shade of yellow, and the whole region is of uniform colour.

4. There were never any patches or striæ, a common feature in xanthoma multiplex; all the lesions were tubercles or infiltrations distinctly raised upon the surrounding skin.

5. There was no jaundice, a very rare omission in *adult* xanthoma multiplex, and unless the cases in question are considered to be xanthoma, diabetes mellitus has never been observed associated with xanthoma, though diabetes insipidus has been noted associated with eyelid xanthoma.

6. The lesions appeared in many instances to be in the immediate neighbourhood of hair follicles, a lesion not observed in xanthoma.

7. The microscopic characters are not those characteristic of, and very constant in, xanthoma.

Although the number of such cases is too small for absolute statements, yet they are evidently, both etiologically and symptomatically, closely related, and appear to form a definite group, with many of the features of lichen. Should further experience show that diabetes mellitus is a constantly associated condition, the name of lichen diabeticus would seem to be an appropriate designation, or, if Mr. Hutchinson's view be correct, xanthoma diabeticum.

H. Radcliffe Crocker.
Alfred Sangster.

Postscript by Mr. Hutchinson.—Whilst agreeing in the main with the preceding report I am still inclined to regard the disease as a near ally of xanthelasma, and should prefer such a name as xanthelasma of the diabetic. I had through the kindness of Mr. Malcolm Morris a second opportunity of examining his patient some months after we had met in committee. I then found in the left knee a group of spots which, when the skin was stretched, became distinctly yellow exactly as those of xanthelasma do. On

the other knee was a similar group which did not show any yellow tint, and none of those on the tips of the elbows were definitely yellow. JONATHAN HUTCHINSON.

---

5. *Case of symmetrical gangrene.*

By REGINALD SOUTHEY, M.D.

[With Plate XXI.]

SOPHIA C—, aged 2¾, the only child of young parents, was brought to me at St. Bartholomew's Hospital, December 3rd, 1882, at 12 noon, with characteristic patches of black purple lividity, symmetrically situated on both legs from pelvis downwards, and on the backs of both arms, just above the elbows; both buttocks presented black discoloration exactly in the situation most likely to be determined by pressure, and both thighs were affected in less degree, each over its trochanter major.

Her face and the rest of her skin presented an ashen pallor. Her eyes were of grey-blue colour, the conjunctivæ dry and tearless, the lower lid border shaded by a violet shadow, recalling though in minor degree the hollow eyed lack-lustre look of the collapse stage of cholera. Tongue quite moist but singularly thin, folded, indented, bloodless, and collapsed. She was perfectly conscious, but apparently frightened, appeared to suffer no pain unless her legs were moved, remained very motionless just as she was laid, and took little notice of what passed around her, although watching her mother's face and movements intelligently. Axilla temp. 99·4°, pulse 120, small, a little wiry at wrist; resp. 24. The heart sounds were quite clear, its action regular, impulse feeble. The respiratory movements natural, and no abnormal sounds were audible over lungs.

She swallowed a little hot milk and brandy, passed a slight motion about 2 o'clock without any blood in it, and a little separate urine which was alkaline and spontaneously deposited urates and some amorphous phosphates; it contained 5 per cent. albumen. The sediment contained no casts, and no blood cells, and gave no particular blood reaction. She was placed in a tepid

DESCRIPTION OF PLATE XXI.

Illustrating Dr. Southey's case of Symmetrical Gangrene of the Extremities, causing death on the third day, in a child two and a half years of age. (Page 286.)

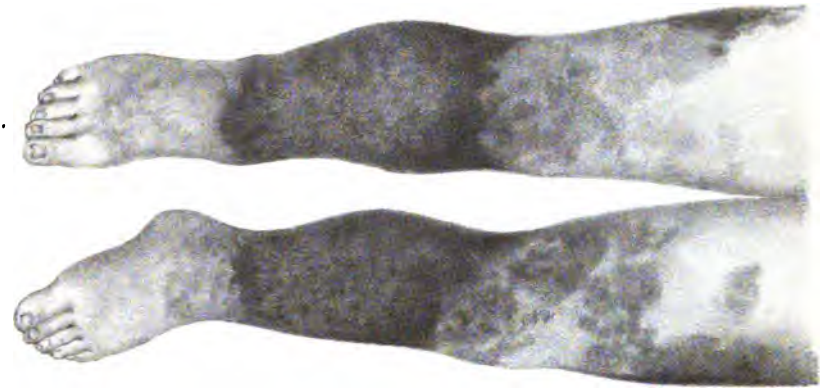

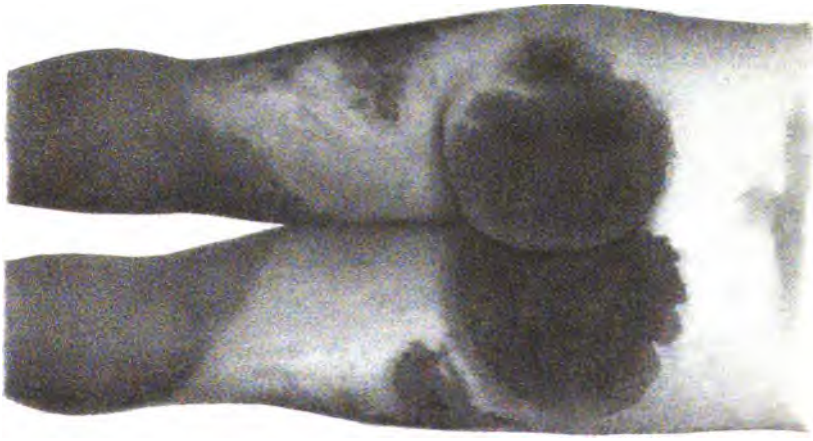

T Godart del.

F Huth Lith^r Edin^r

bath at 95° Fahr., the temperature of which was gradually raised to 99°; she soon said that she felt hot and was removed to bed. She complained of no pain, asked for drink, and sat up in bed to drink some milk and brandy. At 9.45, or a few minutes later, she had a convulsion in which her hands were clenched and arms flexed, but knees not moved; her eyes were wide open and pupils dilated and fixed; the respiratory muscles were much implicated. The first convulsions were the most severe, as they became repeated at shorter and shorter intervals their severity diminished; no pulse could be felt at the wrist after the first convulsion, and she never regained consciousness, the convulsions persisting with few interruptions until her death, which occurred in two hours from the first fit, and about thirty-two hours from the occurrence of the first patch of local asphyxia on both calves.

The *post-mortem* was made by Dr. N. Moore.—The aorta, iliacs, left femoral artery, and the arteries continued therefrom into the patch of gangrene, or local asphyxia of left leg, were dissected out but presented no embolus, no clot whatever. The veins were perfectly free from thrombosis. The blood in the heart and everywhere else was fluid, like black cherry juice. No coagula were discernible.

The heart and lungs were perfectly normal in appearance. Liver, kidneys, stomach, and intestines also. The spleen was rather enlarged, dark coloured, and somewhat soft. The brain looked quite healthy and firm, and the spinal cord also looked firm and felt healthy, two or three sections into it revealed nothing; it was reserved for minute examination.

The gangrenous or asphyxiated parts showed upon section that the skin and connective tissue were principally if not solely the seat of stasis and extravasation. The muscles were blood stained about their sheaths, but not in their substance. Hæmatin and blood cells were effused, with a large amount of blood serum, looking like the extravasation from a great bruise into the cellular tissue. The skin itself had been distended and felt tough and hard therefrom during life. There was no effusion into any joints, a fact contra-indicative of hæmophilia, although not altogether excluding it.

Mr. Gresswell obtained a more correct history of the child's illness from the mother which I will now append, and also personally examined the father.

The husband, from his teeth, his own family history and aspect,

was probably the subject of congenital syphilis himself. He was born fifth in a family of seven, of whom one, a male, died in infancy; one male is married, and has two healthy children. Four females survive.

a. Eldest. Married, has eight children. One premature birth. Two died in infancy. One at thirteen of dropsy and abscesses; ill three months. One had syphilis congenitalis.

b and *c.* Living but not known where.

d. Married, without children.

The father of our patient was the third son, he married (aged twenty-one) a healthy domestic servant of nineteen years; is a sawyer by trade, earning good wages, and fairly well off. The only illness he ever had was vomiting of blood two years ago, when this child was six months old.

Previous history of patient.—She was suckled by mother for twelve months, then fed on good milk and Ridge's food. Was apparently in perfect health up to October, 1882, when she had an attack of febrile purpura. Her head, legs, and feet aching, crimson spots appearing on the ankles and calves. She was feverish and fretful for a few days, during which she was kept in bed and vomited a little.

On November 13th she again suddenly became feverish, burning hot all over, could eat nothing, was languid and drowsy and slept for the best part of three days. She then picked up suddenly and enjoyed good health up to present illness.

This began on Friday evening, December 1st, when she complained suddenly of her head, and put her hands to her forehead. She was neither sick nor feverish. She ate her tea, was put to bed, slept well, woke up on Saturday, December 2nd, lively, and ran about as usual, making no complaint whatever until the afternoon at 4.30, when she came to her father saying she had hurt her legs. He noticed a slate-coloured patch on each calf, surrounded by a red margin, and thinking she had bruised them proceeded to rub them. At this the child began screaming violently. Shortly after this she was undressed by her mother and put to bed. At that time the livid patches were limited to the calves, but tended to encircle the skin in front and below the knee.

Examined at 9.30 the same night. The original patch was larger and of a much blacker hue, the slate coloration had extended upwards and downwards; upwards along the inner and posterior

aspect of each thigh, downwards, entirely encircling the ankles and feet. She was sick several times, bringing up milk chiefly; she could not bear anything touching her legs, and screamed frequently, having little or no sleep throughout that night.

About 3 a.m., December 3rd, two symmetrical livid and purple patches appeared on the posterior aspect of each upper arm, two inches above each elbow, and at 6 a.m. the parents first caught sight of two similar but larger and blacker patches situated on the buttocks.

The mother in answer to my questioning her on bringing the child to the hospital told me, that the bowels had acted that morning naturally, and were generally freely open. She had also passed a little red thick cloudy urine; no blood had been noticed in urine or action that day or at any past time.

December 5th, 1882.

---

6. *The bacilli of leprosy.*

By GEORGE THIN, M.D., for J. D. HILLIS, M.D., of Demerara.

[With Plate XXII, figs. 1, 2, 3, and 4.]

THE drawings show the appearances presented by the bacilli of leprosy in a section of skin excised from a leprous tubercle. Dr. Hillis sent the portion of skin, which had been placed in alcohol immediately after excision, to Dr. Thin with the request that preparations and drawings should be made and shown to the Pathological Society. The sections were stained in Dr. Thin's laboratory, and the drawings, which are faithful representations of the microscopic appearances, were made by Mr. Thurston.

FIG. 1 is a vertical section through the skin (Negro-skin), to show the distribution of the bacilli in the cutis. The magnifying power (150 diameters) is not sufficient to show the individual bacilli, but the lepra cells which contain them indicate their distribution.

FIG. 2.—The lepra cells and the individual bacilli, stained with fuchsine. In the preparation the oval nuclei in the connective tissue are stained with methyline blue (× 550).

FIG. 3.—A lepra-cell, with bacilli highly magnified (1230 diameters), stained with fuchsine. The nuclei surrounding it belong to the onnective tissue.

FIG. 4.—Individual lepra bacilli, highly magnified (1230 diameters). The grouping of the bacilli is artificial.

DESCRIPTION OF PLATE XXII.

FIGS. 1, 2, 3 and 4.—Illustrate Dr. Hillis's communication upon the Bacilli of Leprosy. (Page 289.)

From drawings made by Mr. Thurston.

FIG. 5.—To illustrate Mr. Eve's paper upon Congenital Hypertrophy of Limbs. (Page 298.)

Drawing of a microscopic section of the skin of the hand, from a case of congenital hypertrophy of the hand and arm.

a a. Spaces formed by the separation of the rete mucosum from the thickened corium.
b. Dilated lymphatics.
c. Scaly cuticle.
d. Rete mucosum. (× 100 diam.)

From a drawing by Mr. Eve.

Fig. 5

Fig 2

Fig 3

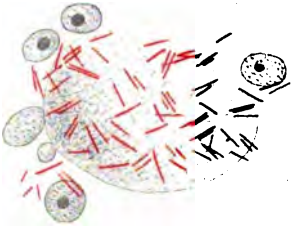

Fig 1



Fig 4

Mintern Bros sc

XI. MISCELLANEOUS SPECIMENS.

1. *Anthrax of face.*

By N. Davies-Colley, M.C.

[With Plate XVII, fig. 2, Plate XVIII, fig. 3.]

Albert B—, aged 43, employed at a leather warehouse in Tooley Street, was admitted, under the care of Mr. Davies-Colley, into Guy's Hospital on February 20th, 1883.

On February 15th he scratched his face with a hide carried by a fellow-worker. That evening he noticed a red swelling about the size of a split pea on his chin, and he had a rigor. He was unable to sleep that night. The swelling gradually increased. He could not take any solid food, and at night he was delirious. He would have come to the hospital, but was too ill to go out of doors. On the 18th he began to cough. There was no diarrhœa.

On admission, he was a strongly-framed and well nourished man, but extremely weak and unable to stand. Just behind the right angle of the mouth was a firm swelling rising abruptly from the adjacent skin to a height of about $\frac{1}{6}$th of an inch. Its surface was nearly flat, but the central part was depressed about $\frac{1}{20}$th of an inch below the surrounding level. It was of a bright red or orange crimson colour, smooth, shining, and somewhat pellucid, while the concave central depression was covered by a thin purplish-black scab. Its dimensions were from before backwards $1\frac{1}{3}$th inches, from above downwards $\frac{2}{3}$th of an inch. The skin around was somewhat swollen, but little if at all reddened. There was considerable swelling of the soft parts from the corner of the mouth to $1\frac{1}{2}$ inches behind the mastoid process, and from the lobule of the ear to below the level of the angle of the jaw. The eyelids were not affected. Two or three large glands could be felt indistinctly below the parotid gland; the largest was about 1 inch long.

There were numerous small herpes vesicles upon the lips. The swelling was not painful; he likened the sensation in it to the "gnawing of a mouse." His temperature was 99·3°, his pulse 80. Chloroform was at once administered; the tumour was cut out, and the exposed surface cauterised. A little tannic acid was also applied to check hæmorrhage. Numerous bacilli were found in the bloody serum which oozed from the surface of the swelling when it was punctured. None were seen in the blood which was prepared in the same way with aniline violet. The adjacent swelling disappeared in a few days, and the wound soon became covered with healthy granulations.

His temperature rose to 101° on the night of the operation, but then fell and afterwards remained about normal. His pulse was always slow. He had a rather troublesome cough, and two days after the operation the bronchitic sputum which he was bringing up was found to be full of large bacilli, like those which had been seen in the serum scraped from the anthrax. Similar bacilli were also found in the urine, sweat, and fæces. He complained occasionally of pain in the head, between the shoulders, and in the lower part of the abdomen. He also suffered from attacks of faintness, without loss of consciousness, and at times perspired very freely.

On March 11th, without any apparent cause, severe diarrhœa came on, accompanied with discharge of a little blood and mucus.

On the 13th bacilli were still numerous in the sputum and fæces.

On the 20th he went out, still passing a few bacilli in his urine, but otherwise well.

He was again seen on April 7th. There were no bacilli in his urine. He still suffered a great deal of pain in the back between the shoulder blades. He had a slight cough, but nothing abnormal could be detected upon auscultation of the heart and lungs.

As far as I can learn, no specimen of anthrax, or "malignant pustule," has hitherto been exhibited to this Society. During the last ten years the disease has been frequent among the workmen employed at the wharves and leather warehouses of Bermondsey. At Guy's Hospital we have, during that period, treated more than twenty cases of this disease, and I published an account of seventeen of these in the 'Medico-Chirurgical Transactions.'[1]

The hides among which the man had been working were foreign,

[1] Vol. lxv., page 237.

from China, Australia, and the Cape. A fellow workman was similarly infected a few days later and died. The workers in leather are familiar with the dangers of anthrax, but they attribute the disease to the arsenic used in the preparation of the hides.

This case was different to all the other cases of anthrax which I had previously seen, in the absence of distinct vesicles upon the margin of the eschar. The indurated swelling which formed the anthrax eschar appeared to be due to an infiltration of bloody serum into the superficial layers of the corium. Ordinarily the parts near the margin of these eschars are covered with small pearly vesicles. In this case they were smooth, and the swelling resembled a tense and very firm nævus. The virulence of the disease was shown by the rapidity with which constitutional symptoms appeared. Usually it is not till the third or fourth day that the affection spreads from the primary eschar to the system. In this case there was a rigor the same evening, followed at once by sleeplessness, delirium, and complete prostration.

Notwithstanding this early onset, and the strong hold which the disease had obtained upon the system, as shown by the bacilli which were observed in the excreta as late as four weeks after the operation, it is interesting to note that the removal of the anthrax was followed by the complete recovery of the patient.

March 6th, 1883.

---

2. *A case of charbon, or malignant pustule.*

By Thomas Bryant.

[With Plate XVII, fig. 3, and Plate XIX.]

William S—, aged 33, a worker amongst foreign hides, was admitted into Guy's Hospital on February 26th, 1883, under my care, with a well-marked malignant pustule on his left cheek.

He had noticed its first appearance four days previously when he awoke in the morning, and the pustule was then about the size of a pea; by night it had much increased, and the glands beneath the jaw became enlarged. He did not at this time feel ill. The next

day, however, when at work, between 4 and 5 p.m., he began to feel unwell, and he could not eat his meals. Getting rapidly worse, he came to Guy's on the fourth day, retching and shivering having come on.

On admission he had a very congested appearance, and his hands, feet and ears were cold, blue, and almost cyanotic. Pulse 132, feeble; temperature 100·2°; sweating profusely. He was so feeble that he could not stand. On his left cheek was a raised swelling of a very dusky hue, with a black slough in the centre, and discharging vesicles about its borders. The pustule was surrounded by an area of redness (see Plate XVII, fig. 3). The neck, from the jaw downwards as far as the clavicle, was much swollen from œdema, and the lymphatic glands were enlarged.

I saw the man within two hours of his admission, and at once excised the pustule with the surrounding parts, and applied some carbolic acid to the surface of the wound.

The operation, however, did no good; and the man sank nine hours after.

He did not complain of pain after the operation, but only of thirst. Eight hours after, he complained of having had a dreadful dream, and that he felt light-headed. He had then rapid breathing; he also vomited. During the last half hour of life his respirations were of a puffing character. Bacilli were found in abundance during life in his saliva and urine.

The *post-mortem* record I leave to Dr. Mahomed, who made the inspection.

This was the second case from the same wharf within one week, the first having been under the care of my colleague, Mr. Davies-Colley; and the notes of which are recorded in the communication preceding. *March 6th*, 1883.

Case of malignant anthrax (charbon), with anthracoid affection of intestine, stomach, and lung. By F. A. Mahomed, M.B.—The specimens exhibited are from W. S—, aged 33, whose case is recorded by Mr. Bryant in the preceding communication.

The following extract is taken from the *post-mortem* report, which was made by myself twelve hours after death:

Body generally cyanosed; rigor mortis well marked; much hypostasis. Nutrition good.

Head.—A few small patches of blood-staining in the pia mater,

DESCRIPTION OF PLATE XIX.

FIG. 1 represents the appearance of the mucous surface of the cæcum and colon of Mr. Bryant's and Dr. Mahomed's case of Facial Anthrax. (Page 294.)

FIG. 2 represents the appearance of the stomach of the same patient.

From drawings by W. Hurst.





especially over the side of the right hemisphere. Brain, 52 oz.; healthy. Cervical glands vascular and somewhat swollen on the left side, but no great enlargement.

Pleuræ.—Slight adhesions at apices. No recent pleurisy.

Lungs.—Dark nodules scattered over the surfaces of both lungs, most numerous at the bases, especially the left. They are slightly raised above the surface and feel solid to the touch. On section, the lungs appear healthy, except for the dark red nodules dotted here and there. Some of these are solid to the touch, others scarcely distinguishable. They are not softened; there is no pneumonia surrounding them, nor any œdema; they resemble hæmorrhages into normal lung tissue. They are not very numerous, certainly not more than twenty in all. The *absence* of inflammation, in the surrounding pulmonary tissue was remarkable. The larynx was normal; tracheal mucous membrane congested; bronchial glands not enlarged.

Pericardium.—Some well-organised lymph on the visceral layer, otherwise normal. No hæmorrhages.

Heart.—13½ oz. Muscle good; valves normal. Aorta good; slightly blood-stained. The blood was unusually fluid in all the vessels, and of dark colour.

Peritoneum.—The peritoneal cavity contained about two pints of dark yellow-red serum. Patches of congestion could be seen through the peritoneum covering the small intestine at the spots corresponding to what I shall subsequently describe as the anthracoid nodules, but there was no lymph on the peritoneal surface.

Stomach.—Mucous membrane thick and mammillated; coated with tenacious mucous. On the anterior wall, about the middle of the lesser curvature, is an oval patch, ¼ by ⅛ inch, in the centre of which is a small dark slough, part of which appears already to have separated, and the remainder is being rapidly thrown off, leaving the muscular wall of the stomach exposed over the surface mentioned above. Close to this, a little nearer the pyloric orifice, is another small ulcer, about ⅛ by ¼ inch, from which the slough has entirely separated. These appear to have been small anthrax nodules in process of natural cure. (These are represented in Plate XIX.)

Intestines.—Passing down from the pyloric orifice, the following conditions were found distributed pretty equally throughout the small intestine. In the duodenum and jejunum were found nume-

rous anthrax growths; in this part of the intestine they invariably followed the line of the valvulæ conniventes. A portion of such a valve, varying in length from ¼ to 1½ inches, would appear with a black, or rather dark brown, slough occupying the free edge of both surfaces, much like the brownish slough which appears on the skin. Surrounding this would be an area of hyperæmia, with some swelling of the mucous membrane, varying in size according to the slough, but with a radius of not more than an inch in the largest. The peritoneal surface was hyperæmic, but no lymph appeared upon it. Lower down, where the valvulæ conniventes disappeared or became less marked, the anthracoid nodules became merely circular patches of raised, blackish-brown sloughs, with a surrounding area of vascularity; in the lower part of the ileum the solitary glands were remarkably large and prominent, but there was no increased vascularity about them, nor any sloughs in their centres. The cæcum was remarkably œdematous; its walls ⅜ to ½ an inch thick, from pure œdema; no redness. It contained several anthracoid nodules in its cavity, and around these were the usual vascular zones. They were also scattered down the upper part of the large intestine. (The plate shows the appearance of the nodules in the cæcum and lower part of the ileum, but the artist has been unable to give any idea of the remarkable, translucent, œdematous swelling of the part.)

Liver.—57 oz. One small cretaceous nodule on posterior surface of right lobe, otherwise healthy; no infarcts. Gall-bladder contained about ¾ oz. of healthy bile.

Pancreas.—Normal.

Mesenteric glands.—Not notably enlarged, but on section they were vascular and of a purple colour; some of them appeared to contain small ecchymoses, but without any notable swelling of the gland.

Spleen.—6½ oz. Not much enlarged, but too soft and diffluent to cut.

Supra-renal capsules.—Normal.

Kidneys.—12½ oz. Healthy. No hæmorrhages.

Bladder, prostate, and *testes* all healthy.

Note.—The nodules in the lungs were subsequently found to contain large numbers of the *Bacillus Anthracis.*

Remarks.—The following lesions frequently found in cases of internal anthrax were only slightly represented in this case: (1) the characteristic anthrax œdema—this was only seen in the mucous

membrane of the cæcum; (2) hæmorrhages in the skin and viscera—these were only observed in the pia mater, and there only in small numbers; (3) blood-stained serous effusions into the pleural and pericardial cavities—a similar effusion was, however, found in the peritoneal cavity. The presence of anthracoid nodules in the intestine has not been recorded in England. Mr. Spear, in his report of the disease at Bradford, states that it was not present in any of his cases: it has only been seen once in the cases that have been admitted from time to time at Guy's Hospital. Blavot, in his Strassburg thesis (1863), states that the intestinal lesions were nearly constant. It is probable that the method of infection, whether by inoculation, by the air, or by food, largely determines the seat of the chief lesions. In Bermondsey inoculation plays the chief part in the propagation of the disease, and at Guy's Hospital we are therefore familiar with cutaneous anthrax; in Bradford, infection arises by atmospheric diffusion of the germs, and pulmonary lesions are frequent.

It is especially noteworthy that in the stomach and intestines some of the nodules were seen to be undergoing the natural method of cure—that of casting off the sloughs. Mr. Spear records a similar result, with favourable termination, to the cutaneous nodules. Anthrax, or *charbon*, is by no means a necessarily fatal disease. Bollinger, in his article in Ziemssen's 'Encyclopædia,' gives the mortality in animals at about 70 to 80 per cent., and in man (if actively treated) from 5 to 10 per cent. only. It varies very greatly in its intensity from truly malignant ("apoplectiform," as Bollinger calls it), to acute, subacute, and chronic. While the acute attacks may be very slight, the well marked ones are said by Dr. Bell to terminate usually by the seventh day, either fatally or by improvement tending to recovery. In this case we had small sloughs in process of separation from the stomach and intestine on the fifth day of the disease, in a case which appeared to have commenced by cutaneous inoculation. *March 6th*, 1883.

3. *Micrococci in Pyæmia.*

By Victor Horsley, B.S.

The specimens shown were from two well-marked cases of pyæmia, in which there were numerous foci of suppuration in the bursæ and joints, but scarcely any lesion (in one case none) in the internal viscera. All the abscesses showed numbers of micrococci growing in chains, while the blood was free from any organism. *December 19th*, 1882.

---

4. *Two specimens of congenital hypertrophy or giant-growth of limbs.*

By Frederic S. Eve.

[With Plate XXII, fig. 5.]

I. Congenital hypertrophy of the foot and leg, especially of the skin and subcutaneous tissue of the sole.

This specimen was presented by Mr. C. Macnamara to the Royal College of Surgeons' Museum.[1] I am indebted to Dr. Hebbs, Surgical Registrar of the Westminster Hospital, for clinical notes of the case.

History.—The patient, a well-nourished woman, aged 24, stated that the left foot had been larger than the right since birth, but that it had rapidly increased in size during the last seven or eight months. It gave her no pain, but she experienced from its weight much difficulty in getting about. She therefore desired that the leg should be amputated. She noticed an enlargement of the sole of the right foot four months before admission into hospital.

Mr. Macnamara performed amputation through the lower third of the left thigh, and the patient died with inflammation of the stump and hectic fever on the third day.

The left leg and especially the left foot were enlarged in all their

[1] The specimen is preserved in the College Museum, No. 4061*a*.

dimensions. The amount of enlargement is indicated by the accompanying measurements :—

	Left.	Right.
From point of great toe to heel . . .	18 inches	8½ inches.
Around instep	14 „	9 „
Circumference of great toe	10¾ „	2¾ „
Ditto of calf of leg	13½ „	10½ „

The foot was generally enlarged, as its increased length plainly shows, but its immense bulk was chiefly due to hypertrophy of the skin and subcutaneous tissue of the sole. The skin of this part was thrown into prominent, firm, transverse folds with deep intervening fissures. This condition was limited to the sole, the altered skin of which projected in rounded lobulations around the sides of the foot. The soft tissues of the toes were immensely increased, and formed a rounded mass at their extremities of softish consistence. (The growth around the great toe was removed before amputation of the leg was performed. The wound became sloughy, and this circumstance in part determined the major operation.) The skin of the dorsum of the foot was slightly thickened and much wrinkled ; parts of the surface were covered with very long, fine hairs.

A longitudinal section of the foot showed that the overgrowth of the sole was due chiefly to hypertrophy of the skin and subcutaneous tissue, and in part to excessive formation of fat beneath the distal extremities of the metatarsal bones.

The bones of the foot retained generally their natural form, but the posterior part of the os calcis was enlarged ; the posterior half of the first metatarsal bone was nearly two inches in thickness, and was united with the cuneiform bone ; and beneath the head of the same metatarsal bone was a semilunar mass of cancellous bone, about three-quarters of an inch in thickness. The cancellous tissue of all the bones was soft, and the medulla appeared fatty.

Sections of the hypertrophied skin of the sole showed, under the microscope, thinning of the rete mucosum, with almost complete obliteration of the papillæ. The increase in thickness of the corium was extreme ; it consisted of tortuous bands of dense but indistinctly fibrillar tissue with rather wide intervening spaces, which were shown by injection to communicate freely with the lymphatic system. The lymphatics did not appear dilated. The blood-vessels of the foot which were injected appeared relatively small. The sole of

the right foot presented a slight degree of the morbid change affecting the left.

Many other abnormalities existed in other parts of the body, most of which were apparent during life. There was lateral asymmetry of the head and face, the left side being the larger. The left half of the tongue was markedly larger than the right half. The same asymmetrical enlargement affected all parts of the left side of the brain. Several osseous growths, of the size and shape of peas, occupied the dura mater.

A fibrous tumour the size of a filbert grew from the sclerotic on the outer side of the left cornea. A fibrous epulis the size of a pigeon's egg sprang from the left upper jaw. The uterine mucous membrane was everywhere covered by a thick villous growth. The left patella was involved in a large osseous growth 6¾ inches long by 6½ inches wide.

The index and middle fingers of the left hand, and the middle and ring fingers of the right hand, were deformed by a lateral inclination to the radial and ulnar sides respectively, but were of natural size.

II. Congenital hypertrophy of the hand and forearm.[1]

The patient, a tinman, aged 38, was admitted to St. Bartholomew's Hospital, under the care of Mr. Morrant Baker.

He stated that his left hand had always been larger than the right, but he was able to work with it without inconvenience until the last year, when it began to grow rapidly.

Nine weeks before admission the skin on the back of the metacarpal bone of the thumb became ulcerated.

Amputation through the lower third of the forearm was performed by Mr. Baker.

The whole of the hand and the fingers were greatly but proportionately enlarged. The hand measured 7 inches across the dorsum from the fifth metacarpal bone to the metacarpo-phalangeal joint of the thumb. The circumference of the middle finger around the first phalanx was 5 inches, while that of the right was 2½ inches. The enlargement of the fingers was much greater at their bases, and they gradually tapered to the extremities which were but slightly enlarged. The nails were natural in thickness and shape.

[1] The specimen is preserved in the museum of St. Bartholomew's Hospital, No, 2694*a*.

The wrist and forearm were slightly enlarged, indurated, and tender. Lymphatic vessels could be traced as fine knotted cords along the inner side of the arm.

Upon the dorsal surface of the metacarpal bone of the thumb was a foul ulcer with undermined edges. At its base the metacarpal bone of the thumb was exposed and had undergone necrosis. The skin of the hand and fingers was thickened, firm, and wrinkled. The hypertrophy appeared to be due in great part to increase of the subcutaneous tissue.

Microscopically the skin of the hypertrophied fingers showed the following conditions: the cuticle was much thickened, dry and scaly; the rete mucosum appeared condensed and not thicker than usual; the papillæ of the corium were large and prominent; the corium and subcutaneous tissue were immensely thickened, and consisted of interlacing narrow fasciculi of dense fibres. A coloured fluid injected into this tissue passed freely into the superficial lymphatics, which were distinctly dilated and unusually numerous. The blood vessels, which had been injected, were scanty. In many places the epidermis was separated from the corium, large spaces being formed (Plate XXII, fig. 5) which in some instances contained injection.

Dr. Sangster[1] has described and figured similar appearances in ichthyosis of the tongue. I am in doubt whether to regard them as artificial and due to the contraction of the tissues in hardening, or as dilated lymphatic spaces. The extent of the separation rather favours the former view.

The condition of the skin near the ulcer on the hand was in many respects peculiar; the surface was covered with long, narrow papillæ, formed by papillary projections of the corium, covered with a thick layer of epithelium. Between the papillæ the epithelium dipped downwards into the corium, and in one or two places something like an infiltration of the corium with small epithelial cells was observed. At the edge of the ulcer the ingrowth of epithelium became more extensive, and slight traces of it were observed at the base; but nowhere was the ingrowth or infiltration of epithelium sufficiently extensive to indicate that it was cancerous.

The tissue of the corium at this part was less dense and fibrous, thickly infiltrated with young connective tissue cells, and

[1] 'Trans. Path. Soc.,' vol. xxxiii, 1882.

contained clumps of round, lymphoid cells; these were also observed in the corium of other parts of the hand and in that of the hypertrophied foot.

The blood-vessels were exceedingly scanty.

The changes observed in the skin may indicate that the ulceration was set on foot by a hypertrophic ingrowth of the epithelium, not of a cancerous nature, although it might have become so. Hypertrophied limbs appear to be prone to such a form of ulceration, for Dr. Goodhart[1] has described a precisely similar condition of the skin at the margin of an ulcer upon a hypertrophied foot in the museum of the Royal College of Surgeons (No. 12).

Remarks.—The dilatation of the lymphatics in the second case cannot, I think, be considered as a cause of the hypertrophy, for the condition is not commonly associated with similar overgrowths. It would be superfluous for me to make any observations on previously recorded cases of congenital hypertrophy of, or giant, limbs, for these, to the number of forty-six, have been collected and classified by Dr. Richard Wittelshöfer.[2]

The instances just related present some peculiarities worthy of notice.

Dr. Wittelshöfer observes, that an enlargement of the part was always noticed at birth, but that rapid growth did not in many cases begin until later in life. This is true of the left foot in the first case, in which rapid growth was not observed until the age of 23 or 24; and of the hand in the second case, which enlarged rapidly at 37; and both limbs were disproportionately large at birth.

The right foot of the first patient, however, exhibited an almost unique peculiarity, in that it showed no sign of abnormal growth until the age of 24.

A case of immense hypertrophy of the breasts—one of which is in the Royal College of Surgeons' Museum, No. 4739—offers a parallel instance to this. No unusual enlargement of the breasts took place until puberty.

[1] See 'MS. Note Book,' vol. i, p. 413. Dr. Goodhart distinctly states that the ulceration was not epitheliomatous, but it is inadvertently described as such in the 'Catalogue,' vol. i, No. 12.

[2] Langenbeck's 'Archives,' Bd. 24, S. 57, 1879. 'Ueber angeboren Riesenwuchs der oberen und unteren Extremitaten.'

The latency of the tendency to abnormal growth observed in most of these cases may be compared to the latency of some tumours of congenital origin, as the dermoid cysts. But the rare instances in which no congenital enlargement of the part existed may be placed more nearly on a par with some fibrous and other tumours of later life.

The causal relation between the hypertrophies under consideration and tumour formations appears to be not a distant one. Cases have been recorded in which fatty tumours had formed on various parts of the bodies of patients the subjects of a congenitally hypertrophied limb.

The first case is a remarkable example of a tendency to tumour formation co-existing with a hypertrophied limb, for there were fibrous tumours of the sclerotic and lower jaw, osseous over-growths of the patella and some bones of the foot, and hypertrophy of the skin of the sole, not to mention a unilateral enlargement of the head and face, all these abnormalities being on the left side. It would therefore appear that the forces correlating the growth of some parts of the left side of the head and left lower limb were impaired; or that the tissues themselves possessed an abnormal constitution.

And while writing on this subject I may mention that the causes giving rise to congenital malformations often act more or less widely, both as regards the parts and structures affected, and they may produce excess of growth at one part with defect or imperfection in another. Thus we may have the condition of the skeleton known as fœtal rickets, in which the bones are enlarged, combined with numerous supernumerary digits on the hands and feet, and with cleft palate and hare-lip;[1] or a supra-scapular bone is associated with malformation of the spine and deficiency of the ribs on the same side;[2] or, again, an abnormal constitution of the bones of a single limb leading to curvature is associated with the formation of exostosis and sarcoma from the bones and enchondroma from the digits, together with numerous nævoid growths from the veins.[3]

Deviations from normal growth are sometimes shown in the

[1] St. Bartholomew's Hospital Museum, Subsection A Q.

[2] Royal College of Surgeon's Museum, No. 264 A, Teratological Section, and 'Med.-Chir. Trans.,' vol. 63, p. 257.

[3] Ibid., No. 410 A.

formation of tumours of different characters in almost every tissue of the body. I made a *post-mortem* on a middle-aged woman who had an epitheliomatous epulis, symmetrical adenomata in both breasts, fibro-myomata of the uterus, and a molluscum fibrosum of the thigh. *April 17th*, 1883.

---

5. *Cysts containing clear fluid probably dilated lymphatic spaces.*

By Arthur E. Barker.

The following are notes on the occurrence of cysts containing clear fluid in the track of the larger lymphatic vessels which I desire to lay before the Society for its consideration, on account of the interest which similar cysts of undoubted lymphatic nature in other situations are attracting at the present time; and although I am unable to demonstrate to my entire satisfaction that the cavities in the present case are positively dilated lymph spaces or vessels, I cannot imagine any other explanation of their nature. But, however this may be, the facts of the case are of interest and may draw the attention of others to such conditions in instances where their exact nature may be more capable of actual demonstration. The series of spaces are of the more interest as they occurred on the same side of the body as an immense nævoid growth involving almost the entire right lower extremity.

The case was that of a child aged two years, who was admitted into University College Hospital, on account of a great enlargement of the right lower extremity, diagnosed by Mr. Marshall, under whose care the child was, to be a nævoid lipoma. As the condition was extending it was determined to remove the limb, and amputation was accordingly performed at the hip joint in the usual manner on January 16th, 1883. Although but little blood was lost at the operation the child died a few hours later apparently of shock. An autopsy was made twenty-two hours later, before rigor mortis had passed off. For the sake of brevity I need only say that beyond extreme bloodlessness nothing abnormal was

found in any of the abdominal or thoracic contents beyond the cysts now to be described. The hip amputation wound was as though fresh made and was free of blood or pus.

On turning up the intestinal coils *en masse* towards the left side I was struck with the appearance of a small cyst evidently thin-walled, which lay on the right side of the brim of the true pelvis in contact with the wall of the bladder and only covered by the peritoneum. It was about the size of a small walnut with a somewhat irregular surface, the walls being evidently thinner at some spots than at others, and through these spots the pale straw colour of the thin serous contents could be easily seen. The sac was not tense but soft, still it could be rendered tense by pressure on the parts around. Another cyst of the same character but many times as large lay immediately beneath the peritoneum at the lower end of the right kidney. Its contents seemed to be stained slightly with a little blood, but otherwise to be of the same nature as those in the first sac described. In examining this collection more closely its wall was torn, and fluid to the extent of about an ounce escaped. The sac was now found to be somewhat loculated with a smooth almost serous lining and extremely thin walls. Its upper third lay upon the lower end of the kidney but was easily separated from it. The whole was only bounded in front by the peritoneum. On examining the scrotal tissues on the same side, I found another perfectly similar cyst with like contents. This was very irregular in shape and ran from near the right side of the root of the penis downwards, and to the left. It was about the size of the last joint of the ring finger and was markedly loculated, being also constricted at one or two points. On being turned inside out it was found to have a similar smooth endothelial lining and to be marked with bands and ridges on its walls. All three cysts lay in a line on the left side of the body, and almost at once suggested dilated lymphatic spaces, lying as they did over the track of several of the larger absorbent chains of the body. An attempt, however, to inject the two upper cysts from the lymphatics of the testicle by the usual method with a fine needle failed, although the blue fluid could be seen to run up the spermatic lymph canals in the most satisfactory manner and along the walls of the upper sac, but none of the fluid actually entered its cavity. Another attempt was then made to inject them from the lymphatics of the walls of the bladder, but with the same negative

result, as also from the glands of the groin. Here, however, in the neighbourhood of the large amputation wound the injection fluid ran out on the cut surface, and the failure is not to be wondered at. But though none of these sacs could be injected from the absorbent system below, I cannot help thinking that they consisted of nothing less than dilated lymph spaces such as have been found elsewhere, as for instance in the neck. Their whole appearance suggested this in the most forcible way. And it is interesting to note that the only traces of such cysts in the body (for I looked carefully in the abdomen and thorax) should have been found on the same side as that of the nævoid change in the lower limb, and lying in the direction of the larger lymphatics. But for the large hip amputation wound it would probably have been possible to inject the latter, in which case I feel sure a closer connection would have been found between them and the cysts than was observed in this case. But the irregular loculated shape, thin, ill-defined walls, endothelial-like lining and lymphoid contents of these cysts left very little doubt in my own mind as to their nature.

March 20th, 1883.

---

6. *Tænia elliptica.* (*Card specimen.*)

Exhibited by F. Charlewood Turner, M.D.

An imperfect specimen, having no head. It is much knotted; apparently about 4½ inches long. At the anterior extremity is a delicate chain of very small segments of square shape. The segments generally are flattened and of an elongated form; they have a finely granular, translucent appearance, and about the middle of each segment are two opaque dots of yellowish tinge, one on each side of the median line. These bodies cause the smaller segments to bulge at this part. They are the ovaries, and their appearance is a characteristic feature of the species. All the segments are small; the more anterior segments measure about 1¼ lines in length by ⅛ a line in breadth; they are much narrower at their anterior extremities. The segments at the posterior part of the specimen are wider in proportion to their length; they are thicker and less translucent. The ovaries are less conspicuous; they measure on an average about 2½ lines in length by ¼ line in width.

At the back of the preparation are two detached segments, the larger of which is about 3½ lines in length by 1 line in width.

This specimen was brought to the out-patient room at the North-Eastern Hospital for Children with a child, by whom it was said to have been passed. *December 19th*, 1882.

7. *Ascaris mystax* v. *Alata.* (*Card specimen.*)

Exhibited by F. Charlewood Turner, M.D.

This specimen was found by the nurse in a motion passed by a Lascar seaman, who was admitted into the London Hospital from on board a Peninsular and Oriental Mail steamer, with acute nephritis, for which he was confined to bed.

The specimen is shrivelled by the action of spirit, but shows the characteristic lipped or winged shape of the head. It is about 2 inches in length.

Dr. Cobbold kindly examined this specimen subsequently to its being exhibited to the Society, and pronounced it to be a female ascaris. He mentioned that there have been five previous recorded instances of this parasite having been met with in the human subject.

XII. DISEASES, ETC., OF THE LOWER ANIMALS.

1. *The pathology of canine chorea.*

By W. B. Hadden, M.D.

The disease known as chorea in the dog is characterised by the occurrence of rapid contractions of individual muscles or groups of muscles. The muscular twitchings, indeed, resemble the contractions caused by the interrupted current.

In canine chorea the same spasm occurs over and over again and at fairly regular intervals; whereas in human chorea there is an endless variety of purposeless spasms, which have little or no tendency to regular sequence. It seems to me that the movements of canine chorea have almost their counterpart in those spasmodic twitchings sometimes observed in man, and which are termed choreiform. Such, for example, is spasmodic torticollis.

I must add, lastly, that chorea in the dog is usually a sequela of distemper, also that loss of sensation and impairment of muscular power are sometimes observed. Its termination is generally fatal.

The microscopical specimens I bring before the Society were taken from a dog, the subject of this disease. I am not able, however, to give the clinical details of the case. I also made a partial examination of the spinal cord in another case, but failed to detect any abnormal changes.

As a matter of fact there is reason to think that the lesions which I am about to describe are not constant.

A valuable paper on the subject was contributed by Dr. Gowers and Mr. Sankey to the 'Medico-Chirurgical Transactions,' vol. lx.

As these two observers have remarked, the most noticeable alterations are to be found in the existence of groups and tracts of lymphoid cells, scattered irregularly throughout the grey and white matter of the neuro-axis.

In my sections, the groups are almost limited to the grey matter, the white matter merely presenting leucocytal excess here and there.

The changes are most marked in the lumbar and lower dorsal regions of the cord; they are apparently absent in the cervical cord and medulla oblongata. The groups of small cells to which I have alluded are really emigrant leucocytes. Indeed, in the affected area a distended capillary can nearly always be made out. The different stages of capillary distension, the filling of the perivascular sheath with leucocytes, and the collection of these leucocytes into groups can be seen in my sections.

In some spots the cells had become lengthened out. Such an appearance, as Dr. Gowers and Mr. Sankey have remarked, suggests that a condition of insular sclerosis might possibly supervene in long-standing cases of this disease. I must mention that these groups of leucocytes are disposed quite at random, there being no tendency to symmetrical arrangement. In one section the changes are most marked, whilst in another taken from the same part of the cord, both grey and white matter are apparently quite healthy.

The motor cells in the anterior cornua are in some places swollen and granular. Their outlines are often indistinct, and the nucleolus occasionally is seen to be in process of division.

In one spot an accumulation of leucocytes around a multipolar cell has caused some atrophy of the cell. The central canal is not distended, but appears to me quite normal. Dr. Gowers and Mr. Sankey have called attention to the existence of vacuoles around the large nerve-cells, to a curious spongy appearance of the matrix of the grey matter, and to an increase in the nuclei of the neuroglia. I have not been able to detect any of these lesions in my sections.

The question arises are these changes primary or secondary?

It is difficult to answer with certainty, but I am inclined to agree with Dr. Gowers and Mr. Sankey that they are probably secondary.

Dr. Gowers tells me he examined two cases without finding any lesion. It would therefore appear that the above-mentioned changes are not constant.

Again, the appearances suggestive of localised vascular disturbance, and the granular condition of some of the motor cells, might be looked upon as being consecutive to simple over action of the nerve-elements. *November* 21*st*, 1882.

2. *Rickets in a Baboon.*

By J. B. Sutton.

This specimen is the skeleton of a young baboon, from Africa, aged 6 months, which died in the Zoological Gardens a few months ago.

History.—The animal was two months' old when introduced into the gardens, and was abundantly supplied with fruit, nuts, and soaked bread in lieu of its natural aliment. Four months after admission the baboon died. The viscera had unfortunately been removed before I saw the body, the skeleton alone coming under observation.

Because the tissues of ossification, viz. epiphysial cartilage, and periosteum, are the seats of disease, I have ventured to describe the affection as rickets.

General condition.—All the bones, with the exception of those of the hands and feet, were covered with thick succulent periosteum, the osseous tissue being soft and easily compressible.

Vertebræ and discs.—The intervertebral discs are thicker than usual, and the nucleus pulposus large and almost diffluent.

Ribs.—The costal arches present the usual moniliform appearance, the beads confined to the pleural surface and being expansions of the rib-shafts, whilst the costal cartilages are normal.

Sternebræ.—The sternebræ are thick and spongy, cavernous spaces existing in their interior partially filled with semi-fluid material.

Pectoral Girdle.—

(A) *Clavicle.*—Scarcely any trace of curve perceptible, the shaft much thickened, the bone shorter than usual.

(B) *Scapula.*—Generally thickened.

(C) *Humerus;* (D) *Radius;* (E) *Ulna.*—Epiphysial zones larger than usual and occupied by bluish translucent spongioid tissue. Changes are most apparent in the lower end of ulna and radius, so far as the upper limb is concerned.

Pelvic Girdle.—

(A) Ossa innominata thickened.

(B) *Femur.*—Lower epiphysial zone measures twelve millimetres instead of one, the growing area being very irregular.

(c) *Tibia.* — Similar changes at the epiphyses, shaft slightly bowed forward. The overhanging internal tuberosity clearly indicates that genu valgum would have resulted had the animal survived.

(d) *Fibula.*—A similar condition.

Skull.—The calvaria is enormously thickened, measuring six millimetres from inner to outer table. The inner table is hard and smooth. Outer table soft and irregular, and sucks up water after the manner of a sponge or piece of porous rock.

Bones of the face share in the general condition.

Lower jaw greatly thickened, yet with all this disease the teeth are normal.

Skull of a baboon, age uncertain.

Specimen No. 2.—Immediately on discovery of the first specimen inquiries were made as to the existence of any other examples of the disease, which resulted in finding this skull, saved as a curiosity on account of the extraordinary thickness of its bones.

It evidently belongs to a young baboon, as its basilar suture is yet conspicuous and its canine not yet in position.

It presents in a greater degree, also in a more advanced stage, the condition of the first cranium. The frontal bone is no less than sixteen millimetres in thickness.

Microscopic examination shows the bone to be divided by irregular trabeculæ into large spaces filled with granular material. The trabeculæ themselves are dotted over with small lacunæ.

Microscopic examination of the first specimen, by means of sections passing through the epiphysial zones of the humerus, exhibit three distinct layers—

1st. The layer of normal hyaline cartilage.

2nd. The layers of cells, arranged in longitudinal columns, three times wider than usual.

3rd. A layer of irregular calcareous trabeculæ here and there, enclosing little islets of normal hyaline cartilage.

November 21st, 1882.

3. *Rickets in a baboon (Cynocephalus porcarius), West Africa.*

By J. Bland Sutton.

[With Plate XX, fig. 3.]

At the last meeting of this Society, Dr. Goodhart exhibited certain portions of the skeleton of a young child which in the main corresponded to the abnormal conditions met with in rickets; but considering the unusual softness associated with hypertrophy of the bones and the thickness of the skull vault, syphilis was supposed to have played a part in the production of the lesions.

Six weeks ago I exhibited at this Society the skeleton of a baboon in which every long bone, save those of the hands and feet, were in a precisely similar condition as in the child described by Dr. Goodhart. Everyone who saw the baboon was satisfied that it was an unmistakable case of rickets. To-night I have here another case, but in a much older subject.

This monkey was a West African baboon, aged at least 1 year and 6 months.

History.—Its last menstrual period was unusually prolonged; the keeper informed me that it had been losing blood profusely for some days previous to its death.

Liver.—8½ oz. (large for size and age of the creature), pale in colour, and lardaceous, affording the reaction with iodine readily.

Uterus.—Large and bulky.

Skeleton.—All the bones are extremely vascular. This is not apparent on a cursory examination, for the bones present a deceptive pallor, but the slightest pressure causes blood to ooze from every pore visible on the cut surface of any of the bones; periosteum thick and succulent.

The thorax presents the usual pigeon breast, with large beads on the pleural surface of the rib shafts; costal cartilages normal; sternebræ thickened, clavicles normal; ossification is fairly well advanced in the epiphyses, but the line of epiphysial growth is large and irregular.

The curvature of all the bones is much increased, particularly the curve of the right femur; indeed, one fails to see how this bone resisted fracture, it is so bent. The right elbow presents a peculiar deformity. Instead of radius and ulna lying side by side, the head of the radius is articulating with the ulna by means of a sigmoid

cavity on the *inner* side; the upper end of the radius, as far as the bicipital tuberosity, is resting on the coronoid process of the ulna. From this arrangement it comes to pass that the cup-shaped extremity of the radius and the greater sigmoid cavity of the ulna articulate on an enlarged trochlear surface of the humerus.

A very small bone, very like one of the carpal series, is attached to the humerus by strong fibrous tissue; its free surface is covered with cartilage, and plays on a narrow articular facet on the outer side of the olecranon. This ossicle probably represents the detached outer condyle of the humerus, the lower end of which is curiously modified to adapt it to the altered relations of the bones of the forearm. It seems propable that there had been dislocation of

WOODCUT 12.

Lower extremity of the femur of a baboon, showing the enlarged and irregular epiphysial line, spongioid tissue, and cartilage islets *a*, *a*, *a*.

the radius with separation of the epiphysis from the external condyle, and that the bones have adapted themselves to their altered relations.

The skull is the seat of marked change; the bones of the vault are enormously thickened, being eight millimetres through (the normal

thickness being four mm., as this natural skull shows); there is an outer table of fairly firm bone, and an inner table of dense smooth bone, but the intervening space is filled with very porous material. Below the level of the occipital curved line the bone is very thin and transparent, resembling somewhat craniotabes. The sutures of the vault are complete, but the suture between the mastoid portion of the temporal and occipital bones is imperfect.

The condition of the teeth is very interesting, for I hope to put forward a probable explanation of the delay in dentition which formed so marked a feature of this curious malady.

Some monkeys cut their milk teeth very soon after birth, and in the course of a few months the temporary teeth are in their places, so that a monkey affected with rickets seems to possess a goodly array of teeth, in spite of the disease.

In the present case, I dissected away the outer portion of the lower jaw to examine the embryo teeth of the *permanent* set, and a very curious condition existed. Normally each tooth germ is enclosed in a delicate connective-tissue sac, known as the dental follicle, which not only surrounds the developing tooth, but is continuous with the pulp chamber through the widely open and imperfect fang; but in these rickety maxillæ these sacs are of great thickness, particularly those lying immediately beneath the gum; instead of the thin, delicate, transparent, and vascular membrane one is accustomed to see, there is a fibrous envelope as thick as the skin on the finger. This is not surprising, seeing that it is continuous with the periosteum of the jaw. This may afford explanation why teeth are late in appearing above the alveolar margins in rickets.

There is one other point of interest which attentive examination of these skeletons reveals. It is usually stated that in rickets the epiphysial zone is greatly exaggerated and occupied by spongioid tissue. This is not all.

If a normal centre of ossification be carefully traced, it will be found to extend from a definite spot, known as the ossific centre, the border of advancing ossification well marked, and the cartilage as clearly and regularly disappearing. Such an epiphysis as this merits the name of *discrete epiphysis*. In rickets, the osseous trabeculæ shoot hither and thither in wildest confusion until the cartilaginous area destined to become bone is nothing more than a tangled network, consisting of imperfectly ossified trabeculæ enclosing in a network of wide meshes *islets* of softened cartilage,

many of them so large as to be easily seen by unassisted vision (Fig. 12—*a*, *a*, *a*.)

Such a condition should be termed a *diffuse epiphysis*, for lime salts appear to be deposited in disorder in a softened cartilaginous matrix; indeed, the rachitic epiphysis may not inaptly be compared to a living sponge where the osseous trabeculæ represent the calcareous or siliceous spicules, and the softened cartilage the parenchyma of this invertebrate. *January 2nd*, 1883.

---

4. *Bone disease in animals.*

By J. B. Sutton.

1. *An Indian monitor.*

The skeleton of a lizard recently living in the Zoological Gardens.

Food.—Eggs, meat, fruit, vegetables.

The features of interest may be arranged under three headings:

1. The condition of the long bones.
2. The softness of the skull.
3. The presence of cartilage tumours.

The rib-arches at the anterior extremity of the thorax have bulgings at the junction of rib and cartilage, not distinct beadings; also enlargement of the rib shafts near the vertebral column.

1. *The long bones.*—In Lacertilia the long bones do not as in the higher mammalia develop from a diaphysis, with one or more epiphyses, separate for a limited period, then fusing together; but the extremities of the limb bones are capped with a layer of articular cartilage. Between the bone shaft and this terminal cartilage a thin layer of ossifying cartilage is retained, where growth continues as long as life endures.

In this specimen the ossifying layer is clearly seen, but the bone for half an inch above is extremely soft and spongy, so that the long bones may be bent at the extremities as though they had been decalcified. The centre of the diaphysis consists of thin, compact tissue, easily broken; the medullary cavity large, and filled with diffluent medulla.

Examined microscopically, this softened tissue consists of thin trabeculæ of osseous tissue, enclosing large spaces filled with round

cells of an uniform size; bands of fibrous tissue can be readily traced into the substance of the softened mass, being most marked in the neighbourhood of the periosteum. I fail to detect in any part of the skeleton the *spongioid* tissue met with in rickets.

2. The softness of the bones of the face and skull is extreme; the lower jaw could be wound round the finger.

The only firm bone tissue in the creature is that of the central portion of the shafts of the long bones, and the vertebral centra.

3. Not the least interesting are the numerous tumours found in various parts. The two largest occur in the vertebræ, and appear to be expansions of the body of the fifth and seventh cervical vertebræ. In each scapula there is a large tumour surrounding the glenoid cavity.

The right humerus has two immediately above the condyles (see fig. 13); the left possesses one; the hyoid has four, growing from its cornua; and there are two on the metacarpal bones.

WOODCUT 13.

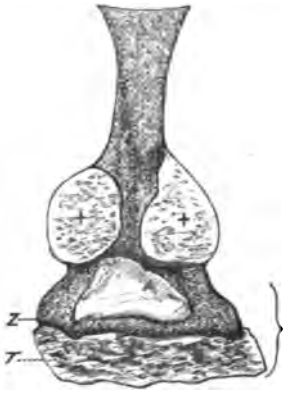

Section of the lower end of the humerus of a lizard, with two cartilage tumours springing from the growing line.

Examined microscopically, these tumours possess a bony nucleus with an external layer of cartilage.

I believe this to be a case of osteomalacia.

Rhea Darwinii. South American ostrich.

This skeleton belonged to a young rhea, recently living in the Zoological Gardens.

The thorax is greatly distorted, owing to extreme softness of the ribs, which can easily be bent in any desired direction. All the

bones possess one property in common. *They are osseous sponges, containing in trabecular spaces oily fluid, which exudes on the least pressure.*

The bones of the skull, usually very hard, are in this bird so soft and pliable as to admit of their bending like a piece of thin leather.

The medullary cavities of the long bones extend much farther into the cancellous tissue of the extremities than is usual, and contain an oily fluid, instead of the ordinary medulla. The trabeculæ of the cancellous tissue are so soft that they may be broken away by the finger with the greatest ease.

Perhaps one of the most interesting features of the case is the existence on the metatarsal bone of each limb of a cartilage tumour as large as a walnut.

In these birds the only epiphyses present are: One at the cnemial process; another at the lower end of the tibia, representing the astragalus of creatures possessing a tarsus; and a third, at the proximal end of the confluent metatarsus. This epiphysis probably represents the distal row of tarsal bones; a zone of epiphysial cartilage exists in this situation in all birds (Fig. 14).

WOODCUT 14.



Metatarsal bone of rhea, with a cartilage tumour springing from the epiphysial line. Half nat. size.

It is just at this point that the tumours occur, one on each leg: the growths, consisting of hyaline cartilage intermixed with fibrous tissue, seem to spring from the cartilage and expand the osseous tissue, more particularly on the outer side of the bone.

The metatarsal bone of the left side was fractured a few days before the bird died; its compact tissue was very thin.

Taking into consideration the extreme softness, porous condition, and greasy state of the bones, this disease resembles osteomalacia.

Macaque monkey, aged at least 3 years.

A puny, deformed, and miserable-looking monkey, which had

been an inhabitant of the Zoological Gardens for the past two years. The keeper informed me that it had been paralysed for some time. *Post-mortem* examination revealed no nerve lesions.

Viscera.—A milk-white patch on the anterior surface of the ventricles of the heart. Induration and enlargement of the spleen, and atelectasis of lung in consequence of the yielding of the thoracic parietes, were the most important lesions found.

Skeleton.—All the bones save those of the skull were extremely vascular, and the periosteum thick. There is extreme pigeon-breast, but no beading of the ribs. The scapulæ are extremely dwarfed, and the vertebral border is doubled on to the venter by the action of the serratus magnus muscle. The pelvic bones are dwarfed, softened, and the crests of the ilia doubled on the ventral surface of the innominate bones by the action of the abdominal muscles. The cavity of the pelvis is extremely encroached upon, and the whole structure presents the rostrum-like projections met with in mollities ossium.

The spinal column presents a strongly marked kyphotic curve, due to extreme softening of its component vertebræ.

The long bones have the epiphyses quite separate, the discs of cartilage being four times their natural thickness. The diaphyses may be likened to very thin nutshells containing oil.

The cancellous tissue of the extremities is soft and spongy, and easily cut with a knife; indeed, I was able to cut microscopic sections with a razor, minus any softening process. The softened ends form large bulgings, which, when squeezed, allow an oily fluid to exude. The external layers in these parts resemble callus more than bone. On some of the long bones large tracts of this curious material exist, deposited by the periosteum in the form of osteophytes.

The left femur presents a remarkable condition. Besides its extreme thinness and softness of extremities the medullary cavity extends throughout the shaft, even to the lower epiphysis, as shown in fig. 15.

Microscopically.—The softened bones consist of large, irregular spaces filled with round cells; here and there *cartilage islets* may be found. The margins of the epiphysial cartilages have undergone great proliferation, and its cells are very numerous, but there is absence of *spongioid* tissue so characteristic of rickets.

The skull presents slight heaping of bone at the margins of the

sutures; the vault is splashed with osteophytic bone. Possibly this is a case of osteomalacia.

WOODCUT 15.

Represents femur split longitudinally, to show the somewhat widened epiphysial cartilage (E), and the extension of the medullary cavity to this cartilage.

The bones of the lower limb have been injected to show the vascularity of the tissue.

Cercopithecus Diana.

This monkey lived in the Zoological Gardens about three years. It presented no deformity during life.

Post-mortem. — The only visceral lesion worthy of note was extreme atelectasis with patches of emphysema at the anterior borders of the lungs. It is difficult to understand how the creature managed to live with such a narrow thorax.

The thorax is narrow and compressed laterally; the rib-shafts are bulged at the cartilage junctions, but the distinct beading seen in rickets is absent; bulgings occur also in various situations remote from the extremities of the ribs.

The flat bones present similar characters to the preceding specimen, and I would particularly note the doubling of the vertebral borders of the scapulæ and the iliac crests.

The long bones have their epiphyses quite distinct; the extremities in the immediate neighbourhood of the epiphysial lines are curved to an extreme degree; certain of the bones (ulna and radius) have bulgings in the centre of the shaft as though fracture had occurred, and provisional callus had been thrown out; but no fracture can be detected even by the microscope. As in monkey No. 1 (the macaque), the shafts are like thin nutshells filled with oil.

Microscopically.—Characters as in preceding specimen. Absence of spongioid tissue is a marked feature in these cases.

Skull.—The skull presents marked craniotabes; the occipital bone below the protuberance is in some places perforated; the

sutures of the base still retain their cartilage; the roofs of the orbits present tabetic patches; the sutures of the vault have raised margins; and the parietal, temporal, and frontal bone have osteophytic patches on their exterior.

Monkey, No. 3. *Cercopithecus cynosurus.*

This monkey presented no external appearance of disease: the features were normal, and nothing abnormal could be felt.

On reflecting the skull cap, the only noticeable feature was the dark purple colour of the bone.

The skeleton was thoroughly examined, every long bone being split longitudinally in order to expose the epiphyses; but all were normal.

The skull, including the bones of the face, were increased to four, and in some cases to five or six times their natural thickness.

The surface of the bone is pitted with holes for nutrient vessels, the pericranium and dura mater are very adherent, the bone tissue porous; the inner surface of the cranium is smooth, except on the parietal bones, where a patch of stellate or reticulate bony deposit exists; the grooves for the meningeal arteries are deepened.

The bones bounding the nasal fossæ are thick, and encroach on the cavities of the orbits, meatuses, and antra.

The spaces in the bone yield a reddish fluid when pressed.

Macaque monkey.

This animal presented no appearance of disease externally.

It is a young animal, as may be seen by the yet separate epiphyses.[1]

The radii and ulnæ are singularly curved, but the curvatures are not due to softness of bone or muscular action, for the compact tissue of their shafts is increased seven or eight times above the normal, the greatest thickness being on the concave side of the curve, and is hard, white, and dense, like ivory; the medullary cavity is encroached upon, and in the centre of the shaft is almost obliterated. The exterior of the bone has some spongy deposit of reticulate pattern, resembling the condition described as osteitis deformans. It may be suggested that it is due to rickets recovered from, but there is no evidence of that affection in the skeleton, although every epiphysis has been carefully examined.

[1] The spine is the seat of lateral curvature in the thoracic region.

Remarks.—Careful consideration of these specimens, and many other skeletons coming under my notice in conducting dissections at the Zoological Gardens, induces me to offer a few remarks upon certain diseases of bones which seem to belong to one group, from the fact that they have one cause in common—*chronic inflammation.*

The diseases referred to are: rachitis, osteomalacia, craniotabes, osteoporosis, and osteitis deformans.

In the science of natural history it has happened again and again that naturalists have erected new species for creatures, which more accurate and careful investigations have shown to be merely varieties of one species living in different localities; so in this group of bone affections. All are manifestations of chronic inflammation, the variety in effect being due to difference in age, and the changes to which the bone is subject in consequence, the acceleration or retardation of any normal process in bone growth having its pathological equivalent.

The processes which operate in the formation and growth of bone after birth consist of three, viz.—1. Epiphysial increase. 2. Periosteal deposition. 3. Osteoporosis or absorption, this last keeping in check the previous two.

Epiphysial growth is most luxuriant from birth up to the third year, during which period the most important secondary centres make their appearance. Perturbation at this age leads to rickets.

Later, when the periosteum has all the work to perform, and absorption keeps it in check, then, if periosteal growth be delayed, osteoporosis continuing unchecked, rarefaction occurs. This is seen in full perfection in bones which have become rarefied by ulcers of the integuments covering them, especially cases of epithelioma of the skin covering the tibia, also throughout the skeleton in that singular malady—osteomalacia. If the periosteum forms bone too fast or deposits it irregularly, osteophytes form, or if it be increased, with osteoporosis normal, then osteitis deformans results.

The varying relation of the processes in health and disease are shown in the following table:

Tabular view of Normal and Abnormal Processes in Bone Development.

NORMAL.		ABNORMAL.
Periosteal deposit	1st, Irregular	Osteophytes.
	2nd, Excess	Osteitis deformans.
	3rd, Minus	Osteoporosis.
Osteoporosis	Excess	Osteomalacia.
Epiphysial formation	Excess	Rachitis.

The following table is arranged to show the diseases which seem to be represented by the specimens (see Table 2).

In distinguishing between rickets and osteomalacia in young animals I adopt the following rule:

Rickets is recognised by the presence of much *spongioid* tissue at the epiphysial lines, associated with diffuse epiphyses consequent on the formation of "cartilage islets."

Long bones are curved throughout their length, the compact tissue thicker than usual and soft; trabecular spaces of the cancellous tissue filled with cells.

1. In osteomalacia occurring in young animals very little spongioid tissue exists, but the epiphysial cartilage is thicker than usual, the cells at the growing margins having undergone more proliferation than usual.

2. "Islets" may occur. Trabecular spaces contain an oily fluid.

3. Compact tissue of shaft very thin; curves limited to the extremities of the bone, where the cancellous tissue is softened. Medullary cavity larger than normal, and filled with diffluent medulla.

TABLE 2.

NAME.	DISEASE.	CAUSE.
Lizard	Osteomalacia Cartilage tumours	Chronic *inflammation.*
Rhea	Tumour (Cart.) Osteomalacia	
Monkey 1st	Osteomalacia	
„ *2nd*	Osteomalacia Craniotabes (no syphilis)	
„ *3rd*	Osteoporosis (skull)	
„ *4th*	Osteitis deformans.	
Baboon	Rachitis	

All search for syphilis up to the present time in monkeys has proved unavailing. *February 20th*, 1883.

5. *Pyæmia in a male python (♂ Python sebæ). West Africa.*

By J. B. Sutton.

In February last a male python, 7 feet long and 9 inches in girth, died in the Zoological Gardens four days after admission.

About the middle of the abdomen and to the right side was a very large swelling, caused by an abscess in the wall of the belly, in the immediate neighbourhood of the gall-bladder. This abscess was lined throughout the greater part of its extent by laminæ of caseous material, arranged layer upon layer, like the fibrin around

Woodcut 16.

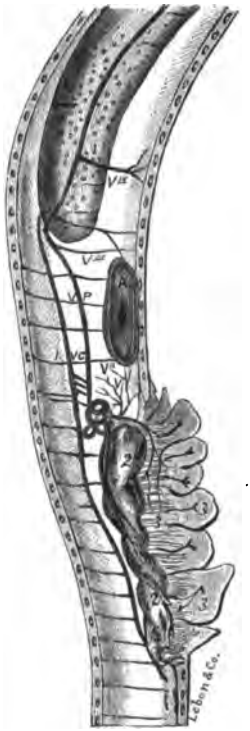

Explanation of diagram to show relation of veins in Python sebæ.

1 The liver. 2. Intestines. 3. Omentum. V. P. Portal vein. I. V. C. Inf. vena cava. V^{I} V^{II} V^{III} V^{IV}. Intercostal veins opening into omental vein and vena portæ respectively. A. Abscess in abdominal wall.

the wall of a sacculated aneurysm. The walls of the abscess cavity, on account of this curious laminated arrangement, were an inch in thickness; the interior contained twenty ounces of extremely fœtid pus.

Viscera.—The pericardium contained five ounces of bloody serum, and the visceral layer of the pericardium was covered with lymph, most abundant over the auricles, where it formed four or five shaggy masses floating in the surrounding effusion, possessing fringes half an inch in length.

I injected the capillary system with fine material, with the view of discovering the source of blood in the pericardial chamber, but failed to detect any rupture of arterioles or veinlets, although the minute vessels covering the surface of the heart became thoroughly injected.

The liver contains numerous abscesses and masses of fibrine, varying in size from a small pea to a nut, equally distributed through the organ. The portal vessels are filled with carmine injection, in order to render the deposits more obvious.

With this condition of viscera I registered the death as pyæmia resulting from the suppurating focus in the abdominal wall; and as it seems exceedingly probable that the extensive deposits in the liver resulted from the peculiar disposition of the portal vein in these reptiles, it may be interesting to refer to it more in detail.

In reptiles, some of the blood returning from the renal-portal system joins veins passing from the intestinal canal, spleen, and omentum or fat body, then passes to the liver, receiving just before its arrival at that viscus certain intercostal veins, in this way establishing a direct communication between systemic and portal veins.[1]

In the python a curious addition to this anastomosis is met with, to explain which I have invoked the aid of a diagram. (See Woodcut.)

The veins of the fat body, instead of opening indiscriminately into the portal vein, form a trunk by themselves, and thus effect the junction as a single vessel; before this happens, however, this omental vein receives several communications from the intercostals in the immediate region of the body whence the main trunk of the portal vein has its systemic tributaries, namely, in that part of the abdominal parietes lying between the liver and gall-bladder.

The abscess was situated exactly in this anastomotic area, where

[1] This anastomosis results from the breaking up of the umbilical vein.

the veins would afford every facility for the ready transport of septic matter into the liver, thus setting up purulent foci in that organ and giving rise to hæmorrhagic pericarditis, and eventually to death. *February 20th*, 1883.

6. *Two hundred abscesses in the liver of a kangaroo.*

By J. B. Sutton.

The specimen was taken from a female kangaroo, which died in the Zoological Gardens a month ago.

The liver surface is everywhere nodular, with small abscesses projecting from the deeper tissues of the liver under the peritoneal covering. Altogether about 200 masses may be counted, varying in size from a cherry to a walnut, some of the larger ones extending deeply into the substance of the organ.

They all possess certain characters in common, their outer wall being formed of dense, yellow, cheesy deposit, the centre consisting of a cavity containing thick pus. Some of them have been examined microscopically, but reveal nothing of interest beyond pus cells. The lymphatic glands in the transverse fissure of the liver are enlarged and caseous.

The immediate cause of the animal's death was hæmorrhage into the cavity of the peritoneum, caused by the rupture of a bridge of liver tissue between an abscess deeply situated and the surface.

I could find nothing to account for this extreme condition. All the other viscera were thoroughly healthy, and every part was carefully dissected. *December 19th*, 1882.

---

7. *A remarkable case of parasites.* (*Card specimen.*)

Exhibited by J. B. Sutton.

The specimen shows the viscera of a small West African carnivore, which died in transmission from Liverpool to London.

The pleural and peritoneal cavities contain an immense number of larvæ, many of which are enclosed in a thin transparent

membrane. Many are situated in the subserous tissue of liver, lung, diaphragm, intestines, testicles, &c. The great omentum contains several hundred. Two hundred and fifty of the larvæ were lost in preparing the specimen. The lungs and liver contain a few invaders encysted in their substance. The kidneys are sacculated. In no part of the body was there the least trace of the parasites in the muscular tissue, voluntary or involuntary.

May 15*th*, 1883.

8. *Retroflexion of the uterus in a baboon.* (*Card specimen.*)

Exhibited by J. B. Sutton.

The specimen was taken from a West African baboon (*Cynocephalus porcarius*), which died in the Zoological Gardens.

I was unable to obtain any history of the animal. The fundus is acutely retroflexed; there is atrophy of the posterior wall of the uterus. A cyst of the size of a pea occupies the outer extremity of one of the ovaries.

It has been stated that one of the disadvantages of the erect position assumed by human beings is the occurrence of flexion of the uterus in the female. The specimen shows that it is not peculiar to the human female.

May 15*th*, 1883.

9. *Two specimens of urinary calculi from animals, composed of carbonate of lime.* (*Card specimen.*)

Exhibited by Samuel G. Shattock.

One of the specimens is from the bladder of an ass. It is of a dull fawn colour, like dried clay, and is highly granular or almost coralline on the surface; its substance is firm, but portions are readily separable from the exterior, which is formed by small spheroidal masses, aggregated into larger branching protuberances, and its sectional surface exhibits the same mode of accretion, being constructed of irregular, branching, foliated parts, arranged radiately with their bases outwardly, and parted in the dried specimen by narrow fissures; no nucleus is recognisable distinct from the body of the calculus. Chemically it consists of carbonate of lime, but with this is a trace of phosphate of magnesia; it contains no uric or oxalic acids.

The second specimen is from the bladder of a dog. The bladder was shown at the Society by Mr. Treves as a specimen of cystitis, and is noticed in the thirty-second volume of the 'Transactions,' p. 311.

The calculus is of a flattened discoid form, 2 inches by 1½ inches in its chief diameters, fawn coloured, lowly granulated on the surface, and on section presents a beautifully arborescent construction. Considerable spaces exist in the dry state between the component parts of the calculus.

The substance of the calculus is entirely soluble without heat in hydrochloric acid, the solution being accompanied throughout by effervescence.

The urine of herbivora is normally alkaline from the presence of carbonates, and the formation of calculi of carbonate of lime is as frequent in such animals as are those of uric acid in man. In the case of the dog I can only assume that the animal had been kept on a vegetable diet, and that its urine had in this way been rendered alkaline, as human urine will be under the like conditions.

December 19*th*, 1882.

XIII. DISCUSSION UPON THE MORBID ANATOMY OF DIABETES.

THE PRESIDENT, in announcing the subject for discussion, observed that the pathological anatomy of diabetes was a subject of which he felt himself to have no certain or exact knowledge; he believed, however, that in this he was not singular. He thought that the discussion ought to be confined to cases of diabetes mellitus, leaving on one side diabetes insipidus, as well as cases of glycosuria in old people, which drag on a chronic course for many years without materially affecting the general health or longevity of such persons.

Dr. WILKS said that he was not prepared to contribute either facts or theories to the discussion, but as he had been asked to open the debate, he would point out several subjects upon which some light might be cast. No doubt it was very probable that all the anatomical lesions commonly found were the consequences of a disease which lay behind all, and which was called diabetes. He remembered the time when Bernard made his original experiments; he had witnessed these experiments in Paris, and the subject then had attracted much attention, and subsequently at Guy's Hospital, in the many *post-mortem* examinations he had made, he had carefully examined the pons and the fourth ventricle, but without, in any case, finding any recognisable pathological condition. Since Dr. Ogle's paper, read ten years ago, in which dilatation of the central canals and vascular changes in the medulla oblongata, and spinal cord were described, the theory that the disease was due to some vaso-motor disturbance, or some disease of the ganglionic nervous system, had found great favour; he hoped that any members who supported this theory would advance substantial facts. His old teacher, Mr. Wilkinson King, had taught that the liver was large and fleshy; and with regard to this, and with regard, also, to the condition of the pancreas and spleen, he looked for further in-

formation. Another interesting pathological question was whether the kidneys were, as a rule, enlarged. Very commonly they were hypertrophied, as was expected, on theoretic grounds, to occur in organs which had to discharge an unaccustomed amount of work. He thought it would be well to note whether anæsthesia and atrophy of the skin had been noticed by any of the members; such changes had been described. With regard to lipæmia, he remembered one case of Dr. Babington's, where the patient was bled, and the blood, on standing, became covered by a layer of fat. Two other points of great importance were—the duration of the disease, and the mode of death. Twenty years ago he would, had he been asked, have attributed death, in the majority of cases, to phthisis; while, in reply to that question, he would, at the present time, answer diabetic coma. Where the cause of death was chronic disease of the lung, what was the nature of this disease? Dr. Addison had taught that the destructive lung disease in diabetes was not ordinary phthisis, not tubercular phthisis, and he had applied the term albuminisation of lung to the condition.

Dr. RALFE.—In the present discussion, I intend to limit my remarks to the consideration of the phenomenon to which the term "acetonæmia" has been applied, with the view of endeavouring to arrive at some conclusion as to how far diabetic coma depends on the development of a toxic agent in the body, or is the consequence of some nervous lesion. In the first place it is important to discriminate between the coma, which is the frequent termination of so many cases of diabetes which have run a long course and which end generally with some lung complication, and the suddenly developed coma ushered in with the peculiar and well recognised symptoms, which seem to occur as an accident than as the natural close of the disease. Although this form of coma is far from being an uncommon termination in characteristic and well-marked cases of diabetes, it is more frequently observed in the irregular and ill-defined forms; indeed, in many instances the onset of this particular form of coma is often the first evidence that the disease is present and the presence of sugar in the urine suspected.

The symptoms attendant on this form of diabetic coma are briefly as follows: It is usually preceded by an increase in the quantity of urine passed, though not necessarily an increase of the sugar. This increase in the flow of urine may last for some days, or it may be present for some hours only. With the onset of definite symptoms,

however, the flow diminishes and the sugar may entirely disappear, so that during the last few hours hardly any urine may find its way to the bladder. The definite symptoms may be thus briefly summarised. In a large proportion of cases the attack commences with sharp epigastric pain, and gastric disturbance, sometimes actual vomiting, which vomit has been observed in some cases to contain blood; in a few cases purging has also been noticed. Almost coincidently the patient is seized with dyspnœa of a peculiarly panting, irregular character; then sets in a condition of restlessness, which often passes into delirium of noisy character. Almost suddenly the restlessness and delirium cease, and the patient falls into deep coma. The temperature at the onset is usually below the normal; the pulse is irregular at first, but on the supervention of coma becomes extremely rapid, weak, and thready. The odour of acetone may be present throughout, but usually diminishes markedly from the onset of the attack. Many of the symptoms enumerated have a close parallelism with those that are attendant on death in acute yellow atrophy and phosphorus poisoning. Thus the sudden and sharp epigastric pain, accompanied with gastric disturbance, often with vomiting, sometimes containing blood; the peculiar dyspnœa, which has been likened to the panting of an animal in which both vagi have been cut; the stage of short noisy delirium, followed almost suddenly by deep coma; the fall in temperature as the nervous symptoms develop; the irregular pulse rising to 120, and then falling below 80 to rise again, and finally becoming intensely rapid as the coma deepens, are all symptoms with which those who have seen cases of acute yellow atrophy, or studied the literature of the subject, are familiar. I shall return to this parallelism when I come to consider the *post-mortem* changes found in persons dying of this form of diabetic coma.

With regard to the circumstances that lead to this condition, it has been held that they depend upon the formation of acetone in the living blood, and that the symptoms are due to poisoning with that substance: hence the term "acetonæmia." Experimental research has, however, I think, made it pretty evident that acetone, as acetone, is not disengaged in a free state in the blood, though there is no doubt that it is found in the urine of diabetic patients; it has also been found in the vomit of patients suffering from chronic dyspepsia attendant on alcoholism. But though acetone may not exist in the free state in the blood, it undoubtedly is con-

tained in some body which readily yields it on decomposition. This body has been generally considered to be *ethyl-diacetate*. This body on distillation yields one molecule of acetone and one molecule of alcohol. Lately, however, the view has gained ground that the antecedent of acetone in the blood is not *ethyl-diacetate*, but *aceto-acetic acid*. The reason for this assumption is—ethyl-diacetate yields on distillation one molecule of acetone and one molecule of alcohol, therefore equal parts of these bodies should be obtained; indeed, as acetone is the more volatile body of the two, the alcohol should be in excess. Now, in several distillations of diabetic urine, it has been shown that the acetone obtained has been considerably in excess of the alcohol; and to explain this, the antecedent body is now supposed to be *aceto-acetic acid*. A clinical fact is in support of this chemical view—the very high degree of acidity of diabetic urine; and we know that from these highly acid urines acetone can be frequently obtained by distillation. Now, aceto-acetic acid is, as we are well aware, a powerful acid, whereas ethyl-diacetate is a neutral body.

It is of importance that this question should be decided, for if it can be shown positively that aceto-acetic acid is the antecedent of acetone in the blood, then many of the phenomena attendant on diabetic coma can be satisfactorily explained. That aceto-acetic acid should not be formed there is no reasonable ground for doubting—since given glucose in the blood, aceto-acetic acid is only one of the products of alcoholic fermentation that may be generated—the question is whether it is the product concerned in bringing about the phenomena under consideration. If the formation of aceto-acetic acid be eventually shown to take place to any extent in the blood of diabetic patients, then we have an explanation—1st, *of the highly acid condition of urine that is associated with diabetes*; 2nd, *of the lactescent condition of the blood*; 3rd, *it would explain the intense fatty degeneration so noticeable in these cases of acute diabetic coma*, since it is well known that the injection of acids into the blood tends to the increase of fatty matter in the blood, and of fatty infiltration in the tissues and organs.

In connection with this, I would now refer again to the parallelism between acetonæmia and acute yellow atrophy and phosphorus poisoning to which I just alluded; and I would draw attention to the statement made by Professor Gamgee, in his work on 'Animal Chemistry,' that in one case of acute diabetic coma examined by

him, "the liver was found after death to be the seat of intense fatty infiltration, similar to that observed in cases of poisoning by phosphorus." I would also draw attention to the observations of Munk and Leyden, authors of the work on 'Acute Phosphorus Poisoning,' and who, in a paper on poisoning by sulphuric, oxalic, and tartaric acids, have also shown that these substances, like phosphorus, cause fatty metamorphosis of the tissues and organs; and I would further point out that the same conditions have been found with animals poisoned by the injection of the bile acids; so that the intense fatty degeneration of tissue and the lactescent condition of the blood in these acute cases of diabetes seem to be allied to the changes produced by phosphorus poisoning, or poisoning by oxalic acid, sulphuric acid, bile acids, &c.

In conclusion, I think the above consideration may warrant us in regarding the acute forms of diabetic coma as due to a toxic agent; that this agent is of an acid nature formed from the alcoholic fermentations of the glucose in the blood; that it is usually present in all cases of diabetes, and gives the highly acid reaction to the urine characteristic of the disease; that sometimes it is produced to an excessive extent, or its excretion is interfered with, in which case it gives rise to symptoms closely parallel to those observed in acute yellow atrophy, phosphorus poisoning, or poisoning with bile acids, or tartaric or oxalic acids.

Lastly, I would dwell briefly upon the practical outcome of such an inference, viz. that of treatment. It is obvious that this will be guided in great measure according to the view we take of the cause of the phenomenon. If we consider the collapse due to nervous lesion we must seek to rouse the patient and rally the vital powers. If we hold that the symptoms are caused by a toxic agent, then our efforts will be directed towards eliminating the poison. With regard to the latter, I believe the best plan to be that of transfusion either with blood or simply with water or a dilute saline solution. In this way we should the more speedily restore the blood to its natural percentage composition, at the same time an endeavour should be made to rouse the patient and promote the action of the cutaneous circulation. This probably would best be attained by the cold pack or affusion.

As the determination of the presence or absence of acetone or allied substances in urine is a matter that ought to be settled daily in watching a case of diabetes, I have ventured to introduce a

test which I think can be easily applied, and which will give an indication of the presence of acetone, &c., if present in anything like an appreciable quantity, say from 0·5 to 1 per cent. It is based on the well-known fact that acetone in contact with potassium hydrate and potassium iodide yields iodoform.

The procedure is as follows:—Dissolve four drachms of potassium iodide in one ounce of liquor potassæ. Of this solution place one drachm in a test-tube and boil, then very carefully add a drachm of urine so as to float on the surface of alkaline iodide solution. At the line of junction a white cloud of phosphates will form, which after a short time will become yellow if acetone, &c., be present. On looking down the feathery phosphates will be seen tipped with yellow points where the iodoform is deposited; these after a time fall through the cloud, and deposit at the bottom of the test-tube. Both conditions are seen in the tubes handed round.

Dr. Finlay said: My contributions to the discussion on the pathology of diabetes consist of—I. The record of a rapidly fatal case of diabetes with microscopical preparations from the lung, kidney, liver, pons Varolii, medulla, and spinal cord; and II. An analytical summary of twenty cases of diabetes from the *post-mortem* records of the Middlesex Hospital, with remarks by Dr. Coupland and myself.

I. I would scarcely have ventured, sir, to take part in this discussion but for the fact that a few months ago I had my attention directed to the subject by the death of a man who was under my care in the Middlesex Hospital. The case proved rapidly fatal, with the symptoms which have been summed up in the name diabetic coma; and having regard to the probability that in the case of such a comparatively rare disease as diabetes, the amount of available material for demonstration would be limited, I thought it well to place what I have at my disposal before the Society. I have accordingly prepared sections of various organs from the case referred to; namely, of lung, kidney, liver, brain, and spinal cord, which are now on view in the other room.

It may be proper to mention that the case from which the specimens were obtained was that of a young man, aged 21, who died on the second day after admission into the hospital. He stated that he had always had good health till a month before admission, when he noticed that he was unusually thirsty, and passed large

quantities of urine at frequent intervals, as often as every half hour day and night. When admitted his temperature was 98·2°, pulse 80, respirations 18; tongue dry, red and glazed, teeth honeycombed and discoloured. With the exception of a blowing systolic murmur over the upper part of the præcordia to the left of the sternum, there was nothing abnormal detected on physical examination of the chest and abdomen. His urine had a specific gravity of 1034, and contained 5 per cent. of sugar, but no albumen.

On the morning of the second day after admission, he complained of difficulty of breathing. About 1 o'clock he became restless, got out of bed and seemed somewhat delirious. On getting him back to bed his hands and feet were felt to be cold and clammy; his temperature was 97°, pulse 140, regular but feeble, respirations 36. He breathed with difficulty and stridor, and was in a state of semi-unconsciousness, although he could be roused to answer intelligently. His tongue was extremely dry and brown. The respiratory sounds over the chest were merely harsh, and the resonance normal. There was no sour smell perceptible in the breath. He had passed 212 ounces of urine during the preceding day. Excepting a little passed in bed there had been none since the graver symptoms set in. His comatose condition became rapidly more marked, and he died at 7.15 p.m.

At the *post-mortem* examination, which was made by Dr. Fowler, the only noteworthy appearances were a dark red colour of the muscles, slight enlargement of the mesenteric glands, an engorged and pulpy condition of the lower lobes of the lungs, two small fibrous tags on the mitral valve, and some small patches of atheroma on the aorta just above the valve. There was also a small hæmorrhage in the pancreas, which otherwise seemed normal. The liver weighed 52¼ oz., and appeared normal; the spleen was small (3¼ oz.) and pale; the kidneys normal, the capsules, however, being unduly adherent. The vessels of the pia mater were rather injected. The brain substance was firm and appeared in every respect normal to the naked eye, as were also the cord and its membranes.

The blood on being shaken up with ether yielded no fat, and under the microscope appeared perfectly normal.

The microscopic appearances of the various organs, taking them in order, are the following:

Lung.—The lung may be described as quite normal. In par-

ticular no fat embolisms are present. In addition to the usual black pigment found in adult lungs, there are a few rounded bodies, which have stained black with the osmic acid with which the sections were treated, but these are in the alveoli, not in the vessels, and probably consist of fattily degenerated epithelium.

The *kidney* shows granular swelling of the secreting epithelium, and some of the smaller tubules are plugged with what appear to be hyaline casts.

In the *liver* the cells are granular and ill-defined, with the nuclei rather obscured; there is an apparent excess of the interstitial nuclei, and also a slight amount of nuclear proliferation in the portal canals. No dilatation of the capillaries is apparent.

Brain and spinal cord.—In the nervous centres, the sections being from the pons, upper part of the medulla, and the various regions of the cord, some of the appearances described by Dr. Dickinson are found. The sections from the pons and medulla show something of the cribriform appearance referred to by him, but the excavations are small and do not appear around all the arteries. Some of them are, I think, certainly the result of the manipulation of the sections in mounting; others are probably due to the falling out of the vessels during the operation of cutting, favoured by the action of the fluids in which the specimens were hardened; and as to the rest (if any), it may fairly be questioned whether they are not more likely to be the consequence than the cause of the disease. If, as Dr. Dickinson says, these cavities are larger in rapidly fatal than in chronic cases, we should have had a typical manifestation of them in this case, which had lasted for only a few weeks. There is no appearance in them nor about the vessels of crystals of hæmatine. In the condition of the cord there is nothing calling for remark, except that the central canal appears natural.

I should say that the heart also was examined microscopically, and showed nothing abnormal. I regret that I omitted to investigate the condition of the sympathetic. There seems nothing in the record of the case to suggest an essential pathology, and it would be unsafe to do so until we have a much larger store of *post-mortem* records, with microscopic examination of all the viscera which might be concerned in the causation of the disease, particularly of the nervous system, as well as microscopic examinations of the same parts from cases of other disease, for purposes of comparison.

II. In connection with this subject, my colleague Dr. Coupland and myself have searched the *post-mortem* records of the Middlesex Hospital over a period of thirty-two years, and have found particulars of 20 cases of diabetes, 16 being males and 4 females, their ages ranging from thirteen to sixty. (See Appendix.)

The results of our inquiry we may summarise as follows, premising that our analysis is limited to the morbid conditions recorded, without reference to the mode of death, for which sufficient data were not obtainable in all the cases.

Brain.—The condition of the brain is not noted in three cases (3, 6, and 19), and it is stated to be normal in six cases. It is described as "congested," or as presenting on section an excess of puncta cruenta, in eight cases (1, 4, 7, 11, 12, 16, 17, 20); as soft and pale in one (8), and as firm and pale in two (5 and 9). The cerebral convolutions are noticed to be shrunken in two cases (15 and 16), there being an excess of subarachnoid fluid in six (7, 9, 10, 11, 14, and 16), and of ventricular fluid in five (7, 8, 10, 12, and 16). The arachnoid was opaque in two cases (9 and 11); cysts were observed in the choroid plexus in two cases (7 and 16). There was evidence of commencing meningitis in one case (12). Thus, it will be seen that the changes observed in the brain were in the main those depending on the quantity and quality of the blood, vascular engorgement, œdema of pia mater, and ventricular effusion. In only one case was there evidence of recent inflammation, and that but slight, namely, No. 12. In five of the cases it is particularly stated that no change was found "in the fourth ventricle (1, 4, 9, 13, 14); in two that the pons and medulla were normal; and that no excavations were visible to the naked eye in two (16 and 20), although in the case fully recorded above microscopical examination gave slight evidence of such perivascular erosion in the pons and medulla (No. 20).

Heart.—The heart is described as normal in ten cases (1, 4, 6, 8, 10, 11, 12, 15, 17, 18). In three cases (2, 14, 19) its wall is noted to be soft and flabby; in two cases (5 and 20) to be pale; in one (3) to be dark. In one case, that of a corpulent man with granular disease of the kidneys, it was markedly hypertrophied, weighing 28½ ounces (16). There was evidence of commencing pericarditis in one case (13), and in two others changes denoting previous pericarditis (2 and 15). Vegetations on the valves were found in three cases (2, 3, and 20), and valvular thickening is

mentioned in two (7 and 13). Atheroma of the aorta is recorded in three cases (9, 11, and 20). Thus there is only a minority of cases exhibiting any obvious degeneration of the heart muscle, but there is no record of microscopical examination of its fibres except in No. 20.

As to acute inflammatory changes there was slight endocarditis in three cases, and in only one was there any evidence at all, and that somewhat equivocal of pericarditis.

Lungs.—The most constant and marked lesions are those which are found in the lungs and pleurse, which are described as normal in but two instances (1 and 13).

In twelve cases there were old pleuritic adhesions (2, 3, 4, 6, 8, 9, 11, 12, 14, 15, 18, 20), and in two cases (9 and 10) recent pleurisy, one of them (9) being a limited empyema in connection with perforative ulceration of a pulmonary cavity.

Bronchitis was markedly present in one case (7), but in several more or less engorgement of the bronchi together with pulmonary congestion was observed. In one case the bronchi were plugged with membranous casts, an extension of membranous inflammation from the larynx (2), so that probably this case may be considered as one in which diphtheria supervened on the diabetes.

Pulmonary congestion is noted in seven cases (4, 10, 15, 16, 17, 18, and 20), and œdema in six (2, 5, 7, 11, 14, 15); these conditions, being found apart from recent or tubercular inflammation in four cases only. Acute lobular pneumonia in one case (7), in two (10 and 18) there was lobar pneumonia, which in one passed on to very extensive gangrene of the upper lobe.

As to phthisis and tubercular lesions in the widest sense there are three cases in which the latter were limited to single isolated nodules, caseous (12) and cretified (4 and 18), one of the latter being in the case of pulmonary gangrene just mentioned. In eight other cases these changes were more or less widely disseminated throughout both lungs, and occurred in very varying degrees of chronicity (3, 5, 6, 8, 9, 11, 14, 19). In six of these cases (3, 6, 9, 11, 14, 19) cavities were present.

It may be remarked that these phthisical lesions were often obviously of such old standing as almost to compel the conclusion that the diabetes arose in the subjects of tuberculosis, and not that the latter was secondary to the former. The comparative paucity of acute pulmonary inflammation, viz. three cases, is worthy of note,

and particularly the fact that in one case this passed rapidly on to gangrene.

Liver.—The liver is described as normal in seven cases (1, 2, 3, 6, 9, 10, 13), and in several others it does not appear to have presented any striking changes. Thus, in five cases it is noted to have been pale (3, 5, 7, 19, 20); in three to have been congested (4, 14, 15). It is described as soft in two cases (5 and 8), as firm and tough in four (15, 16, 17, 20), fatty in two cases (11 and 12), and pigmented in one (15). In this last case the pigmentation was striking, masses of brown material being accumulated in the interlobular tissue and in the portal canals, as well as in the hepatic cells. The lobulation is mentioned as being ill-defined in one case (18).

The size of the organ varied much. It is described as small in two cases, and in the other directions the most notable departures were, in Case 5, male, aged 21, weight 68½ ounces; Case 11, male aged 30, weight 82½ ounces; Case 12, female, aged 18, weight 71 ounces; Case 14, male, aged 27, weight 61 ounces; Case 15, male, aged 25, weight 75 ounces; and in Case 16, male, aged 52, weight 152 ounces, where the organ was of a dark, reddish-brown colour, tough, and coarse in texture.

These conditions, such as they are, might well be related to the part played by the liver in the production of sugar.

Pancreas.—We regret that the condition of this organ has been noted in so few instances—six only; but of these it is said to have been normal in structure in four (8, 9, 10, 14), although small in two of them (8, 10). It is said to have been enlarged in one (19), and in one case there is described a very advanced state of fibrosis with atrophy of the glandular parenchyma (6); in one case (20) there was a small hæmorrhage in its substance.

Spleen.—The condition of this organ is not noted in three cases (17, 18, 19), and is described as normal in six (1, 2, 3, 4, 8, 13). As to size, it was small in at least five cases, in one (19) weighing only 1½ ounces; but in three others it was considerably enlarged, weighing 10 ounces (10), 8½ ounces (6), and 7½ ounces, (12), being also noted as large in No. 16. It is described as pale in five cases (5, 7, 9, 14, 20); as soft in seven (6, 9, 10, 11, 12, 15, 16). In one case, where the organ was enlarged, there were hæmorrhages in its substance (16). This was a case of carbuncle with diffuse cellulitis,

and the condition of spleen may have been due to septic causes. In one case (5) it is said to have been the seat of a fibrinous deposit (? embolic). Although mentioning these changes in the spleen we have no deductions to draw from them.

Kidneys.—In the majority of cases these organs were larger than the average. Of recorded weights in fourteen cases the total weight of the two kidneys combined varied from 7½ ounces (4) to 16½ ounces, with a mean of 12½ ounces. They may be said to have been decidedly large in at least nine cases (2, 5, 6, 7, 8, 10, 11, 14, 16). They are described as congested in six cases (2, 3, 4, 7, 9, 18), as pale in four (5, 14, 15, 19), and flabby in three (2, 3, 5). In two cases they were granular with cystic degeneration of the cortex (7 16); but no other gross disease is described in other cases.

Stomach and intestines.—In one case (16), that of a lad, 17 years of age, the fatal event was due to severe enteritis with sloughing of a large part of the ileum, a lesion that has been occasionally recorded by other writers in this disease. In the same case hæmorrhagic erosions occurred in the stomach.

Blood.—In several cases the occurrence of dark-coloured clots in the heart is noted, and we do not gather that the blood showed any manifest departure from the normal. In two cases it is mentioned as being remarkably fluid (16 and 17), these two being the cases in which gangrene of intestine and of lung respectively occurred.

There is only one case in which the lipæmic condition was noted (5). It certainly was not present in any of the cases examined by ourselves during the last ten years, and it is fair to assume that it could not have occurred to any marked extent in the other cases.

The case of lipæmia seems to us worthy of special comment, as it formed the text of what is, perhaps, the most elaborate analysis of the condition published in our language, and it was not until we discovered the *post-mortem* record that we became aware of this valuable contribution to literature.

The examination was made in 1859 by the late Dr. Charles T. Coote, then Assistant-Physician to the Middlesex Hospital, and his paper on the subject of "Piarrhæmia," as he terms it, appeared in the 'Lancet' in September, 1860, a few months before his premature death.

The occasional occurrence of lipæmia in diabetes has of late years received renewed attention from its assumed connection with

fat embolism, as explanatory of the supervention of diabetic coma in some cases.[1]

We cannot but think that lipæmia in diabetes is not of frequent occurrence. It is interesting, however, to find it noted and described in such detail as it was by Dr. Coote twenty-three years ago, although, from the brief clinical record he gives of the case, there are not sufficient data to assign fat embolism as a cause of the fatal event. At the same time we may note that the lungs are described as œdematous, besides being the seat of tubercular disease, and that the spleen and kidneys were pale, the former being the seat of a "fibrinous deposit." In his paper Dr. Coote mentions many conditions in which fatty blood has been found, the chief being alcoholism and diabetes, his case being then the seventh recorded instance of its occurrence in the latter disease.[2]

Out of thirty-nine *post-mortem* examinations recorded by Dr. Frederick Taylor, in his paper on "Diabetic Coma" ('Guy's Hospital Reports,' 3rd series, vol. xxv, 1881), a milky condition of blood is noted in two cases only, and the most recent writer on the subject, Professor Frerichs ('Zeitschrift für Klinische medicin,' No. 1, 1883), seems only to have once met with lipæmia, and never with fat embolism.

Upon the latter point we do not here touch, as beyond Case 20 no special search was made for such embolisms; but as to lipæmia we may, we think, agree with Dr. Coote, that it "is not a *result* of diabetes mellitus, for either may exist without the other." He further goes on to say that "both seem to be consequences of the same derangement of the functions of the liver, which overloads the blood sometimes with an excess of sugar alone, sometimes with an excess of sugar and fat combined." We ourselves are unaware of any alternative hypothesis to explain the reason of this excess of fat in the blood in diabetes.

[1] Sanders and Hamilton on "Lipæmia and Fat Embolism in the Fatal Dyspnœa and Coma of Diabetes," 'Edin. Med. Journal,' July, 1879, p. 47.

[2] Rollo was the first to observe it in diabetes. Babington mentions that, "the most marked instance (of milky serum) that I have met, was in a case of diabetes where bleeding was several times repeated at long intervals, and on each occasion the same morbid condition of serum was observed. This was quite opaque, and nearly as white as milk; and on standing a few hours a film of matter resembling cream covered the surface." 'Cyclopædia of Anat. and Physiology,' vol. i, p. 422.

Lastly, we may mention that in one case (9) the observation is made of pressure upon the vagi nerves by enlarged cervical glands without inflammation, but in no case does there appear to have been any examination made of the sympathetic.

APPENDIX.—*Abstract of Twenty Cases of Diabetes from the post-mortem records of the Middlesex Hospital.*[1]

Case 1.—Male, aged 21, April, 1844. Emaciated. Brain congested. Lungs, heart, liver, spleen, and kidneys natural. Muscular tissue florid.

Case 2.—Male, aged 38, October, 1855. Brain presented no particular changes; in the floor of the fourth ventricle or elsewhere. Lungs and pleuræ: old adhesions on left side, bronchi of left lung filled with fibrinous casts. Larynx lined by false membrane. Right lung œdematous and emphysematous. Heart adherent anteriorly to pericardium; muscle soft and flabby; black blood on both sides; vegetations on aortic valves. Liver and spleen natural. Kidneys flabby, weight 7 oz. each, congested.

Case 3.—Female, aged 50, May, 1856. Brain: condition not reported. Lungs: both pleuræ adherent, a large quantity of grey and yellow tubercles scattered throughout both lungs, especially in upper lobes. Cavities at apices. Heart dark in colour; vegetations on aortic valves. Liver (40 oz.) natural, pale brown colour. Spleen natural. Kidneys flabby, congested; brownish-grey in colour.

Case 4.—Male, aged 17. April, 1859. Emaciated. Brain: dura mater and arachnoid injected. Brain presents numerous bloody points. Careful microscopic examination of medulla oblongata and roots of nerves issuing from it made, but nothing abnormal detected. Lungs: at left apex pleural adhesions and a calcareous deposit; lower lobes of both lungs engorged. Liver (34 oz.) congested, otherwise normal. Heart and spleen normal. Kidneys (3¾ oz. each) congested.

Case 5.—Male, aged 21. November, 1859. Diabetic odour perceptible. Brain: membranes healthy; about two ounces of serum at base of brain, which on exposure to the air becomes immediately covered with a thin white cream. The venous blood, which is quite fluid on escaping from the superior longitudinal sinus, appears

[1] The records commence in the year 1844, but there are two periods, viz., from September, 1846, to October, 1850, and from January, 1851, to April, 1853, for which no reports appear to have been preserved.

nearly of the colour of raspberry cream, but in a very few seconds it separates into two portions, one (supernatant) of the colour and appearance of thick white cream, the other of a deep reddish-black hue, like ordinary fluid venous blood. For purposes of examination blood was collected from—

1. The sinuses of the brain.
2. The innominate vein and right ventricle (which contained a very small, nearly colourless, non-adherent clot).
3. The hepatic vein.
4. The splenic vein.
5. The median cephalic vein.

The serum at the base of the brain was also set aside.

These were examined on the following day (November 5th). The supernatant creamy fluid appeared on every specimen except that from the splenic vein. Under the microscope it appeared *quite homogeneous*, with the exception of a faint trace of amorphous granular matter. It was wholly taken up when shaken with ether. Neither the blood from the splenic vein nor any other specimen presented the least appearance of a fibrinous clot. The serum was neutral in reaction. Blood from the hepatic veins, and also that from the splenic, contained free alkali, which when set free by heat restored the colour of reddened litmus. The reaction from the splenic blood was much the stronger. The blood was everywhere fluid excepting the clot in the right ventricle. Muscles red and well nourished. Brain weighed 49½ oz.; substance firm and pale. Structure under microscope, as well as that of cerebellum and medulla, remarkably healthy. Heart; muscular substance pale; valves healthy. Lungs: left, œdematous; right, apex infiltrated with masses of crude yellow tubercle, altogether as large as an orange, surrounded by pigment, and in a quiescent state; rest of upper lobe full of blood, œdematous, in some parts much softened. Liver (68½ oz.) of an ashen grey colour, very friable; microscopically showed excess of fat in liver cells. Spleen (3½ oz.) small, pale, containing one small fibrinous deposit, the size of a hazel nut. Kidneys (6½ oz. each) flabby; capsules non-adherent; surface pale and mottled; on section pale and coarsely striated. Supra-renals and mesenteric glands healthy.

Case 6.—Male, aged 40. May, 1861. Extreme emaciation. Brain not examined. Lungs: left, adherent at apex; small nodule of miliary tubercle at apex, tissue otherwise healthy; right, ad-

herent all over; upper lobe converted into one large cavity, communicating almost directly with the right bronchus. Adherent to walls of vomica were large masses of disintegrating lung substance, and also clots of blood. Heart (3 oz. of serum in pericardium): muscular tissue and valves normal. Liver (55 oz.) to all appearance normal; no enlargement of lobules. Spleen (8½ oz.) rather soft. Pancreas unusually firm and tenacious, and converted into firm fibrous-looking tissue; natural structure almost completely gone. Kidneys united at their lower extremities by renal tissue over front of spine. Weight of both together 14 oz. Structure firm, capsule separates easily, surface smooth.

Case 7.—Male, aged 49. April, 1862. Brain: considerable injection of the superficial vessels, and much effusion beneath the arachnoid, which is opaque over the whole of both hemispheres. On section, the brain substance presents numerous bloody points, with a pinkish hue of the grey substance. About half an ounce of slightly turbid serum is found in each of the lateral ventricles. There is considerable effusion at the base of the brain, and especially round the optic commissure, and the brain substance is rather more than usually firm. About half a dozen little cysts, up to the size of sweet peas, are found in the posterior part of each choroid plexus. Lungs: right lung (43 oz.) adherent over whole of base. emphysematous. Numerous patches of lobular pneumonia scattered throughout the upper lobe, and more numerously still in the lower lobe, in the stage of purulent infiltration; the whole lung œdematous. Bronchial mucous membrane highly congested. Left lung (25¼ oz.) in same state as right lung. Heart (10½ oz.): mitral and aortic valves thickened; tricuspid much thickened. Liver (54 oz.) very friable and pale. Kidneys: left, 6¼ oz.; capsule very adherent; surface beneath granular; a few cysts in cortex; hyperæmic. Right, 7 oz.; capsule not adherent, surface beneath smooth; some cysts. Spleen pale.

Case 8.—Male, aged 46. November, 1863. Brain: substance pale and somewhat soft, fornix and septum lucidum extremely so; ventricles contain about half an ounce of serum, which gives no saccharine reaction. Corpora striata, optic thalami, pons, and medulla normal. Lungs: pleural adhesions in both. Left studded with cheesy deposits; cavities at apex. Right also studded with tuberculous nodules, partly opaque and partly grey, and semi-translucent. Heart normal. Liver rather small, surface smooth,

somewhat soft in consistence; on section, smooth and of a darkish colour. Kidneys: left 7 oz., right 3½ oz.; normal in structure. Spleen normal. Pancreas small (2¼ oz.); structure normal.

Case 9.—Male, aged 60. February, 1864. Brain: opacity of arachnoid; considerable quantity of subarachnoid fluid; substance of hemispheres firm and pale; fourth ventricle quite normal; arteries at base normal. Lungs: apex of right lung firmly adherent to thoracic wall. In front, part of the pleura was separated at base from the rest of pleural cavity by firm adhesions, and formed a sac filled with pus and flakes of lymph; this communicated with a cavity in lung by a small opening. Pleura at back of lung covered by thick lymph. At apex a cavity surrounded by lung infiltrated with yellow tubercles, the size of peas. In lower part of middle lobe a large, ragged, irregular cavity filled with purulent fluid; this communicated with sac formed by part of pleura. In left lung firm adhesions at base and apex; cavity at base; numerous deposits of yellow tubercle scattered throughout lung tissue. Heart small; right ventricle and auricle filled with loose colourless clots; left side empty; atheroma at commencement of aorta. Liver small; opacity and thickening of capsule, extending over small space of upper surface; substance firm; of natural colour and appearance. Spleen small, soft, and light in colour. Kidneys congested, otherwise normal. Pancreas normal. In the neck the deep glands on either side were somewhat enlarged, and appeared to press on each pneumogastric; these appeared quite normal, and there was no inflammation about the sheath of either.

Case 10.—Male, aged 33. February, 1864. Extremely emaciated. Brain: membranes normal; small quantity of subarachnoid fluid; substance of brain firm and natural in appearance. Lungs: both pleuræ contained a small quantity of turbid serum; surface of both lungs and parietal pleuræ smeared with soft yellow lymph; injected and dotted with ecchymoses, most extensive on right side. Base of left lung engorged with blood, part in a state of red hepatisation; rest of lung normal. Right lung congested posteriorly, otherwise normal. Heart normal. Liver (59 oz.) normal. Spleen (10 oz.) large and soft. Kidneys large (left 7 oz., right 6½ oz.); normal in appearance. Pancreas small (1½); also normal in appearance.

Case 11.—Male, aged 30. February, 1866. Extremely ema-

ciated. Muscles pale and wasted. Brain: milky opacity of arachnoid covering hemispheres; pia mater much injected with considerable quantity of clear serum beneath arachnoid. Substance of hemispheres firm, and bloody points very numerous; pons and medulla apparently normal. Lungs: firm fibrous adhesions at left apex. Right lung œdematous; no tubercle. Apex of left lung solid from deposition of opaque yellow tubercle, and the seat of a small cavity. Several patches of grey miliary tubercle scattered throughout rest of upper lobe; lower lobe free from tubercle, but œdematous. Heart normal; a few patches of atheroma in arch of aorta. Liver large (82½ oz.) and somewhat pale; cells found to contain a good deal of oil. Spleen of moderate size and flaccid. Kidneys (right 8 oz., left 8¼ oz.) large, but found quite normal in structure on microscopic examination.

Case 12.—Female, aged 18. June, 1868. Brain: pia mater everywhere intensely injected; cerebral substance firm and very hyperæmic; medulla apparently normal. Lungs: A few old adhesions at base of right, none at apices. In right lung close to posterior surface of lower lobe was imbedded a small cheesy mass the size of a pea; lungs elsewhere normal. Heart normal; right cavities filled with firm decolorised clots. Liver rather large (71 oz.) and slightly fatty. Spleen large (7½ oz.) and very soft. Kidneys normal (right 5½ oz., left 5¼ oz.). On microscopic examination no tubercle was found in the pia mater, or sheaths of small arteries.

Case 13.—Male, aged 22. November, 1869. Rather emaciated. Brain: firm and healthy; the velum interpositum was perhaps slightly congested; the fourth ventricle appeared healthy. Lungs small but healthy (right 8½ oz., left 7¾ oz.). Heart: a few flakes of lymph in pericardium (?). Slight thickening of aortic and mitral valves, with commencing atheroma; heart otherwise healthy. The cavities contained very little blood. Liver rather dark and of moderate size (46½ oz.). On under surface a few of the lobules were opaque, and formed a small nodule slightly raised above the surface the size of a large pea. Spleen (3½ oz.) healthy. Kidneys large and very firm (right 5¾ oz., left 5½ oz.); pale, capsules not adherent. The organs were, with the exception of kidneys and liver, small.

Case 14.—Male, aged 27. April, 1873. Much emaciated; muscles wasted and very pale. Brain: surface œdematous; grey

matter paler than natural; a considerable quantity of cerebro-spinal fluid; nothing abnormal in floor of fourth ventricle. Pericardium contained three ounces of serous fluid. Heart: right cavities dilated and full of blood; muscular substance flabby; valves competent; some atheroma on surface of mitral. Lungs: right—firm adhesions over upper lobe; posterior part of lobe strewn with soft, opaque, cheesy granulations; rest of lobe riddled with cavities. A cavity the size of a walnut at extreme apex; a few of the opaque cheesy masses sparsely distributed through upper part of lower lobe; rest of lobe highly œdematous. Left universally adherent, most firmly over upper lobe which was almost entirely converted into one large cavity. Anterior portion of lobe presented tracts of cheesy material in midst of œdematous lung tissue; lower lobe engorged, some caseous deposits. Bronchial glands enlarged, not caseous. Liver large (61 oz.), firm, congested. Spleen (5 oz.) of pale brown colour, mottled with white. Kidneys: both considerably enlarged (7¼ oz. each), smooth and pale. Pancreas not enlarged or manifestly diseased.

Case 15.—Male, aged 35. November, 1873. Much emaciated. Brain: convolutions shrunken; no other change. Lungs: congested, especially at bases; great œdema throughout; right adherent to chest wall by one or two firm adhesions. Heart: valves competent; left side rather hypertrophied; a tough white fibrous patch of old pericarditis on anterior surface. Liver (75 oz.) rather rough on surface; congested. On section lobules are seen to stand out from surface, the substance being unusually tough. A fresh section under microscope showed liver cells filled with pigment. Kidneys (right 4 oz., left 5 oz.) pale, healthy. Spleen (4½ oz.) small and soft.

Case 16.—Male, aged 52. 1875. Great corpulence; carbuncle on back of neck, with diffuse purulent cellulitis. Blood notably fluid. Dura mater adherent. Brain shrunken, firm; subarachnoid fluid in excess; puncta cruenta in hemispheres very numerous; some effusion in lateral ventricles; cysts in choroid plexus; no excavations visible to naked eye in corpus striatum, optic thalamus, cerebellum, pons, or medulla. Lungs engorged. Heart (28½ oz.) hypertrophied. Liver (152 oz.) greatly enlarged, of dark reddish-brown colour, tough, coarse in texture. Spleen large, soft, and the seat of hæmorrhages. Kidneys (right 7 oz., left 7½ oz.) granular, cystic, tough.

Case 17.—Male, aged 13. 1876. Much emaciated. Brain: excess of puncta cruenta, otherwise normal. Lungs engorged. Heart normal. Blood fluid and black. Stomach presented hæmorrhagic erosions. Small intestines filled with dark fluid contents; mucous membrane of jejunum red and swollen; same condition observed in ileum, and at one part gangrenous sloughing; the inflammation diminished towards lower end. Liver firm, brown. Kidneys healthy.

Case 18.—Female, aged 24. 1877. Body spare. Brain natural. Lungs: both adherent at apices, especially left. At apex of right lung a cretified nodule. Upper lobe of left occupied by a large gangrenous cavity filled with pinkish-brown fluid; its walls ragged and sloughing; grey hepatisation of lower third of lobe; bronchi inflamed; in lower lobe a few granular masses; otherwise normal. Liver brown; its lobulation ill defined. Kidneys smooth; vascular.

Case 19.—Female, aged 44. 1880. Much emaciated. Brain not examined. Lungs: five ounces of fluid in each pleura; adhesions on both sides. In upper lobe of left lung a large irregular cavity, another in upper lobe of right lung, and in lower lobe a ragged cavity full of fœtid *débris*; patches of consolidation elsewhere. Heart soft; blood clotted. Liver pale. Spleen small (1½ oz.). Kidneys pale (4¼ oz. each). Pancreas enlarged.

Case 20.—Male, aged 21. November, 1882. Fairly nourished; muscles of dark red colour; mesenteric glands enlarged. Brain: vessels of pia mater injected; brain substance firm; cortex pink; convolutions not flattened; organ in every respect normal to the naked eye. Lungs: left adherent in front; lower lobes of both engorged and friable. Heart: two small fibrous "tags" on mitral valve; muscular tissue pale, but of normal consistence; cavities contained black blood and clots; some small patches of atheroma above aortic valves. Blood shaken with ether yielded no fat. Liver (52¼ oz.) firm, smooth, and of a light pinkish colour; on section tissue of normal colour; outlines of lobules distinct. Spleen (3¼ oz.) small and pale. Kidneys (right 4¼ oz., left 5¼ oz.) a little above average size, lobulated; capsules adherent. Pancreas soft, not enlarged; a small hæmorrhage in its substance, about an inch from its lower end.

For details of microscopic appearances of the various organs in this case the earlier part of this communication may be referred to.

Dr. Goodhart showed, for Dr. Hamilton, Professor of Pathology

at Aberdeen, a specimen of lipæmic blood taken from the heart of one of the cases described by Dr. Sanders and Dr. Hamilton in their paper upon lipæmia. Dr. Hamilton writes: "It is common enough; but lest there may not be a specimen at hand, I send it. It shows very well under the microscope the characters I have described. In those cases where lipæmia is present, I still feel that it must be the cause of the dyspnœa and death; but the change in the blood must be a complex one, and probably a minor degree of change in its constitution may unfit it for respiratory purposes and induce some amount of dyspnœa. In a case which occurred to me lately, the embola, composed evidently of an aggregation of oil globules, could be seen with the naked eye in the mesenteric and cardiac vessels. The oil globules were detected during life in blood drawn from the finger. In all the post-mortem examinations I have conducted upon diabetics during the last five years, I have never failed to find the acetone odour whatever the cause of death. But it is sometimes not characteristically developed until twenty-four hours afterwards."

Dr. Hale White.—The only point, Sir, to which I would venture for a few moments to draw the attention of this Society, is the condition of the nervous system in diabetes. Dr. Dickinson is the author who has brought this subject most prominently before the profession, and in his 'Diseases of the Kidney and Urinary Derangements. Part I. Diabetes,' on page 32 we find the following: "A practised and careful eye will often detect a fine porosity or cribriform appearance in limited patches of white matter, as if closely beset with pin holes. . . . More rarely, considerable cavities such as might hold peas are seen." On the next page he says: "Since I first noticed these changes, in the year 1868, I have especially examined the nervous centres in eleven cases of diabetes, and found them (viz. the cavities) in all;" and further on, "large excavations and pores in cribriform arrangement thus become evident to the naked eye." I hope, in the first place, to be able to show that, as far as our experience at Guy's goes, this is not the condition of the nervous system in diabetes; and, secondly, that this condition of the nervous system may exist without any diabetes. The following are the results of the examination of the nervous system in the last twenty-three cases that have died at Guy's. Most of the post-mortem examinations were made by either Dr. Hilton Fagge or

Dr. Goodhart, and in each case I have copied their remarks word for word:—

Case 1.—1878. Lucy F—, aged 28. Cause of death, coma. Brain weighed 48 oz.; looked perfectly healthy in every respect. I could see nothing whatever abnormal either in cord, medulla, or brain; the vessels all of normal size, and they compared favourably with those of a brain from a non-diabetic subject supposed to be healthy.

Case 2.—1879. Charles T—, aged 32. Brain quite normal; perhaps the vessels in the corpus dentatum cerebelli were a little large. The spinal cord looked quite healthy, but on section was rather soft, and on the right side below the seventh cervical nerve was a small abscess in the grey matter, apparently recent, confined to the grey matter, extending one inch down the cord; no tubercle.

Case 3.—1879. Sarah R—, aged 20. Cause of death, coma. Brain weighed 38 oz.; nothing abnormal found.

Case 4.—1879. Benjamin B—, aged 67. Cause of death, carbuncle, coma. Brain healthy.

Case 5.—1879. John S—, aged 35. Cause of death, coma. Brain weighed 46 oz.; finely convoluted, firm, congested. I examined it carefully in all directions, and could find nothing whatever abnormal. Dr. Frederick Taylor examined it afterwards and agreed in this.

Case 6.—1879. Thomas C—, aged 43. Cause of death, pneumonia. Membranes thick at sides of hemispheres; no thickening at base. Brain very firm, and quite healthy.

Case 7.—1879. Ernest B—, aged 14. Cause of death, typhoid. Membranes were normal, except that they were excessively vascular, the pia mater being everywhere minutely injected. I do not think this is of any significance, as the boy died in a comatose state. The brain was firm, and in all respects quite healthy to the naked eye. I searched very carefully through by slicing, and could find nothing in the way of gaps or pigmentary deposits visible to the naked eye either in the cortex, central ganglia, pons, medulla, or corpora dentata cerebelli. The spinal cord was, like the brain, injected on its surface, but everywhere perfectly healthy.

Case 8.—1880. Walter L—, aged 29. Cause of death, phthisis. Brain healthy; no signs of extravasations anywhere.

Case 9.—1880. — B—, aged 25. Cause of death, coma. Brain apparently perfectly healthy.

Case 10.—1880. George W—, aged 34. Cause of death, gangrene of lung. Brain to naked eye examination healthy.

Case 11.—1880. Sarah M—, aged 41. Cause of death, coma. Brain weighed 39 oz.; small, round, fairly convoluted, healthy in all respects. Cerebellum healthy; large vessels looked for, none found, there were the usual large vessels in the corpus dentatum, but the cerebellum, pons and medulla were quite healthy.

Case 12.—1881. James W—, aged 40. Cause of death, coma. Brain weighed 45 oz. A careful search all through the brain failed to show any disease; the brain was firm, as was also the spinal cord.

Case 13.—1881. Kezia W—, aged 26. Cause of death, pneumonia. Brain weighed 47 oz.; all parts perfectly healthy.

Case 14.—John S—, aged 56. Cause of death, phthisis. Brain weighed 48 oz.; very soft from decomposition, no disease of any part.

Case 15.—Isaac H—, aged 35. Cause of death, coma. Brain weighed 50 oz.; healthy in appearance, nothing abnormal found.

Case 16.—John B—, aged 36. Brain apparently healthy.

Case 17.—Thomas F—, aged 50. Cause of death, pneumonia. Membranes and vessels thick. Brain weighed 44 oz.; quite healthy in every part, and cord also.

Case 18.—Anne C—, aged 59. Cause of death, phthisis. Membranes thick and sodden-looking. Brain weighed 42 oz.; was very firm, the membranes stripping with remarkable ease. The brain was examined throughout, and nothing abnormal could be seen; excessive pigmentation over the medulla; cord perfectly healthy.

Case 19.—George M—, aged 64. Cause of death, pneumonia. Membranes very thick, arteries not atheromatous, but they were the thick vessels of arterio-capillary fibrosis. The brain was examined throughout, and nothing abnormal could be found; texture soft, cerebellum pons and medulla quite normal, and cord also.

Case 20.—William H—, aged 20. Cause of death, coma. Brain weighed 54 oz. A perfect brain, rather firm; ganglia healthy; vessels of corpora dentata cerebelli small; pons and medulla healthy, cord ditto. Microscopic examination showed the structure of the nervous centres to be perfectly healthy.

Case 21.—George A—, aged —. Cause of death, phthisis. Both to naked eye and microscopical examination brain and cord were absolutely healthy.

Case 22.—William B—, aged —. Cause of death, carbuncle. Brain and cord absolutely healthy. On making a section through the pons the vessels seemed rather large, but not more so than

normal. On microscopical section, owing to these vessels falling out of their spaces in the brain substance, a perforated appearance was given to the section, but it was quite evident that these were only holes due to the falling out of the vessels.

Such a series of cases as this proves, it seems to me, most conclusively my first proposition, viz.:—that this "Gruyère cheese," or vacuolated condition of, brain is not as a rule present in cases of diabetes. The only possible way in which I can explain the statement that the brain is vacuolated in diabetes is by supposing that those holes, due to the dropping out, from the section, of vessels rather larger than usual, have been mistaken for abnormalities. In proof of this being a normal condition I show two sections, one from the last case of diabetes in which it will be seen that on the under part of the pons, just below the surface, are several holes, but that these are not pathological is evident from the fact that in some the vessels may be seen falling out, and, furthermore, on contrasting them with sections from the pons of a perfectly healthy subject, it will be seen that a similar condition is there present. It is worthy of note that these spaces which might be called "small vacuoles" are more frequently present just above, or beneath, the under surface of the pons than elsewhere, that being explained by the presence of many small branches from the transverse branches of the basilar artery.

In support of these statments the entire brains, together with microscopical sections, are shown from cases 21 and 22.

For the opportunity of showing that the "Gruyère cheese" condition may be present without diabetes I am indebted to Dr. Savage, who has kindly allowed me to show sections of brain from the cases of "Coare" and "Cresswell," both of them lunatic asylum patients, in whom no sugar was present in the urine. I can also show sections of a "Gruyère cheese" brain from a case that came under my notice only after death. The patient had been an inmate of the hospital, and therefore there is the strongest probability that the urine was examined, and if so there certainly was no sugar because a note to that effect would have been made in the report, but as there is no mention of the urine the presumption is that it was healthy.[1]

On holding up to the light the thin sections of these "Gruyère cheese" brains now passed round many vacuoles will be seen, each

[1] These cases were subsequently made the subject of a separate communication by Dr. Savage and myself, to be found at page 1 of the present volume.

of them with a well marked, clearly defined margin, and all more or less rounded, quite different from any rents in the brain substance that may accidentally have occurred during mounting. As far as can be made out these correspond to the vacuoles described and figured by Dr. Dickinson, although they occur in subjects not suffering from glycosuria. I hope at some future time to be able to show the Society many more specimens of the different varieties of this condition occurring in the brain and other parts of the body, and therefore will not now spend any more time upon it (see p. 1, et seq.).

Dr. Dickinson on p. 46 of his work says that probably vacuolation may be present without there being diabetes, so that perhaps not so much stress ought to be laid on this second part of the argument as the first; nevertheless, it is interesting to see specimens in which this condition of brain is present in non-diabetic subjects, and if vacuolation be the true pathology of diabetes, it is a very strange fact that in all the cases in which Dr. Dickinson has found it, diabetes has been present, whilst in none of those three in which I have seen it has there been any glycosuria.

In addition to the above arguments for doubting whether these described changes represent the pathology of the disease, I would urge again, as I have previously done at p. 18 in the last volume of the 'Transactions' of this Society, that it is extremely unlikely that these grave changes should affect the medulla, and yet never implicate other centres together with the diabetic, for if they did we should expect to find paralysis, for example, of the seventh or ninth nerves as occasional accompaniments of diabetes, but as far as is known this is never so.

For these three reasons, then, it seems very doubtful whether the changes in the nervous centres described by Dr. Dickinson represent the pathology of the disease.

The results with regard to the post-mortem records of diabetics at Guy's, made me anxious to test Dr. Dickinson's statement that out of 106 specimens of urine passed by lunatics at Bethlem Hospital, forty-seven reduced copper in one or other degree, and of these eighteen the reduction was such that it could have been due to nothing but saccharinity, and among these eighteen three contained a considerable amount of sugar. With the help of Dr. Savage, who kindly aided me in the examination of the urine, I am enabled to give the following table:

Examination of the urine, especially with regard to the presence of sugar of forty-nine insane persons, inmates of the Bethlem Hospital.

Disease.	No. of Cases.	Sugar.	Slight Cupric Reduction.	Lithates.	Uric Acid.	Oxalates.	Phosphates.
Acute Mania . .	8			2	2		2
Melancholia . .	21		5	10	3	3	7
Dementia . . .	7	1			1		
Chronic Dementia	6						
General Paralysis	5			1		2	2
Puerperal Mania .	1	1					
Not Classified . .	1			1	1		

The case of puerperal mania was aged 22. Owing to the difficulty of collecting the urine the sugar could not be estimated quantitatively.

The case of dementia (male) was aged 56, and contained 1·95 grains of sugar to the fluid ounce.

Of the cases marked "Slight cupric reduction," none gave a brown precipitate with Dr. Pavy's blue liquid; three only turned the blue to a green coloration, and the other two gave a slight dirty-green precipitate. In all five cases this slight reduction was solely due to the uric acid present in the urine.

On contrasting these results with those arrived at by Dr. Dickinson we get the following:

Dickinson.—Some reduction (even slightest),	44·35	per cent.	of cases examined.
Hale White „ „	14·3	„	„
Dickinson.—Undoubted sugar . . .	16·65	„	„
Hale White „ . .	4·0	„	

But in order that it should not be objected to my tables taken at Bethlem that the number of cases examined there was too small, Dr. Paddison, of the Surrey County Asylum, Tooting, was good enough to help me to examine seventy-five specimens of urine taken from inmates of that asylum. The results were as follow:

Examination of the urine, especially, with regard to the presence of sugar of seventy-five insane persons, inmates of the Surrey County Asylum.

Disease.	No. of Cases.	Sugar.	Slight Cupric Reduction.
Acute Mania	10		3
Chronic Mania	21	1	6
Dementia	22		11
General Paralysis	4		
Epilepsy	7	1	4
Idiocy	1		
Melancholia	2		
Not Classified	8		3

The epileptic case (male) contained 1·388 grains of sugar to the fluid ounce of urine.

The chronic mania case (male) contained 1·89 grains of sugar to the fluid ounce of urine.

In this, as in the Bethlem table, "Slight cupric reduction" means only that due to uric acid, and on analysing the figures we find that 27, or 36 per cent., gave some reduction (even slightest), but of these only 2, or 2·65 per cent., contained sugar; of these two cases one was an epileptic, and so many attempts have been made to discover the pathology of this disease that it is certainly not due to any coarse change, such as has been described as the origin of diabetes. It will therefore be justifiable to exclude the epileptics, and if we do so, it appears that out of 68 cases 1 only contained sugar, or 1·47 per cent.; and putting together the Surrey County and Bethlem cases we see that, out of 117 cases examined, 3, or 2·56 per cent., contain sugar, against 16·65, as stated by Dickinson. As the table given by Dr. Dickinson contains no case of epilepsy it is quite fair, in comparing the two tables, to exclude the one that occurs in mine. In the face of these results I cannot help thinking that some of the cases mentioned by Dr. Dickinson as of undoubted saccharinity contained no sugar, but only uric acid.

The last point concerning which I am at issue with Dr. Dickinson is his statement that "a very distinct amount of sugar is to be detected in the urine of children with tubercular meningitis." I have searched the records of Guy's Hospital, and have only selected

cases in which the urine was carefully tested by competent observers, and find that in eight cases of tubercular meningitis there was no sugar present in any of them.

Dr. STEPHEN MACKENZIE (Plate XXIV).—In order to comply with the spirit of the circular issued by the Council, I propose to deal with the morbid anatomy of diabetes—1. By an analysis of all the fatal cases in the London Hospital, within a specified period, to illustrate how death is brought about in this disease. 2. To describe the naked-eye appearances of the body dead of diabetes. 3. To state the results of the microscopic examinations in the cases I have investigated.

1. Analysis of all the fatal cases of diabetes in the London Hospital from the beginning of 1874 to Midsummer, 1883.[1]

Death by coma, no gross disease found *post mortem*			7
Death by coma, no *post-mortem* examination.	No signs of pulmonary or other visceral diseases during life		3
	With pulmonary disease during life		1
Death by coma.	Recent pneumonia or phthisis		4
	Old pneumonia or phthisis		4
Total deaths by coma			—19
Cerebral hæmorrhage			1
Cerebral hæmorrhage, meningitis, coma			1
Cerebral tumour			1
Spinal cord disease and phthisis			1
Stricture of urethra, suppurative nephritis, coma			1
Tubercular nephritis, tubercle in lung			1
Pneumonic phthisis			9
Scirrhus of pancreas, sudden collapse			1
Gangrene of foot, death rather sudden			1
Dermoid ovarian cyst, calcified mesenteric glands[2]			1
			37

From the above table it will be apparent that in many cases there were other conditions present besides the diabetes that may have had an influence in bringing about the death of the patient. In some instances it is difficult to determine the share such conditions took in causing, or being caused by, diabetes. Some, as phthisis

[1] I am greatly indebted to Dr. Gabbett, at the time medical registrar, for assistance in investigating the records for this analysis.

[2] Believed to have helped herself to codeia.

pulmonalis and renalis, and gangrene of foot, are, no doubt, the outcome of diabetes; but in others, as, for instance, the cerebral meningitis, cerebral tumour, disease of spinal cord, these conditions may not stand either in causal or consequential relationship to the disease, only coinciding with it, for it cannot be held that diabetes confers an invulnerability from all other morbid conditions.

From a study of this series of cases of fatal diabetes, two facts stand out prominently—the tendency of the disease to bring about phthisis, and to terminate in coma.

Some pulmonary affection, pneumonic or phthisical, was present in twenty of the thirty-seven cases, in one case associated with renal phthisis. In ten of the cases these destructive lesions in the lungs and kidney were the actual means of bringing about the patient's death, whilst in others, no doubt, they contributed to this result. The phthisical conditions were the result, and not the cause or concomitants, of diabetes, many of the cases having been under observation for diabetes before any signs or symptoms of phthisis presented themselves, and in all the remainder there was evidence, by symptoms, of the antecedence of the diabetes. The only organs involved by the destructive process we call phthisis, in this series of cases, were the lungs and kidneys—organs which considerations would lead us to expect are placed under peculiar conditions in this disease. In the case of cerebral meningitis tubercles were not observed. The absence of the disseminated changes known as general or diffused tuberculosis is interesting, and in accordance with the results of most observers. The importance, however, is more apparent than real. This point will be referred to again later.

As to the dependence of the phthisis on the diabetes, I think no doubt can be well maintained. I know of no one other general disease which is so frequently succeeded or complicated by phthisis. As to how the phthisis is induced, whether owing to the marasmus, the glycosuria and its consequences, or other influences, I do not propose to discuss. Nor do I think it of any importance to show that glycosuria is frequent or infrequent in phthisis, this being in my opinion to invert the order of the phenomena under discussion.

Death was determined by coma in nineteen of the thirty-seven cases in this series, or in just over half the number. This is ex-

cluding all the cases where an obvious cause other than diabetes existed for coma, such as cerebral hæmorrhage, meningitis, cerebral tumour, and suppurative nephritis. Of these nineteen cases of coma, *post-mortem* examination showed no gross visceral lesion, such as could be concerned in producing this mode of termination of life, in seven cases. In three other cases, in which no examination was made after death, there were no signs of pulmonary or other visceral disease during life. In eight cases of diabetes, dying of coma, phthisical or pneumonic changes were found *post-mortem*, and in one case in which no examination was made there were well-marked signs of pulmonary phthisis during life. In some of the cases the pulmonary disease was quite insignificant in amount, and could scarcely have contributed to this special mode of death, whilst in others the changes were more extensive and advanced. But no cases are included in the category of diabetic coma unless the clinical evidence of this mode of death was distinct, and the coma, whilst presenting slightly different features in individual cases (as it did in those in which no visceral lesion was discovered), differed in no essential respect from that which occurred in pure and uncomplicated cases. In only four of the nine cases of coma in which pulmonary disease was found was the disease at all advanced, or rather, extensive; a point on which I would lay stress, as my experience teaches that absence of pulmonary disease, or, if present, but little advanced (or extensive) disease of the lungs, is one of the conditions which especially renders the occurrence of diabetic coma probable. This is almost equivalent to saying that the coma depends on the severity of the disease, as regards sugar misappropriation, for, as is well known, as the pulmonary disease advances the sugar in the urine generally lessens, and often totally disappears before death, when this is brought about by phthisis. It would seem, indeed, that the natural mode of termination of diabetes is by inducing phthisis, but that in a large proportion of cases this stage is only partly reached, or not reached at all, owing to the patient being prematurely cut off by coma.

There are certain other circumstances specially tending to precipitate death by coma in diabetes. These are the age of the patient, the rapidity and severity of the disease, and conditions that tax the enfeebled strength of the diseased organism.

As regards age: in this series of cases the mean age of patients dying of coma was 33·5, the mean age of patients dying of diabetes

in all ways was 38·5 years. But this bare statement does not represent the whole matter, for *all the cases, with one exception only, dying at or below 25 years died of coma*, the mean age being brought up to 33·5 by ten cases above 25 years.

Duration of disease. The rapid course of the disease, which, as a rule, is equivalent to its severity, but influenced by age also, has an important effect on the determination of coma, as shown by Dr. Frederick Taylor.[1] Thus, in my series of cases the mean duration of the whole series of cases was rather over one year and three months, whilst in the cases of pure coma it was only eight months. The duration of the classified cases is shown in the following table:

Duration of Disease.

	Maximum.			Minimum.			Mean.		
	Yrs.	Mhs.	Wks.	Yrs.	Mhs.	Wks.	Yrs.	Mhs.	Wks.
Pure coma (with *p. m.*) . .	2	0	0	0	0	5	0	8	0
Coma, no *p. m.* — No pulmonary disease	1	0	0	0	2	0	0	5	2
Coma, no *p. m.* — With pulmonary disease (1 case) .							1	0	0
Coma, no *p. m.* — With acute pulmonary disease .	1	9	0	0	3	0	0	10	2
Coma, no *p. m.* — With old pulmonary disease . .	3	10	0	0	2	0	1	5	0
Phthisis, no coma	3	6	0	0	4	0	1	4	0
Miscellaneous deaths . . .	8	0	0	0	0	7	2	0	2
Of whole number							1	3	2

It has been shown by many writers since the time of Prout that fatigue, as a journey, often induces the coma.

As regards the essential nature of this coma various opinions, founded on the observed conditions in some cases, have been put forward.

Occlusion of the vessels by fat, especially the pulmonary and renal arterioles and capillaries, has been found in a few cases, and this has been advanced as an explanation of diabetic coma.

In the third section of these remarks I give the result of numerous examinations on this point, which show that no fatty embolisms were found in any of these cases, and that this explanation, whilst possibly sufficing for some cases, cannot be held as applicable to

[1] 'Guy's Hosp. Rep.,' 1881, p. 160.

the whole class of cases of diabetic coma. The same remarks apply to a character of the blood which has been observed in some cases of diabetic coma. In none of this series had it the laky or creamy character that has occasionally been found.

An acetone odour of the breath was not noticed in any of the cases in this series observed by myself, nor is it recorded in the *post-mortem* notes. I have noticed it during life in other cases not included in the series.

As to the nature of the coma that so frequently terminates in such a dramatic manner in cases of diabetes, whilst I can afford no positive evidence on this point, I cannot help arriving at the conclusion, from having closely watched a number of cases, that its sudden onset, peculiar features, and the absence of marked changes of a constant character in the dead body, indicate that it is due to some chemical agency—some poison acting on the nervous centres in a peculiar and characteristic manner. What that poison is there does not appear to me to be sufficient evidence to prove. It may be, if not acetone itself, of a nature allied to acetone. Fat embolisms must be regarded as too inconstant to explain the condition. The case of fat embolisms in the lungs and kidneys and fatty blood, so well described by Sanders and Hamilton,[1] is one of great importance, because the coma was of a very typical character, and the embolisms of fat in the lungs and kidneys might explain many of the most striking symptoms. The absence of fatty embolisms in other equally typical cases would lead to the inference that some other undiscovered factor was in play.[2]

2. The appearances noticed in the bodies of those dying of diabetes.

It would in my experience be difficult, and in many cases quite impossible, to conclude from the *post-mortem* examination, without any clinical history of the case, that the patient had died from diabetes. Some of the appearances might be suspicious, but there are none that can be held pathognomonic. The great wasting, in a case in which no organic lesion was found, might raise a suspicion, but it would only amount to this, without a chemical examination of the urine or tissues. In a case of consecutive phthisis the appearances in the lungs and other organs would not enable us positively

[1] 'Edinburgh Med. Journal.'

[2] I dealt with this question more fully at the Pathological Section of the Brit. Med. Assoc. Annual Meeting, 1882, 'Brit. Med. Journ.,' April 7th, 1883.

to affirm, in any case, that the phthisis was connected with diabetes. At the same time there are appearances which, if not pathognomonic, are common or characteristic.

Emaciation is, of course, almost always present.

The nervous system.—The brain is generally greatly wasted, the convolutions being atrophied and the subarachnoid fluid being correspondingly increased. One patient, who succumbed really to consecutive phthisis, was found to have a recent minute hæmorrhage in the floor of the fourth ventricle. This could have had no influence in the causation of the disease. Beyond wasting I have found no constant appearance of a morbid character in the brain, never the naked-eye cribriform condition described by Dr. Dickinson. The spinal cord is generally firm, but presenting no sign of disease.

Heart.—The heart is generally found wasted. In one case only was it hypertrophied, and once there was found interstitial degeneration of the heart walls.

Blood.—The blood in many cases is noted to have had a dark or tarry character; in others it appeared natural. In no case had it the laky or creamy character which has sometimes been noticed in diabetes.

The liver is recorded to have been smaller than natural. In some cases it was firm, in others soft. It was usually darker than normal, and what is most characteristic as regards its appearance has been a homogeneous shiny appearance.

The spleen has varied; in some cases it has been wasted, in others soft; it sometimes has the dark, homogeneous, shiny appearance seen in the liver.

Kidneys.—The kidneys are usually found larger than natural, soft, and congested. Occasionally they present the shiny dark appearance observed in the liver and spleen.

Pancreas.—The pancreas was examined in most of the cases. In only two are important changes recorded. In one the ducts were full of calcareous concretions; in the other the pancreas was the seat of scirrhus. What influence the latter had, if any, in the production of diabetes is uncertain, but it must be remarked that this organ is not unfrequently the seat of cancer, without glycosuria resulting. In this case there were secondary deposits of cancer in the liver.

The Lungs.—In cases dying of coma the lungs are nearly always congested, and often œdematous.

As already stated, pulmonary disease is present in nearly half the cases. The *post-mortem* appearances are those of a disintegrating pneumonia. The individual patches vary in size, tending to aggregate, to take on the so-called cheesy character, and to break down and form irregular cavities, usually without distinct lining membrane. Miliary tubercle is undoubtedly rare.

3. Microscopic appearances.

The remarks made as to the naked-eye appearances of the organs in diabetes apply equally to their histological examination. I have found no appearances which are special to diabetes (with, perhaps, the exception of a peculiar condition of the renal epithelium), nor any so constant as to appear inseparably connected with this disease. At the same time there are some changes which, though not peculiar to it, are frequently found in diabetes.

Nervous system.—I have examined microscopically portions of the nervous system in fourteen cases, of which the cortex of the brain has been examined in eleven, the medulla in eight, the pons Varolii in five, the corpus striatum in three, and the spinal cord in three cases. In three of the cases no changes were apparent. In six cases there were slight perivascular and periganglionic dilatations, and in four other cases there were excavations of a doubtful character; in some the perivascular dilatations were quite trivial in degree, such as are often seen in the bodies of those dying from the most various diseases, and in none were these of such marked characters as those described by Dr. Dickinson, whose specimens I have, by his kindness, had the opportunity of seeing. In some of the cases in which the dilatations are present blood pigment is found occupying the spaces. I am in doubt how much of the appearances of perivascular dilatation and excavation are due to the mode of preservation adopted. In several of the cases there were myelin deposits, clearly from faulty keeping. I do not find any characteristic distribution of such changes as I have noticed, but my observations are not sufficiently numerous on this point to have any value. The ganglion cells in the medulla, pons, and elsewhere, have in several of the cases undergone granular and pigmentary degeneration. A hyaline degeneration of the intima of the minute arteries is observed in some cases, but the change, which is better marked in other parts of the body, is not peculiar to diabetes. In one of the cases which was examined by Mr. Nettleship, a similar condition of the retinal arterioles was found, and

in addition miliary aneurisms. This case had clinically presented the signs of glycosuric retinitis.

The spinal cord presented no important changes.

Lungs.—Portions of the lungs were examined in sixteen cases. Intra-alveolar extravasations of blood were found in seven cases. In six of these the patient died from coma of the diabetic kind, and in the remaining case, in which a cerebral tumour was found, death also was from coma. The lungs in these cases were greatly congested. In some a hyaline condition of the intima of the arteries was present. The extravasations were quite minute, and must be regarded as mainly, if not entirely, due to the mode of death, and not as dependent on the disease inducing it.

The most common change in the lungs, and that claims attention, is the pneumonic or phthisical. This was present in seven of the sixteen cases examined. The process appears to begin as a (in the pathological sense) croupous pneumonia, with some thickening of the alveolar walls. The exuded and proliferated contents of the air vesicles and the alveolar walls and blood-vessels undergo a necrotic process—in well-stained specimens these parts take very little of the dye—the vessels become obliterated, and the necrosed part crumbles away and forms cavities. The "obliterative arteritis" of Friedländer[1] is well seen in many of the alveolar blood-vessels, and no doubt plays an important *rôle* in the process of necrosis. In only one of the cases were giant cells found. This was in the case of a man in whose lungs, after death, the changes found were of the character of ordinary phthisis, and were described as "broncho-pneumonic." In no case were there diffused miliary tubercles. As to whether the destructive changes in the lungs should be called tubercular, I regard as quite unimportant, as long as their character is understood. I mentioned at the debate that in four of the cases, including that in which giant cells were present, no bacilli had been found; but Dr. Heron, who kindly made an independent examination on this point for me, has seen bacilli in the lungs of diabetics; and since the discussion I have had a case of diabetic phthisis with bacilli in the sputa. The lungs in this case presented the usual characters seen in the phthisis supervening upon diabetes.

Liver.—Sections of the liver were examined in eleven cases. In seven of the cases no important changes were found. In

[1] 'Centralblatt, f. d. Med. Wissenschaft.,' 1876, No. 4, s. 65.

two cases there was atrophy of the liver-cells, but in one of these the tissues were not well preserved. One showed granular and pigmentary changes in the hepatic cells, and one hyaline degeneration of the intima of the arteries. In one case only was fatty degeneration of the liver-cells present, and in it the process was well marked, and associated with slight interstitial inflammation. The case was one of consecutive phthisis with giant cells, and there was commencing tubular nephritis. The fact that in only one of the eleven cases examined was there any sign of fatty degeneration or accumulation in the liver-cells is important with reference to the lipæmia and fat embolisms sometimes found. If the liver were fatty a source for the fat in the blood would exist. Sections of the liver, the lung, and the heart of this case were treated with osmic acid, but no fat had found its way into the vessels.

Spleen.—The most important change in this organ is a hyaline degeneration of the arteries. It was present in all the five cases examined, though to different degrees. The change consists in a hyaline swelling or transformation of the arterial walls. This alteration is often limited to the elastic portion of the intima, but occasionally it spreads beyond this area and invades the muscularis. The result of this swelling of the intima is to encroach on the calibre of the affected vessel. Sometimes the swelling is more or less concentric and regular, but more often it does not affect the whole circumference of the vessel, but forms a lateral bulging into the interior of the canal. The endothelium of the intima is pushed before it, circumscribing it. The lumen of the affected vessel is greatly reduced by this hyaline swelling, and may be almost obliterated. The material in question has a peculiar faint yellow or yellowish-brown colour in logwood-stained preparations, and appears very similar in sections treated with osmic acid. It is not acted on by iodine or methyl-anilin in a similar manner to amyloid or lardaceous material. This change in the vessels is an interesting one, but not in any way peculiar to diabetes. Dr. Klein has described it in connection with enteric fever[1] and scarlatina.[2] I have found it present in the spleen in nearly all the cases of pyæmia I have examined, in a case of angina Ludovici (submaxillary cellulitis), and in several other diseases. It differs from the hyaline fibroid change of arterio-capillary fibrosis described by Sir William Gull

[1] 'Rep. Med. Off. Privy Council,' New Series, No. vi.

[2] Ibid., No. viii.

and Dr. Sutton. It differs altogether from the "obliterative arteritis" described by Friedländer, or the similar change described by Heubner as "syphilitic degeneration of the cerebral arteries."

Heart.—The heart was examined in nine cases. The muscle-fibres were usually atrophied, the striæ ill-marked. No fatty degeneration or accumulation was present in any case. The muscle nuclei were undergoing pigmentary degeneration in several of the cases. In one case there was commencing carditis, and in another the muscularis of the arteries was hypertrophied. The microscopic changes in the heart were such as are usually seen in persons dying from chronic or wasting disease, presenting no other peculiarities, either in kind or degree.

Kidneys.—The kidneys were examined in seventeen cases. Comprising as this number did patients of various ages, the changes incidental to the different periods of life were of course present, but have no bearing on the disease. The epithelium of the convoluted tubes was in several of the cases in a granular or disintegrating condition, in some measure at least due to post-mortem changes. There is one change, however, affecting the epithelium of the collecting tubes which, as far as I know, is special to diabetes. This change has been described by Cantani, from observations of Professor Armanni.[1] Cantani is the only author in whose work I have found a description of this change. This alteration of the epithelium is a vesicular condition of the cells, which become swollen and translucent. The nucleus usually remains in its natural position in the interior; it also may become vesicular, but this does not necessarily take place. The cell looks as if washed out, only the framework remaining, and it calls to mind the translucent appearance of vegetable cells (Plate XXIV). The change, so far as I have seen, is confined to the epithelium of the collecting tubes, as mentioned by Cantani. It was present in greater or lesser degree in six of the seventeen cases examined. Cantani thinks the condition due to dropsy of the epithelium, but considers the irritating influence of the sugar in the urine may have an influence in its production. It is probably the same process as gives rise to what is known as "dropsical degeneration" of epithelial cells elsewhere.[2] A hyaline degeneration of the intima of the arteries was present in

[1] 'Le Diabète Sucre,' by Dr. A. Cantani, translated by Dr. Charvet. Paris, 1876, p. 344.

[2] Zeigler, 'Gen. Path. Anat.,' translated by Macalister, p. 77.

six of the seventeen cases examined. The change is identical with that described more fully under the spleen (Plate XXIV).

Pancreas, thyroid, and stomach.—The pancreas was examined microscopically in four cases. The epithelium was more granular and indistinct than natural in one. In another case there was slight fibrosis, but the patient was 54 years of age. Hyaline degeneration of the arteries was present in two of the cases. The thyroid body was examined in one case (male, aged 49), and there was increase of the connective tissue found. In one case the stomach was examined, and slight interstitial gastritis detected. The patient was a male, aged 35, and died of consecutive phthisis.

With reference to the question of lipæmia and fat embolisms, I have examined a number of sections hardened in chromic acid and spirit, in bichromate of ammonia, and subsequently in spirit, and in absolute alcohol, and spirits of wine.

The sections were cut by hand or by microtome, and placed for the requisite time in a one-half per cent. solution of osmic acid.

I have in this way examined sections of three cases of pure coma (diabetic), five cases of diabetic coma with visceral lesions, ten cases of diabetes in which death occurred in various ways, and in which diabetic coma was not present. The lungs were examined in fifteen cases, kidneys in sixteen, liver in eleven, heart in ten, nervous system in twelve, spleen in four, pancreas in three, the thyroid body in one case.

In none of these cases was fatty matter found in the blood-vessels. I purposely examined a number of non-comatose cases to ascertain whether there was any special source for, or tendency to, fatty absorption, but none was discovered. As already stated in only one case was an organ found in a state of fatty degeneration (the liver). I think these series of observations justify the expression of an opinion that lipæmia and fat embolisms are not present in many well-marked cases of typical diabetic coma, and that the tendency to fatty blood does not appear to be of frequent occurrence in diabetes. The results of my examinations are thus mainly of a negative character, and, as far as they go, do not indicate that the morbid anatomy of diabetes throws any light on the essential nature of the disease.

DR. SEYMOUR TAYLOR (Plate XXIII, fig. 1).—Mr. President, I have recently had opportunities of making or witnessing post-

mortem examinations in four cases of diabetes. They were all adult males, and in each the typical diabetic coma supervened shortly before death.

I examined the kidneys very carefully of three of the cases, not with any idea of finding a primary lesion, but with a view to ascertain if there were any, and if so, what, secondary changes. The organs presented to the naked eye the usually described vascular engorgement. Microscopically, the glomeruli showed marked extravasation of blood; hence they were of a pale, yellowish tint. The epithelium of the tubuli, however, was remarkable. The cells were large, of a yellow-brown colour, and their nuclei failed to take the hæmatoxyline staining. The most characteristic feature was a tendency for the epithelium to come away from its basement membrane *en masse*, so that in parts the kidney presented a mere skeleton outline of its normal condition. The shedding of the epithelium was not in the form of a cast, as there seemed to be no fibrinous exudation to form the basis of a cast: it was merely a well-marked necrosis, and as such was evidently a secondary change. By staining sections after the manner described by Frerichs good results are obtained. It is, briefly, as follows: The kidney must be hardened in absolute alcohol, as any aqueous solution dissolves the glycogen from the tissues. The sections are then immersed for a short period in a weak solution of iodine and iodide of potassium, and mounted in glycerine. The presence of glycogen in the epithelium then shows itself by the mahogany tint, or by shades of colour varying from a rich yellow to a dark red or brown.

The liver in all the cases presented a similar congested state to that of the kidneys; the cells being shrunken and atrophied from pressure, more especially in the outer zones of the lobules.

As regards the central nervous system the positive evidence of pathological change was almost *nil*. I could find no morbid change in the brain, the medulla, the spinal cord, or the sympathetic ganglia, with the exception of a hyaloid thickening of the blood-vessels, a condition which has been also noted by a previous speaker, Dr. Stephen Mackenzie. But I did not gather from Dr. Mackenzie's remarks that he considered these changes as pathognomonic. Some of the sections exhibited by Dr. Dickinson bore a resemblance to some of the so-called lesions of the nervous system in chorea; but I am of opinion that I have seen similar conditions in the brain and cord of a presumably healthy man, and in a certainly healthy dog; and



Fig. 1



Fig. 2.

DESCRIPTION OF PLATE XXIII.

FIG. 1.—To illustrate Dr. Seymour Taylor's communication upon the Morbid Anatomy of Diabetes. (Page 366.) Section of kidney from a case of diabetes. From a drawing by Miss Alice Boole.

a. Glomerulus with extravasated blood-corpuscles.
b. Urinary tubules from which the epithelial lining has dropped out.
c. Blocks or masses of epithelium which have come away from the tubules.

FIG. 2 illustrating Dr. F. Taylor's Case of Lympho-sarcomatous Ulceration of the Back. (Page 247.)

The figure represents a section of the tumour of the back (Plate XVI, fig. 2), and shows lymphoid cells, with a small amount of reticulum, and small blood-vessels containing corpuscles.

From a drawing by Dr. F. Taylor.

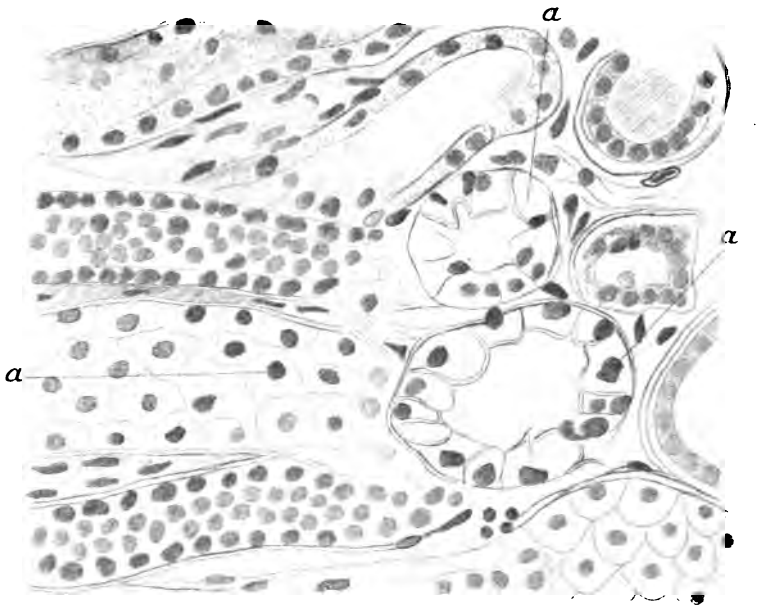

Fig. 1



Fig. 2

DESCRIPTION OF PLATE XXIV.

To illustrate Dr. Stephen Mackenzie's communication on the Morbid Anatomy of Diabetes. (Page 364.)

From drawings by Dr. Stephen Mackenzie.

FIG. 1.—Section of kidney, showing peculiar alteration of epithelium (dropsical swelling ?).

a. The translucent epithelium having the appearance of vegetable cells. (About 615 diameters.)

FIG. 2.—Afferent artery of glomerulus.

a. Hyaline transformation and swelling of artery.

b. Nuclei of endothelium.

c. Bowman's capsule.

d. Glomerular capillaries. (About 615 diam.)

I would suggest, with all deference, that it would be a subject not unworthy of the attention of the Pathological Society, to endeavour to decide what appearances in the central nervous system are morbid, and what are due to our methods of preparation. I am sceptical of some of the so-called lesions in the brain and cord, and I am inclined to think that many of the conditions we regard as morbid may be due to our methods of hardening and cutting.

Since Claude Bernard's remarkable discovery as to the production of glycosuria by injury to the fourth ventricle, we have been working with this observation as a centre. We have taken a physiological experiment as the basis of a supposed pathological fact; and although such may be the true method of morbid research, I apprehend it may occasionally lead us to fallacy. I look upon diabetes in our present light as a functional disease, and should continue to do so until I can find some undoubted lesion; and upon these lines my treatment of a case would be based.

Dr. Frederick Taylor.—After all that has fallen from other speakers, I am afraid that I shall have little to say that will be fresh, or that will throw any new light upon the difficult questions of diabetes.

I have paid special attention to two points in connection with diabetes: one, the condition of the nervous system as demonstrable after death to the naked eye or under the microscope; the other, the mode of death in diabetes. With regard to the first, I am not prepared to add new discoveries, but rather to express doubts of the reality of some already advanced. I believe that too much has been assumed in the attempt to demonstrate that the nervous system in diabetes is the subject of a number of pathological changes, which may be regarded as the *fons et origo* of the disease. And I may say that I have felt it my duty to come here this evening, because, in conjunction with Dr. Goodhart, I ventured to call in question the reality of these supposed changes, and the justice of the views founded upon them; and it seemed desirable that we should take this opportunity of submitting our specimens to the judgment of members of the Society, in order that as far as possible a right opinion as to the facts may be formed. I am not claiming that this question should be settled by the examination of any such limited number of specimens as is likely to fall into the hands of one or two observers, and I am very glad to find that others have investigated

the subject, of whom Dr. Finlay, Dr. White, and Dr. Mackenzie have already given the Society their results. But the interest of the specimens I have to show is, that they have been examined by Dr. Dickinson himself, who has expressed his opinion upon them in the medical press, and the Society will be in a position to decide whose views are the more correct.

We examined the nervous centres of nine cases, and the results were published in the 'Guy's Hospital Reports' for 1877, with a criticism of Dr. Dickinson's views on the specimens he originally described. Dr. Dickinson subsequently examined our specimens, and while allowing that the slides showed a minimum of change, marked a number of slides, in which he considered that the changes which he had described were demonstrable. I have placed a number of these slides under the microscope, and I have the remainder for the inspection of members if required. What I observe is, that the great majority of these slides marked by Dr. Dickinson came from one patient; the case in which we ourselves recognised some rather unusual appearances. I do not propose to go into details about these particular cases, because it would take up the time of the Society unnecessarily, and they have been already stated; but I feel that the great authority of Dr. Dickinson, which has led his views on the nervous system in diabetes to be widely copied in text books, cannot be opposed by a mere *dictum*, and therefore I would claim the indulgence of the Society while I say a few more words about it. Our conclusions were that the bulk of these cords and brains were practically healthy—that is to say, that minute differences of size of artery, size of perivascular space, quantity of fibrous tissue, were well within the limit of variations found in persons who could not be supposed to be suffering from any disorder, even functional, of the nervous system. We thought ourselves therefore justified in saying, from the examination of nine cases, that there was no *constant change* in the nervous centres of diabetics. The most considerable deviations from the usual standard that we found were the presence of glistening bodies of orange red colour (which might be hæmatoidin) about the vessels in one case; large size of vessels in one; rather thick walled vessels, and thick connective tissue septa in the cords of about half.

What we certainly did not see was any trace of nervous degeneration and decay, or anything that would, in our opinion, justify one in drawing the elaborate picture which has been presented to

us of vessel dilatation, of accumulation and extravasation of their contents, causing intrusion of corpuscles into the nerve substance, with its subsequent destruction, decay, and cavitation.

This is the condition to which the earliest descriptions lead up, and of the existence or future on-coming of which Dr. Dickinson, as it seems to me, was willing to accept a great variety of things as proof: large vessels, large spaces, post-mortem coagulation of blood, not only outside vessels but also in them, orange-coloured granular matter, the change unfortunately minutely described under the name of miliary degeneration and miliary sclerosis, and unusually large central canals, were all thrown into the group of glycosuric antecedents; as well as thick vessels and thick fibrous septa. Not that all of these things were seen in all cases—but some in one, some in another. And still I should ask, are they to be considered as satisfactory evidence of vessel engorgement and nerve-decay? As to arteries, do we not know that in Bright's disease it is common to find the arteries all over the body thickened? and do we therefore infer that the patient has undergone prolonged universal congestion? May not these thickened vessels be part of a general condition? And the same may be asked of vessels whose calibre is greater than the usual standard: may not this be a general condition peculiar to one individual, or to his time of life? We did not see, either in our own specimens, or in those of Dr. Dickinson —which he kindly allowed me to examine—anything that was certainly a varicose dilatation. A resemblance to varicose dilatation may easily arise in healthy vessels as a result of twisting in mounting, or from straight sections of curved vessels, or otherwise.

What evidence is afforded by a large central canal? The question of the formation of elongated cavities in the spinal cord is still *sub judice*, and it may be that an unusual size of the central canal is connected with it. But its relation to vascular dilatation is rather difficult to see; and surely there is another possible explanation of it, namely, that it is simply a congenital defect. The canal is formed by the union of the edges of the primitive groove, and is at first relatively large, and later on, to quote from 'Quain's Anatomy,' "is greatly narrowed, and subsequently, being more and more confined to the centre, it ultimately diminishes to a small tube." A check to this process would explain a large central canal, which, by the way, is by no means peculiar to diabetes. Dr. Dickinson himself has seen it in chorea, and I have

seen it in a case of hydrophobia; and I would submit that it has nothing to do with the origin of any one of the three disorders. Then we have the condition described as "miliary degeneration," of which we spoke reservedly in our description of the specimens, and which was then known to have been discovered in the cords of patients who had died from the most various diseases, even without the participation during life of the nervous centres. I am now quite convinced it is the result of the action of spirit; and the same view has the support of Dr. Savage, who read a paper on the subject at the International Medical Congress, and of others.

There remain the semi-crystalline bodies, which are spoken of as hæmatin, and the granular or gelatinous matter, which is regarded as the product of nervous decay. The former I do not think are even hæmatoidin. Their colour and their position of course suggest, perhaps even prove, their connection with the blood, but it is by no means clear that they have an *ante-mortem* origin.

Of the latter, also, I can only say that I fail to see the evidence on which an origin in decayed or degenerated nerve substance is based. From the examination of Dr. Dickinson's specimens I am prepared to say that in one of them upon which he relied, the gelatinous matter, is simply normal brain tissue, and from what we know actually of the conditions in diseases of an obviously destructive nature like myelitis and softening, it seems that the degenerative nature of this gelatinous material is quite unproven.

When this discussion arose Dr. Goodhart and myself were prepared to leave the matter to the judgment of other observers, but I regret that I have not since taken myself all the opportunities of examining into the question that I might have. But, so far as the cases occurring at Guy's Hospital are concerned, Dr. White has, at the meeting in April, given the Society the results of a naked-eye examination of twenty-three cases, which I may here remark have all died since the publication of our paper. In one of these cases I am able to confirm his results by microscopic examination, as well as by a more detailed examination of the hardened specimens with the naked eye; and I have examined two other cases in the same way, which were not included in his list.

I think I need not detail the cases. Suffice it to say that they were ordinary cases of diabetes. All died of coma. One had phthisis, the other three had no lesions of the viscera. The brain and spinal cord show no changes to which the disease can be

referred. In two cases they are perfectly normal; in the other two it is perhaps more difficult to say, since they have been spoilt by spirit, but the microscopic examination, combined with the naked-eye investigation, suffice for one to pronounce them free from the degenerative changes ascribed to such cords by Dr. Dickinson.

The second point to which my attention has been directed is the mode of death in diabetes. In seeing a number of cases, though, of course, perfectly aware that coma or some kind of unconsciousness was one method of termination, I was struck with the frequency with which patients died comatose, a frequency which seemed to me to be very much greater than was fairly represented by any published statements on the subject. Kussmaul had drawn attention to the peculiarities of the nervous symptoms in diabetes, and appeared to regard their occurrence as infrequent. I collected all the cases occurring at Guy's Hospital over a period of eight years, with the object of ascertaining as accurately as I could the proportion of cases in which this mode of death occurred. The results in forty-three cases were published by me in a paper in the last volume of the 'Guy's Hospital Reports.' I endeavoured to distinguish the following groups of cases:

Those dying from coma alone, with no visceral lesion or none competent to kill at the time: those dying from phthisis or pneumonia without coma: and those dying from coma, though already suffering from either active phthisis or pneumonia. And I made this division, because it was clear to me that we must go to the clinical phenomena as well as to the pathological conditions, in order to know the mode of dying.

To the cases I was then able to analyse I have added ten more that have occurred within the years 1881 and 1882, and the analysis gives the following result:

Coma.	No visceral lesions	17
	Visceral lesions inactive	8
	Visceral lesions active	10
	No *post-mortem*	8
		—33
Coma (diabetic?).—Renal disease		8
Pneumonia.—Coma doubtful		1
Coma absent.—No *post-mortem*		2
Phthisis, pneumonia, Bright's disease, peritonitis		14
		—
		58

This gives a very large proportion of comatose cases. Of the ten additional cases, seven died with coma, and all with the peculiar air-hunger which is the most striking feature in Kussmaul's description. I may say these ten cases are not all that occurred in 1881—1882, but all of which I can at present get the notes in order to properly classify them.

I went into the various causes and antecedents of this condition, so far as they could be gathered from the cases before me, and working on the forty-three cases first classified in relation to predisposing and exciting causes, I came to the following conclusions:—That death by coma occurred more frequently amongst the younger patients, that there was very little difference in relation to sex, and that, as regards the duration of the disease, a large number of cases were early cut short by the comatose termination, so that it seemed that the accident of coma was earlier met with than the onset of pneumonia or phthisis, but that nevertheless some cases died of coma after many years.

I have but little to contribute as to the immediate causation of the peculiar symptoms which have been ascribed by different observers to uræmia, acetonæmia, and fat embolism. What was obvious from these cases was that if any one of these conditions was occasionally the cause, it certainly was not in all. In two cases only of the forty-three was a milky condition of the blood described, while in a certain number the blood was healthy to the naked eye and to the microscope. Three which were examined for fat embolism gave no result.

The subject of acetonæmia has not, perhaps, been so thoroughly investigated as it might have been, but certainly no positive result has come under my notice. In many cases the fragrant odour has been absent, and in two cases at least chemical research by Dr. Stevenson failed to detect acetone in the viscera.

Judging from these cases, and from the literature of the subject so far as I am familiar with it, I think that the comatose termination of diabetes is a toxæmic condition; that it is not due to fatty embolism, and certainly not to structural lesions of the nervous system.

I may here remark on one peculiar symptom which is generally quite early in the development of the condition, which is very frequent, and which may give rise to difficulties in diagnosis. I mean pain in the abdomen. Of the forty-three cases first analysed, sixteen had it; in two it was so severe as to suggest perforation;

in one case I was asked by the house physician to see the case, under the impression that something of the kind had occurred, but knowing my patient I suspected what was to occur, and the event soon showed that mine was the correct view. Amongst the seven cases that have recently occurred, two at least have had it, one complaining of pain at the lower border of the ribs on the right side; another is reported by the clerk to have been "admitted for pain in the abdomen;" in a third case tenderness in the abdomen was obvious during the semi-coma, and here the abdominal aorta was pulsating violently; another patient was said by his wife to have had sinking pain in the epigastrium for six weeks. In two cases suffering from pain *post-mortem* intussusceptions of the intestine were found, and in another case dying from coma several intussusceptions were found, but he was not in a condition to give any history, and it is not known whether he had any pain preceding the coma.

The condition of the pancreas has been frequently commented on in relation to diabetes, and I take this opportunity of mentioning what has been found in the organ within the last few years amongst the cases dying at Guy's Hospital. Of forty-six cases occurring in the years 1873—1882 inclusive the condition of the pancreas is not specially mentioned in the majority, and it may be assumed that there was nothing remarkably wrong with it. In five cases it is specially described as healthy, and in only five is any note made of an altered condition.

Alfred S—, aged 40, was admitted in 1880. He was taken suddenly ill, became comatose, and died. In the heart was a peculiar clot, the upper surface milky white and of creamy consistence. Quite unlike ordinary fibrinous clot, its lower surface was soft, and much resembled raspberry cream. The pancreas presented a peculiar appearance; it was rather larger than usual; on its surface, and also scattered about the gland between the lobules, was a milky-white, fatty-looking material, as it were, smeared over it. This appearance extended into all the adjacent fat, notably into the transverse fissure of the liver, and into the upper part of the mesentery; it presented the appearance of the matter seen in atheroma.

In 1881 a case of diabetes occurred in which the pancreas was described as small and fatty. The patient had phthisis, pleuritic effusion, and granular kidneys. Another case had a rather small, but otherwise healthy pancreas. Death resulted from destructive

This gives a very large proportion of comatose cases. Of the ten additional cases, seven died with coma, and all with the peculiar air-hunger which is the most striking feature in Kussmaul's description. I may say these ten cases are not all that occurred in 1881—1882, but all of which I can at present get the notes in order to properly classify them.

I went into the various causes and antecedents of this condition, so far as they could be gathered from the cases before me, and working on the forty-three cases first classified in relation to predisposing and exciting causes, I came to the following conclusions:—That death by coma occurred more frequently amongst the younger patients, that there was very little difference in relation to sex, and that, as regards the duration of the disease, a large number of cases were early cut short by the comatose termination, so that it seemed that the accident of coma was earlier met with than the onset of pneumonia or phthisis, but that nevertheless some cases died of coma after many years.

I have but little to contribute as to the immediate causation of the peculiar symptoms which have been ascribed by different observers to uræmia, acetonæmia, and fat embolism. What was obvious from these cases was that if any one of these conditions was occasionally the cause, it certainly was not in all. In two cases only of the forty-three was a milk[illegible] of the blood described, while in a certain number the bl[illegible]lthy to the naked eye and to the microscope. Three [illegible]amined for fat embolism gave n[illegible]

The su[illegible]tonæmia [illegible]aps, been so thoroughly investig[illegible]ght hav[illegible]rtainly no positive result has co[illegible] notice. [illegible]es the fragrant odour has been [illegible]wo [illegible] chemical research by Dr. Ste[illegible] viscera.

[illegible] the literature of the subject so[illegible]hat the comatose termination o[illegible]at it is not due to fatty embo-li[illegible] lesions of the nervous system [illegible] symptom which is gen[illegible] condition, which [illegible] difficulties in [illegible]

in one case I was asked by the house physi[illegible] under the impression that something of the kind [illegible] knowing my patient I suspected what was to [illegible] soon showed that mine was the correct view. [illegible] cases that have recently occurred, two at [illegible] complaining of pain at the lower border of the [illegible] another is reported by the clerk to have been [illegible] in the abdomen;" in a third case tenderness [illegible] obvious during the semi-coma, and here the [illegible] sating violently; another patient was said [illegible] sinking pain in the epigastrium for six weeks [illegible] from pain *post-mortem* intussusceptions of the [illegible] and in another case dying from coma [illegible] found, but he was not in a condition to [illegible] not known whether he had any pain [illegible]

The condition of the pancreas has been [illegible] in relation to diabetes, and I take this [illegible] what has been found in the organ [illegible] the cases dying at Guy's Hospital [illegible] the years 1873—1882 inclusive the [illegible] specially mentioned in the [illegible] there was nothing remarkably [illegible] special[illegible]ibed as healthy, [illegible] an a[illegible]ion.

A[illegible]d 40, was admitted [illegible] den[illegible] comatose, and [illegible] clo[illegible] surface milky [illegible] Qu[illegible]inary fibrinous [illegible] m[illegible] raspberry [illegible] li[illegible] it was [illegible] a[illegible]ed about the [illegible] [illegible]oking [illegible] [illegible]ended [illegible] [illegible]

[illegible] e
[illegible]e
[illegible]nd
[illegible] of
[illegible]hort
[illegible] and
[illegible] The
[illegible]ed the
[illegible] but at
[illegible]isease or
[illegible]gs were in
[illegible] spleen was
[illegible] substance
[illegible]r, was noted
[illegible]*us scriptorius*
[illegible] and was of a
[illegible]around and im-
[illegible]e vascular than

[illegible]ttention presented
[illegible] patient was a girl,
[illegible]f a charwoman, and
[illegible]n on December 8th,
[illegible]d, nor any account of
[illegible] well for twelve months.
[illegible]d drowsy, but restl[illegible]

pneumonia, with ulceration of the larynx and bowels, abscess of the liver, and tubercle of the kidneys and prostate.

A third case, in the same year, died with caseous pneumonia, and the pancreas is thus described: "It at once attracted attention by its want of firmness and want of sharpness of outline; its capsule was thick and opaque, so that the gland looked like one enclosed in a bag, instead of showing its lobulation distinctly. It was very soft, and on section seemed to be nothing more than a lump of fat. The ordinary pancreatic lobulation was quite gone." Of this pancreas I have placed a specimen under the microscope. The section is almost entirely adipose tissue, through which small portions of pancreatic gland tissue, measuring from $\frac{1}{30}$th inch to $\frac{1}{20}$th inch in section, are irregularly scattered.

Recently, in 1882, a case has died of pneumonia in which the pancreas is described as yellow and fatty.

These facts are, of course, too few and too scanty in detail to draw any conclusions from, but they suggest the desirability of a careful examination of this organ in all fatal cases of diabetes.

Dr. Dawson Williams.—By the kind permission of the physicians I have been able to make an examination of the records of University College Hospital for the last ten years, but the amount of material thus placed at my disposal is very limited. In looking through the cases I have been impressed by the considerable proportion which the cases among young people bore to the whole, and to these I shall chiefly confine my notes. The three following cases appeared worthy of special note:

Case 1.—Ernest S—, aged 17, a pupil teacher, and working very hard in that employment, was admitted on November 1st, 1879, under the care of Dr. Bastian. It is stated that his father had suffered from fistula in ano, that his mother had a "tumour," and that of their five children only one other son had survived. The patient had whooping-cough when six years old, and scarlet fever when thirteen years old. He seems to have been in his usual health (he was never very robust) up to a month before admission, when, according to his own account he caught cold, and began to lose flesh and to grow weaker. He had only noticed any increase in the quantity of urine passed for about a fortnight, and for this period only had he been troubled by thirst, hunger, and pain in the loins. When admitted he weighed 7 st. 2 lbs.; eighteen months earlier his

weight had been 9 st. 4 lbs. He was free from dyspnœa or any signs or symptoms of disease of the lungs or heart; he passed urine very frequently—every forty minutes, he said. The administration of opium had no effect in diminishing the quantity of water passed, but, on the contrary, appeared to cause an increase, so that on one day the quantity reached 197 fluid ounces; the average quantity of sugar to the ounce of urine while he was taking opium was 37·6. On November 25th a restricted diet was ordered, and this was still further limited on the 29th. Under this treatment the quantity of sugar gradually declined, and the quantity of urine fell to 82 fluid ounces; but the patient got worse. On December 4th he complained of great languor; on the 7th, in addition to this, of loss of appetite. On the 11th, the bowels having been confined for some days, a simple enema was ordered; while at stool, half an hour later, a violent pain in the abdomen suddenly came on. The abdomen was found to have become tender; he passed a bad night, vomiting several times, and his face grew pinched and haggard. During the afternoon of the 12th he grew rapidly worse, his breathing became "short and quick," the pulse imperceptible; he became more and more deeply unconscious, and died at 10 a.m. on the 13th. The concluding symptoms in the case appear to have suggested the occurrence of perforation of the intestine or of peritonitis; but at the *post-mortem* examination there were no signs of any disease or injury of the peritoneum. The lower lobes of both lungs were in a condition of recent uniform catarrhal pneumonia; the spleen was hard and tough; the liver was also tough and its substance thickened. The most remarkable appearance, however, was noted in the medulla oblongata; at the tip of the *calamus scriptorius* the surface was slightly raised in an ovoid shape, and was of a pinkish colour; the membranes of the medulla, around and immediately below this point, were decidedly more vascular than natural.

The second case to which I wish to direct attention presented some points of resemblance to the above. The patient was a girl, Jane E—, aged 15. She was the daughter of a charwoman, and was admitted under the care of Dr. Bastian on December 8th, 1881. No family history could be obtained, nor any account of her own illness beyond that she had not been well for twelve months. When admitted she was dull, listless, and drowsy, but restless.

The face was slightly cyanosed, and she complained of dull pain in the occipital region. There was no dyspnœa, nor any symptoms or signs of disease of the thoracic organs. She was intensely thirsty. In the first twenty hours she passed 198 fluid ounces of urine of sp. gr. 1034, and containing 29·1 gr. sugar to the ounce; in the following twenty-four hours she passed 223 fluid ounces of sp. gr. 1033, and containing 23 gr. sugar to the ounce; in the next twelve hours she passed 76 fluid ounces of urine, sp. gr. 1032, and containing 24·3 gr. sugar to the ounce; it also contained on this day one tenth albumen. After admission her drowsiness rapidly increased. On the 10th she was ordered a restricted diet, and was that evening given a simple enema; this was followed by a large motion at 9 p.m. Immediately after this—apparently while using the bed-pan—she began to breathe rapidly; at 10.40 p.m. she was breathing 42 in the minute; hands and feet were cold, and the pulse was small, weak, and compressible; forty minutes later she had become unconscious, and her breathing had become fuller and quieter; no urine was passed after 9 p.m.; no complaint was made of thirst; and at 6.45 a.m., or nine hours and three quarters after the passage of the large stool, she died. Temperature, on December 10th, 7 a.m., 98° F.; 3 p.m., 97·4° F.; 7 p.m., 97·2° F.; midnight, 96·1° (pulse 148, respiration 44). On the 11th, 3 a.m. 97·2° F.; 6.45 a.m., 100·2° F. Five minutes after death the temperature in the axilla was 100° F.

The *post-mortem* notes recorded the following facts: Heart small; right ventricle covered with fat; right side of heart contains semi-fluid clot mixed with some bubbles of gas, odourless; small patch of atheroma (near septum) on mitral valve; muscular substance of left ventricle pale and tough; fatty degeneration of lining membrane of aorta just above sinus Valsalva. No signs of consolidation or of old cicatrices in lungs, but marked emphysema of lower lobes and lower part of upper lobes; substance tough. Kidneys weighed 4 ounces each; capsules strip off easily; surface pale, mottled, with distended vessels; extreme pallor of cortical and interpyramidal substance; pyramids in right kidney very dark. Spleen 2 ounces, small, and bloodless. Liver medium size; substance tougher than natural; capsule not thick. Uterus very small. Dura mater unduly adherent to calvaria; unusual number of branches of the meningeal arteries visible; tentorium more vascular than natural. Brain not compressed, more consistent

than natural; excessive number of puncta cruenta, and grey matter too red. No coarse pathological change.

I have reported these two cases at length, because they agree with certain cases described, on the same evening, by Dr. Frederick Taylor, in that death somewhat rapidly followed the sudden emptying of the bowels, which had contained a large quantity of fæces. With regard to this, I shall not attempt any elaborate speculation for the facts are too few and too slender to support a hypothesis but would merely observe that the effect of suddenly emptying the abdomen, whether of fæces or of fluid, is frequently, as is well known, to bring about a marked tendency to dangerous syncope, probably from the great increase in the vascular capacity, or at least in the vascular contents, of the chylo-poietic system. There was, it is true, no definite syncope in either of these two cases; but in view of the theory advanced by Dr. Pavy, namely, that diabetes actually depends on a vasomotor paralysis affecting the chylo-poietic system, the rapid termination of these cases under a condition which is believed to tend to bring about such paralysis, or at least such over-distension of the vessels of the chylo-poietic system, or to aggravate it if it be present, appears to be worthy of note, and may serve, if not to throw light on the pathology of diabetes, at least to act as a warning in practice.

Case 3.—The youngest patient whose death I find recorded, was a girl aged 11 years; symptoms of diabetes had been present for about 18 months, but they only became urgent about three weeks before death, when she began to complain of languor, headache, and pain in the left shoulder, and the thirst became intolerable. When admitted she was already suffering from dyspnœa and orthopnœa, the accessory muscles of respiration were working, and she was slightly cyanosed. The pulse was 180, small and compressible; the respirations were 36. She had phthisis, chiefly of the left apex. During the first twenty-four hours after admission she passed 190 fl. oz. of very pale urine, at frequent intervals; sp. gr. 1035°, faintly acid; no albumen; sugar, ·46 per cent. She was at first very restless, but gradually became more dull and heavy, and the cyanosis increased. On the morning of the third day she became semi-comatose; about 6.30 p.m. that day she became suddenly excessively cyanosed and died. At the autopsy, the vessels of the pia mater were much injected; and on section of the brain, the puncta cruenta appeared to be four or five times more numerous

than natural. The vessels of the corpus striatum and cerebellum were also much injected; the apex of the left lung contained a vomica, and the lower part of the lobe was in a condition of catarrhal pneumonia; at the apex of the right lung was a large patch of yellow softened tissue, surrounded by a dense capsule of fibroid tissue.

The three following cases occurred in young women:

Case 4.—Jane W—, domestic servant, aged 21. The symptoms —thirst, frequent micturition, constipation, swollen gums, dimness of sight, and general weakness—were said to have come on suddenly nine weeks before her death. Nineteen days before her death, and while on skim-milk diet, a trace of albumen appeared in the urine; it disappeared in about five days, but recurred two days before death. While she was on a skim-milk diet (18 days) the quantity of urine and of sugar at first decreased, but subsequently increased, reaching on the 17th day the enormous quantity of 241 fl. oz. of urine, with 62·66 gr. of sugar. After this she was put on a restricted diet (meat, gluten, and eggs); the amount of urine fell to about 85 fl. oz., and of sugar to about 1300 gr.; but she grew rapidly worse, vomiting and retching became troublesome, and appetite failed. On the third day of strict diet she began to be dull and apathetic; in the evening she was in a stupor, breathing heavily, with a pulse of 120 to 130, and temperature between 96° F. and 97° F. (in the rectum scarcely over 97° F.); the stupor gradually deepened, the pulse became more and more rapid, the breathing heavier, and she died about forty-eight hours after the symptoms of coma were first noticed. During the last thirty-six hours no urine was passed, and only about 14 fl. oz. could be drawn off by the catheter. At the autopsy (nine hours after death) the brain was firm and healthy in appearance, except that, in the optic thalamus (most markedly on the right side), in the lower part of the pons, on the right, and over a large area in the floor of the fourth ventricle, the spaces through which the vessels passed were larger than usual. The lungs were free from disease, but there were a few old pleural adhesions. The abdominal organs presented nothing unusual.

Case 5.—Annie W—, housemaid, aged 23; mother died of phthisis; patient had symptoms of phthisis for about five months; for two months she had micturated frequently, passing large quantities of urine; for six weeks thirst, hunger, and constipation had

been distressing symptoms, and for one month sight had failed, so that she could with difficulty read medium print. On the second day after admission she passed 102 fl. oz. of urine, containing about 18 gr. sugar to the ounce, and a trace of albumen. On the evening of this day she had a sudden attack of shortness of breath, the respirations being heavy and sighing; the dyspnœa passed off, but the sighing breathing remained; she was intensely restless all night. Early on the morning of the third day she became semi-comatose; the urine contained albumen, $\frac{1}{8}$, and granular casts; at 11 a.m. the face had become livid, and covered with perspiration, the fingers purple, the feet cold, and the breathing laboured: she died at 2 p.m. The temperature was never higher than 98·4°. At the autopsy, the brain and its vessels appeared natural, except that the pia matral vessels were injected. The right lung contained a small mass of "gelatinous, slightly pigmented, racemose tubercle" at the apex; the left, at the apex, a small cavity, with indurated walls and cheesy pus; in the neighbourhood, some "small grey nodules (? tubercle)." *Kidneys.*—Right, 4½ oz., capsule strips without much difficulty; numerous small cysts on the surface, some with gelatinous, some with liquid contents; no granulations; retraction at two points on the surface; opposite the bases of the pyramids the average thickness of the cortex was a quarter of an inch, cortex buff coloured. Left, numerous contracted areas on the surface, no granulations, cortex smaller and Malpighian bodies more crowded than in the other kidney.

Case 6.—Emma H—, domestic servant, aged 23. Mother died of phthisis. Weakly child; abscesses in the neck and foot (9—11 years of age). Typhus fever at age of 15. Weakness, dryness of skin, and emaciation for eighteen months before her admission (under Sir William Jenner). For twelve months she had suffered from severe thirst, ravening hunger, and had passed large quantities of urine. Sight had failed, so that she could not see. She was extremely emaciated; the skin was dry as a rule, but towards the end of her life she sweated occasionally. Twenty-seven days before death she had a severe attack of dyspnœa, which did not recur, though during the forty-five days she was in hospital the respiration rate rose from an average of 20 to an average of 30. The emaciation and weakness rapidly increased, and she died of exhaustion. The phthisis appeared to extend, but to the last to be confined to the left side. Temperature first week—

Maximum—Morning, 100° F.; Evening, 102° F.
Minimum— „ 99·2° F.; „ 100° F.

Last week—

Maximum—Morning, 99° F.; Evening, 101·2° F.
Minimum— „ 97·8° F.; „ 98·4° F.

She was treated for about a month by a skim-milk diet. The average quantity of urine she passed before this was 120 fl. oz., and on one of these days she passed 3456 grains of sugar. While on the skim-milk diet the quantity of urine averaged about 82 fl. oz., and the sugar fell to 1440 grains in the first week, and to 364 grains at the end of a fortnight. On account of diarrhœa, loss of flesh, and increasing exhaustion, the diet had to be abandoned ten days before her death.

Autopsy.—Brain healthy, so far as could be judged by the naked eye. Heart 4·5 oz.; atheroma of aortic cusp of mitral; "heart substance if anything a little firmer than natural." Lungs: right, two small cavities at apex. Left adherent throughout; whole upper lobe, except at extreme apex, where was some cheesy matter, was one vast cavity with thickened pleura for walls, and traversed by trabeculæ; the lower lobe contained one small cavity, several racemose masses breaking down, and at the posterior base granulations, some white and cheesy, a few transparent. Kidneys: right healthy; left, in the centre a pale patch the size of a shilling, containing two small cheesy masses. Large intestines: mucous membrane, from cæcum to sigmoid, thickened, purplish, with numerous small ulcers one sixth of an inch in diameter.

Among the cases occurring in persons past the grand climacteric, the only one to which I propose to refer was that of a woman, Caroline M—, aged 59, who was admitted on September 26th, 1879, under the care of Mr. John Marshall, F.R.S., who has allowed me to record the case. The patient had been kicked violently on the left leg about two months before admission; the part was much bruised, but the skin was not broken. The great toe "festered," and a month later the ankle swelled, and some ulcers formed; these ulcers began as "little pin-like points," and were painful from the first. She had long suffered from varicose veins. When admitted she had two ulcers on the inner aspect of the leg near the ankle, two which covered the dorsum of the foot, and one on the outer side of the first metatarsal bone; the floor of the ulcers was covered with a greyish-black adherent slough; the edges were raised

and surrounded by a zone of reddened and tender skin. The ulcers under local treatment began to heal. She was passing about 100 fl. oz. of urine a day, which contained 24 grains of sugar to the ounce. On October 14th the ulcers became offensive and began to extend, and in front, just above the ankle-joint, was a patch of gangrene. On October 15th the gangrene had extended; where extending it was covered by transparent cuticle, but on the older part there were blebs; the margin of the gangrene was well defined, the skin beyond was dusky red and œdematous, as was the whole of the foot. On October 16th the leg was amputated with antiseptic precautions. Although Esmarch's bandage was used, a good deal of blood was lost. A few hours after the operation the stump began to bleed again; three arteries were secured, but there was general oozing, and the blood did not appear to coagulate. On October 17th the patient was wandering, and there was a slight blush on the stump; at 4.45 p.m. the hæmorrhage recurred, and at 6 p.m. she died, about twenty-eight hours after operation.

Temperature.

October 11th,	noon.	100·2°	October 14th, 7	p.m.	101·6°
8	p.m.	101°	„ 15th, 11.30	a.m.	99·4°
„ 12th, 11	a.m.	99·4°	7	p.m.	96°
7	p.m.	101°	11	p.m.	99·4°
„ 13th, 8	p.m.	101·2°	„ 16th, 7	a.m.	99°
„ 14th, 11	a.m.	103°	11.30	a.m.	98·4°

At the autopsy the body was noticed to be very fat. The wound showed hardly any lymph—a mere trace round the bone. Lungs emphysematous; no pneumonia, but collapse and patches of œdema posteriorly. Heart covered with fat, and generally fatty and friable; left ventricle hypertrophied, extremely friable and pale; aortic valves and root of aorta atheromatous. Gall-bladder full of calculi, adherent to colon. Liver pale and friable, contained three patches of (apparently) extravasated blood. Kidneys: left 6 oz., right 5 oz.; surfaces uneven and cortex shallow. All abdominal organs anæmic. Inguinal glands over left femoral vessels appeared bruised and congested; femoral artery healthy, containing a large delicate clot; a similar clot in the artery of the opposite side. Surface of brain anæmic; subarachnoid œdema.

This patient had been in the hospital from April 9th to May 14th, 1877, on account of a varicose ulcer. She had then only noticed

that she had been passing an increased quantity of urine for six weeks. The average quantity of urine passed during twenty days was 67 oz., and the average quantity of sugar was less than 12 grains to the ounce.

Since the attention of members of this Society has been specially directed to the subject of diabetes, by the issue of the circular which invited contributions to this discussion, I have heard frequent expressions of surprise at the comparative rarity with which cases of diabetes are met with in the records of the various hospitals. This applies of course to cases which terminate fatally, as the same case frequently enters the hospital several times, and a large number under treatment improve rapidly and are shortly lost sight of. In reply to a question which I addressed to him, Dr. William Ogle courteously informed me that in the Reports of the Registrar-General the term "diabetes" means only diabetes mellitus, and that when a death is registered as due to "diabetes," without further addition, it is assumed that the disease meant was diabetes mellitus. There can, I imagine, be little doubt that this assumption leads to a correct result. It would appear, from a table published in these Reports, that diabetes is not so rare as a cause of death as purpura, aneurism, pericarditis, or small-pox, and that it is only a little less frequent than hernia and pleurisy.

The Reports of the Registrar-General afford evidence on another point, the value of which will be variously estimated, but the importance of which cannot be wholly denied. A careful examination would seem to show that diabetes is becoming year by year a more common disease. Taking the total number of deaths from all causes, they were 436,566 in 1862, and 528,624 in 1880—that is to say, the number of deaths from all causes in 1880 was about one fifth greater than in 1862. The deaths attributed to diabetes show a very different relation; they were 537 in 1862, and 1059 in 1880—that is to say, the deaths from diabetes in 1880 were nearly twice as numerous as in 1862. The following table, abstracted from a Table (No. 34) in the Registrar-General's Report for 1879, shows the mean annual rate of mortality in England during the thirty years, 1850–79, and in each quinquenniad, from all causes, and from diabetes. I have added the rates for nervous diseases, because they show no relation to the increase in the rates for diabetes; and the rates for urinary diseases, because they do show a very close

relation, having been for the last twenty years very nearly as ten to one.

TABLE I.—*Mean Annual Rate of Mortality in England. Annual Deaths to* 1,000,000 *Living.*

Years	1850 to 1854.	1855 to 1859.	1860 to 1864.	1865 to 1869.	1870 to 1874.	1875 to 1879.	Average. 1850 to 1879.
Deaths from all causes . .	22,299	22,052	22,248	22,760	22,019	21,250	22,105
„ „ Nervous Diseases .	2,777	2,758	2,823	2,859	2,817	2,812	2,808
„ „ Urinary Diseases .	190·6	227·	270·6	320·2	352·2	420·	296·9
„ „ Diabetes . .	23·	24·8	28·4	32·2	35·2	40·6	30·7
„ „ Gout	12·4	13·2	13·4	18·2	20·8	25·6	17·3

An examination of each year separately shows that, with very few exceptions, the death-rate from diabetes has steadily risen year by year from 24 per million in 1850 to 42 per million in 1879, and 41 per million in 1880. I may remark in passing that the death-rate from nervous diseases in 1880 was lower than it had been for a quarter of a century.

An examination of the Tables published by the Registrar-General showing the proportional number of deaths in a million deaths, shows a similar steady increase in the proportion that deaths due to diabetes bear to deaths from all causes. In 1862 the proportion of deaths from diabetes was 1329, in 1880 it was 2008, or an increase of about a third.

Another point upon which the Registrar-General's return can afford some information, is the age at which deaths from diabetes most commonly occur, and the relative proportion of deaths at each age. Dr. Dickinson, in his valuable work on 'Diabetes,' has compiled a table from the Registrar-General's Reports for the ten years 1861 to 1870. I have drawn up a similar table (Table III) for the succeeding decade. For the sake of easy reference, I reproduce Dr. Dickinson's table (Table II).[1]

[1] One slight alteration was necessary.

TABLE II.—*Dickinson*, 1861—1870.

Age.	Males.	Females.	Total.
Under 1 year	4	4	8
„ 1 „	10	9	19
„ 2 years	12	4	16
„ 3 „	7	8	15
„ 4 „	8	8	16
Total under 5 years	41	33	74
From 5 to 10 years	62	52	114
„ 10 „ 15 „	113	87	200
„ 15 „ 20 „	221	131	352
„ 20 „ 25 „	222	141	363
„ 25 „ 35 „	651	368	1019
„ 35 „ 45 „	653	384	1037
„ 45 „ 55 „	746	352	1098
„ 55 „ 65 „	817	377	1194
„ 65 „ 75 „	594	236	830
„ 75 „ 85 „	146	55	201
„ 85 „ 95 „	7	7	14
Totals	4273	2223	6496

TABLE III.—1871—1880.

Age.	Males.	Females.	Total.
Under 1 year	3	1	4
„ 1 „	6	4	10
„ 2 years	4	5	9
„ 3 „	5	9	14
„ 4 „	5	6	11
Total under 5 years	23	25	48
From 5 to 10 years	65	54	119
„ 10 „ 15 „	134	133	267
„ 15 „ 20 „	284	171	455
„ 20 „ 25 „	348	201	549
„ 25 „ 35 „	816	502	1318
„ 35 „ 45 „	906	494	1400
„ 45 „ 55 „	954	547	1501
„ 55 „ 65 „	1236	660	1896
„ 65 „ 75 „	922	464	1386
„ 75 „ 85 „	229	121	350
„ 85 „ 95 „	12	2	14
Totals	5929	3374	9303

DESCRIPTION OF PLATE XXV.

Charts showing the Ages of Deaths from Diabetes. Dr. Dawson Williams. **(Page 385.)**

Chart shewing the ages (in decades) at which deaths from Diabetes occur, based on the totals for the ten years 1861 to 1870.

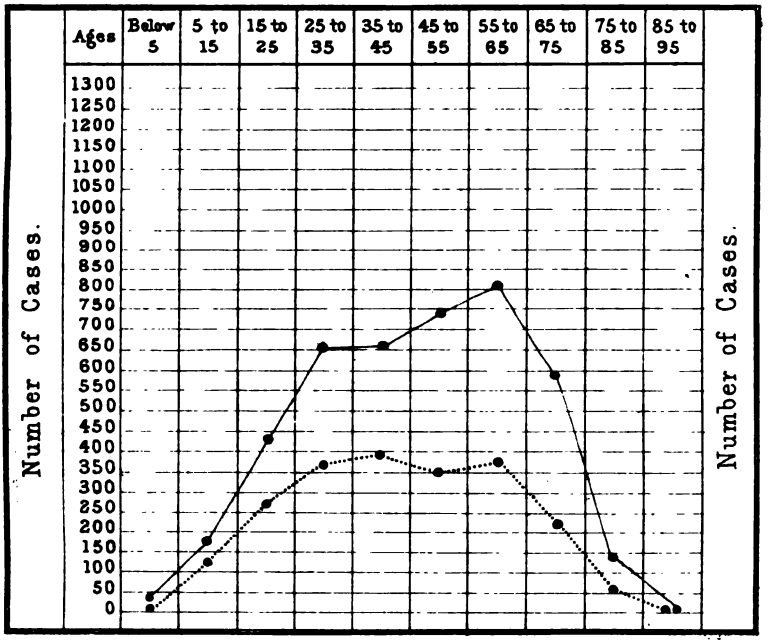

Chart shewing the ages (in decades) at which deaths from Diabetes occur, based on the totals for the ten years 1871 to 1880.

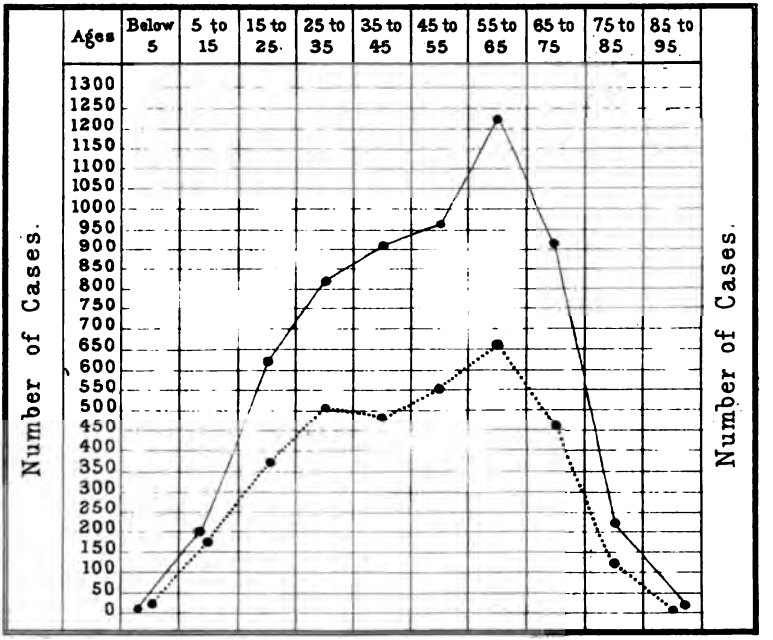

These two tables present, as it seems to me, a very noteworthy correspondence. This is best shown by the charts, which it will be seen very closely correspond in form (Plate XXV). The chief point of difference is the disproportional increase in the number of males in the decade, 35 to 45. In the second period (1871-80) the form of the curve for females approaches that for males still more nearly than it did in the first period (1861-70); the maximum for the two sexes occurs in the same decade, 55—65, and there is no disproportional increase among females during the child-bearing period.

It appears to me that evidence of this kind ought not to be neglected, since it offers corroborative evidence as to the distinct nature of diabetes as a disease. Whether diabetes possesses a constant anatomical substratum, or whether it is a derangement of function, it has been abundantly shown to be a disease with definite symptoms, a definite course, and a definite and constant incidence both as regards age and sex.

In a valuable and exhaustive paper, contributed to the 'Transactions of the Obstetrical Society,' Dr. Mathews Duncan has brought together thirty-seven cases of diabetes occurring in connection with childbirth; and his contention appears to be that in rare instances there is a certain obscure, and hitherto unrecognised, causal connection between the two. I merely refer to this to point out that diabetes, has up to the present time, been a disease which has very seldom been registered as a cause of death in relation to childbirth, or within a month after childbirth. In the ten years from 1870 to 1879, only six cases of diabetes were registered as occurring in women dying within one month after childbirth. Of these deaths four occurred in women between the ages of 35 and 45, and two in women between the ages of 25 and 35.

Dr. Dickinson.—I will not delay to notice in detail the observations of the last speaker, Dr. Frederick Taylor. I may, however, observe in passing that with regard to two conditions which he charges me with asserting as causes of diabetes, namely, dilatation of the central canal of the cord and the so-called "miliary sclerosis," the fact is that I most carefully guarded myself from any inference of the kind. I described dilatation of the cord in two case of diabetes only, and while inferring from them that the cord was not healthy, I expressly stated that this condition was exceptional. As to miliary sclerosis, I described its occurrence in several

diabetic bodies, because I wished to tell the whole story; but far from attaching importance to this in relation to diabetes, I have expressly insisted that the concurrence is accidental (see my work on 'Diabetes,' Description of Plate 3), and have elsewhere expressed my belief that it is often due to *post-mortem* change ('Lancet,' February 2nd, 1878, p. 161).

Dr. Taylor tells us that he examined some preparations of mine which had become the subjects of discussion, and found, as I understood, nothing morbid about them. His criticism would have had more force had he looked at the preparations before stating his opinion. Neither in these on the table to-night does he find anything indicating disease. But I cannot help thinking that the existence of blood in conspicuous amount outside its proper vessels is, to say the least, a condition which can scarcely be regarded as compatible with health.

But without further following any remarks which have fallen from different speakers adverse to my own observations, I judge that I shall best save the time of the Society, and supply the best answer, if one be possible, to much that has been said, by briefly recounting my own results.

I think it may be fairly presumed at the outset, or accepted as a postulate, that diabetes is not a disease without a pathology. If it were so it would not come within the objects of this Society. I presume that it is an organic disease, that it depends on change in the permanent structures, since it persists as it does notwithstanding that all outer circumstances, food, climate, and physic are subjected to every conceivable variation. That a disease so tenacious, so regular in its consequences, and so fatal, should be merely functional is an idea which I for one am unable to entertain. Whether we have yet found the essential change or not, I cannot doubt that it exists.

I have examined a large number of diabetic subjects with more or less comprehensiveness, and I may honestly say with much labour and care. I have recently examined four for the purposes of this Society with results—many of which are represented by preparations on the table—which, as regards the brain, are strongly confirmatory of what had been arrived at previously. In these I made it my particular business to examine the sympathetic, with results which I shall presently state.

I set to work originally with a very wide scope, examining with

the microscope almost every structure I could think of, without any particular bias as to the result. My attention was soon drawn to the brain as giving the best promise. The earliest observations were made many years ago, when the pathology of the nervous centres was a novel inquiry, and I am free to confess that, notwithstanding all the care I could exercise, I did not always allow sufficiently for the variations which the cavities and channels of the brain present independently of special cerebral disease; and I think that some exaggerations or misconceptions which had this origin may have tended to cast doubt more widely than it was deserved.

I will address myself first to the question as to whether pathological changes of any sort are associated with diabetes; and, secondly, if there be any, what may be their bearing and significance.

As to the first, I will take the organs in succession, so far as I have given attention to them, and begin with the brain. This to rough examination generally passes as natural, though it is generally hard in texture, often injected, and more rarely marked with extravasated blood on the surface. On section pores in cribriform arrangement, which are exaggerations of the ordinary puncta vasculosa, are often conspicuous in the centrum ovale, and white matter underneath the lateral ventricles. The most characteristic sections are obtained from parts in which this peculiarity has been observed.

The appearances which are declared by the microscope are chiefly four:

1. Dilatation of the blood-vessels.

2. Extravasation of blood in small amounts, probably rather by transudation than rupture.

3. Enlargement of the perivascular spaces.

4. Alterations in the perivascular sheaths and nervous matter bounding the cavities.

As to the first, I have displayed some of the many instances in which portions of blood-vessels, chiefly arterial, have been notably dilated for short lengths, though as a morbid change this is less conspicuous than what is to be presently mentioned. I have seen this in the dentate body of the medulla and elsewhere.

Next comes a less equivocal result of morbid change. The spaces around the blood-vessels often contain such quantities of

blood pigment in large grains or conglomerations as to be fairly presumed to be morbid, and in some instances extravasated blood in corpuscular shape has been found; this has been seen in the deeper perivascular canals, in the pia mater at the sides, and in the median line, of the medulla oblongata, and in the central brain tissue, the most marked instance of which was in the pons about the median line. In fifteen diabetic brains I found extravasated blood in seven, specimens from several of which are here tonight.

I think that any one who will look at the considerable quantities of blood, speaking microscopically, which lie outside the blood-vessels in the spaces around them, or intruded into the cerebral substance, must acknowledge that the change is morbid, definite, and even striking. It was best shown about the large vessels under the corpora striata, in the pons, and in the pia mater, especially that in connection with the medulla. In some cases the blood corpuscles retained their outline; in others, the blood apparently longer effused was recognisable only by its colour.

Perivascular changes have been invariably found — thickening of the sheath, erosion, or degeneration of the circumjacent nervous substance. The most marked instances have been found where the vessels and spaces are naturally the largest, between the corpus striatum and the base of the brain, about the pons and medulla, and in the white matter between the upper part of the brain and the ventricles. The cavities are often super abundantly sprinkled with grains of blood pigment, and in many cases the bordering nervous matter is rendered transparent and gelatinous by some degenerative change akin to solution. An alteration which is early appreciable, not only by the naked eye, but in the recent state, in the cribriform enlargement of the perivascular channels of the white matter of the centrum ovale. This, though not peculiar to diabetes, for it has been found in chronic insanity, is often noticed as a diabetic lesion. I have specimens here to-night from four cases. The enlarged canals which constitute the holes are usually abundantly spotted with blood pigment, while the arterial sheaths are thickened.

The cord is seldom or never quite natural, though the evidences of morbid change are less striking than in the brain. Erosions are often seen at the base of the anterior fissure. In a few cases the grey matter of the horns has been rendered translucent by a sort of incipient sclerosis. Perhaps the most striking morbid change which

the cord has been found to present is dilatation of the canal, which, however, is exceptional, since it was observed but in two cases. I may add that spots of degeneration or *post-mortem* change, to which the name of miliary sclerosis has sometimes been applied, were found in many cases, both in the brain and cord; but regarding this change as not certainly morbid, I have said nothing about it.

With regard to the sympathetic system, I must confess to having spent some labour in vain. I have examined most of the chief divisions repeatedly: the prevertebral cord, with especial reference to the ganglia, in the cervical and dorsal regions, in five cases, the intervertebral ganglia in four cases, and the semilunar ganglia in four cases. The result of comparison with healthy structures has been to show that these parts of the nervous system are generally healthy in diabetes. I found in one case a very decided granular degeneration of the cells in the cervical ganglia, to which importance must have been attached had a similar change been found in other cases—the specimen is upon the table—and a lesser degree of the same change once in the semilunar ganglion.

With regard to other organs I need say but little. The lung has been found to present the appearances of caseating pneumonia succeeded by excavation. The liver appears to be uniformly injected, vessels of every denomination being loaded with blood, which, when coagulated after death, whether by reagents or otherwise, gives an appearance of universal thrombosis. In one case I noticed masses of so-called hepatic apoplexy, or the cavernous condition. I have described as present in one instance a very peculiar localised dilatation of the capillaries. I have since seen it in another, giving to parts of the organ a spongy appearance. It is to be taken into question whether these conditions, specimens of which are before the Society, are not due to *post-mortem* development of gas in the tissue. At the same time I may say that I have not seen it except in diabetes.

The kidney has been found to present all the phases of tubal and sometimes of interstitial nephritis.

With regard to the pancreas I have no evidence to offer.

To come to the general results of the inquiry, the lung and kidney must take a secondary place, since they are clearly involved only with the progress of the disease, not at its beginning. The liver appears to be more essentially concerned: in view to which I may refer to the occasional presence of jaundice with severe dia-

betes. With our present knowledge interest must attach mainly to the nervous system, and considering the slight changes noticeable in the sympathetic and in the spinal cord it must centre chiefly in the brain. This, according to my observations, is not healthy, but uniformly the contrary.

The changes, all perivascular, show an altered relation between the blood-vessels and the brain tissue, but it must be allowed that though constant in kind they are not uniform in position, but are widely and somewhat irregularly scattered, so that to find them they must be somewhat generally sought for. It has been my practice to harden many portions of the brain and cut sections by hand in a good light, being always guided by naked-eye inspection. I do not think it is of much use to put pieces of brain into a machine and cut at random. I fancy this process has led to the overlooking of changes which I have never failed to find. I do not suppose we have got to the bottom of this matter; as yet we may be only troubling the surface of it, but that something shows on the surface is certain. I cannot doubt that the brain is the seat of morbid action in diabetes, whether as the consequence of the disease or the cause of it. The changes, chiefly such as belong to hyperæmia, are, as I maintain, constant with diabetes, though scarcely to be asserted as peculiar to it, any more than we can say, with our present imperfect knowledge, that the changes of tetanus or chorea are peculiar to those disorders. Nervous pathology is still in its infancy, but we have with diabetes evidences of morbid change which sometimes resemble the more acute congestive lesions of tetanus, hydrophobia, and chorea; in other cases the more chronic conditions which belong to insanity. What there is behind which causes dilatation of the vessels, extrusion of their contents, and alteration of their channels, we very imperfectly know in any case. We see rather the result of the storm than the storm itself. Perhaps some day we may get behind the wind and see what has led to it.

It may be suggested that the diabetic changes are the results of the circulation of altered blood, but against this we have evidence that they are especially localised in the brain, whereas the blood is everywhere; and we have the important testimony of clinical experience that the disease continually begins as the consequence of a mental impression or cerebral state. No fact with regard to diabetes is more clearly declared than its frequent origin in grief or

anxiety. What will give a child chorea will often give a man diabetes.

I have nothing to say further except to express a hope that some younger and abler observer will carry the inquiry much further than I have done. My preparations are at the service of any one who cares to see them. And I would venture to suggest, sir, that the observations in question, apart from any theory which may be founded upon them, would form a fit subject for a committee. I have no doubt, sir, that you could find pathologists, whose verdict would command respect, who are not yet committed beyond recall with regard to matters which have been in question.

Dr. Pavy said that his remarks would be chiefly directed to the chemical questions involved, and especially to the condition of the blood. He agreed with Dr. Dickinson that there was a pathological anatomy of diabetes, but he felt confident that the primary condition was a chemical fault. He had recently been making, in conjunction with his two trained analysts, a series of researches on the physiology of the carbo-hydrates, and the results he had obtained gave an entirely new aspect to that subject. The group of bodies included in the term carbo-hydrates were found in both the animal and the vegetable kingdoms; they were all bodies which, in the presence of certain ferments, underwent changes. Diastase, the ferment of saliva, that of the pancreatic juice, and that of the intestinal juice, all produced the same result when they acted upon starch, converting it first into a series of principles known as dextrins, and finally into maltose; the action of these ferments could go no further, they could not produce glucose. The process of conversion was attended by increasing hydration: thus starch might be said to consist of twelve atoms of carbon combined with ten molecules of water; whereas, maltose, the final result of this fermentative action, consisted of twelve atoms of carbon combined with eleven molecules of water. The dextrins, which intervened between starch and maltose, presented intermediate degrees of hydration. Starch had no power of reducing cupric oxide, and it was precipitated by alcohol; whereas the dextrins were not precipitated by alcohol, and had the power of reducing cupric oxide. Starch, dextrin, and maltose, acted on by heat in the presence of sulphuric acid, were converted into glucose. The analytic process of which Dr. Pavy had availed himself was based on these facts. The

liquid which was to be analysed was divided into two parts—one part was immediately tested, and its power of reducing cupric oxide estimated; the other half was treated with sulphuric acid, and so converted into glucose; and, the amount of glucose being known by the amount of cupric oxide reduced, on comparing the two results, the exact condition of the carbo-hydrate in the original liquid as to its degree of hydration was known. Now, though it had been shown that all the ordinary ferments of the body could only bring starch into the condition of maltose, yet the carbo-hydrate found in diabetic urine was glucose, the more highly hydrated principle. The glucose-forming ferment existed only in the liver under certain conditions. In the alimentary canal, in the liver, and in the circulatory system, the action upon the carbo-hydrates in health was the reverse of that gradually increasing hydration above described. He had found, by experiment, that from the mucous membrane of the alimentary canal a ferment was obtainable which converted glucose into maltose; cane-sugar, not into glucose, as was formerly supposed, but into maltose; and starch either into maltose or a dextrin of low cupric-oxide-reducing power. Portal blood contained maltose and dextrins, and, under proper conditions, the liver was capable of converting maltose and dextrins into glycogen. When carbo-hydrates were taken by a healthy person, they were converted, not into glucose, but into a dextrin, or maltose. This was the process of assimilation of the carbo-hydrates in a healthy person, but in a diabetic person this power was lost; starch and sugar in them were converted into glucose, and appeared in the blood, from which it was eliminated by the kidneys: even on a purely meat diet, a person suffering from a severe form of diabetes excreted glucose; this could only occur through the splitting up of a nitrogenous molecule into urea or some other product, and glucose. For this to occur, there must be a glucose-forming ferment; such a ferment existed in the liver, but only under certain circumstances. When the liver was supplied with blood which was thoroughly venous, it converted carbo-hydrates into maltose; but, if the blood were imperfectly venous, or partook of the nature of arterial blood, the resulting body was glucose; it could be shown, by a number of different methods, that an excess of oxygen in the portal blood led to glycosuria. These facts threw great light on the cause of diabetes, and had convinced him that it was due to a dilatation of the arteries of the chylopoietic viscera, brought about by vaso-motor

paralysis. Experiment has shown that this dilatation actually occurred. Mere congestion of the liver was not an efficient cause; there must be an afflux to it of blood not properly venous, and such an afflux there was in paralysis of the vaso-motor system; for, as the well-known experiment on the rabbit's ear showed, section of the sympathetic caused such a modification in the circulation that the blood, when it reached the veins, still had the arterial characters. If there were a limited amount of vaso-motor paralysis, the diabetes was not severe; in such cases nothing very marked might be observed with regard to the tongue, but, as the case advanced, the tongue became involved—it became intensely red and injected, that is, exceedingly hyperæmic. Here, he thought, there was an ocular demonstration of the theory he advanced; if the chylopoietic viscera were in the same hyperæmic condition as the tongue, then they were in a condition which must result in glycosuria. In young subjects, diabetes was a progressive disease; at an early stage the glycosuria might be arrested but it returned, and finally ceased to be amenable to treatment. There was no doubt that there was some nerve-lesion in diabetes; and, holding the opinion he had expressed, he would strongly urge those who had turned their attention to the pathological anatomy of the nervous system, to make careful examination of the vaso-motor system.

Dr. Douglas Powell.—Sir, thus late in the evening, and after the last two brilliant communications, I will only further detain the Society but a very few minutes. This debate, it seems to me, has been useful, not only in summarising the uncertainty of our knowledge of the pathology of diabetes, but in pointing out the direction for further inquiry and in indicating more especially the importance of experimental physiology and pathology, combined with physiological chemistry, as the means by which light may most certainly be thrown upon the nature of the disease. I think the communication just heard from Dr. Pavy has redeemed the Society from some reproach, inasmuch as from the side of living pathology no previous contribution had been made, and to my mind the very important and novel observations of Dr. Pavy dovetail in their conclusions in no small degree with the account of Dr. Dickinson as to the existence of nervous lesions. I would wish to be allowed to second Dr. Dickinson's suggestion that a committee be nominated to examine and report upon the microscopical speci-

mens shown tonight, and I would beg to add that that committee be a standing one to report upon all specimens brought here illustrating the condition of the nervous system in diabetes. I cannot myself imagine how any one can fail to find in the specimens brought by Dr. Dickinson to-night—such positive lesions as hæmorrhages, distorted vessels, and thickened sheaths—examples of morbid anatomy, be they the results of coma or the causes of it. But to pass on to the subject of my own very slight contribution to-night, it is with reference to what I believe to be a prevalent opinion as to there being some causal relationship and affinity between diabetes and phthisis. I believe this somewhat loosely held view to arise from a confusion of two things, diabetic phthisis, if there be such a disease, and phthisis in diabetes, in the same manner as syphilitic phthisis, a very rare disease, and phthisis occurring in the course of syphilis, a very common occurrence, are often confounded together. In my own experience I could not recall half a dozen cases of chest disease in which there has been diabetes. In the out-patient department of the Brompton Hospital, where I worked for several years, diabetes was most rarely met with, and during the five or six years that I have had care of in-patients, with an average of about thirty beds constantly occupied by cases of phthisis of every variety, degree of activity, and stage, I can recall no case of diabetes, the only case that has occurred having no chest disease. Since the last meeting, however, I thought it might be useful definitely to ascertain the proportion, if any, of diabetes amongst the consumptive patients now in the hospital, and through the kindness of my colleagues and the labours of my friends Messrs. Waugh, Jackson, Horrocks, and Sutton, the resident clinical assistants, in examing the urine, I have ascertained results in 165 cases of phthisis representing most varieties, degrees, and stages, and 65 other forms of chest disease now in the hospital. I may briefly state the results of no small labour by saying that the urines ranged in specific gravity from 1010 to 1035, that in 22 cases albumen was found present in more or less quantity, that in 30 cases there was an excess of phosphates (doubtless in some instances due to their taking hypophosphites), but that in no case was any sugar to be found. It would be interesting, sir, to have converse statistics prepared showing in what proportion of diabetics lung disease prevails. I do not mean statistics drawn from fatal or last stage cases; death

probably approaches us all through the medium of the lungs, the heart, or the brain; and I appeal to those who have made many *post-mortems* in chronic diseases whether some destructive lung lesions are not found in a large proportion of them. It is a pity that we have had no morbid specimens of lungs from diabetics brought forward during this debate, that we might better judge whether there be anything very peculiar or characteristic in the form of lesion. I myself believe that phthisis and diabetes have nothing in common, they rarely coexist in the earlier stages, they do not merge into one another, they are not interchangeable by heredity. Phthisis certainly does not predispose to diabetes nor the reverse, save in as far as diabetes is an exhausting malady, in the course of which as such—but with no other causal affinity—some form of phthisis or destructive inflammatory chest disease is apt to arise.

Dr. Radcliffe Crocker.—Now that the subject of diabetes is under discussion it may not be inappropriate to bring under the notice of the Society a method for the quantitative estimation of sugar in the urine, for which we are indebted to Dr. Duhomme. It is not new, having been communicated to the Société de Thérapeutique by Dr. Duhomme, at the meeting of April 22nd, 1874; but I believe it is not known in England, or at all events not as well as it deserves. It was brought under my notice by a patient, a French lady, who was in the habit of estimating the amount of sugar in her own urine by Dr. Duhomme's apparatus, a practice which, however objectionable on other grounds, speaks well for the facility of the plan.

The chemistry is identical with that of Fehling's well known method; the difference lies entirely in the mechanical details. The apparatus consists of two of Limousin's compte-gouttes graduated to 1 c.c. and 2 c.c. respectively. These are simply well-made pipettes with a small red rubber ball to act as a sucker, and to allow the fluid taken up to escape drop by drop. The problem is to estimate what fraction of 1 c.c. of the urine is required to completely decolorise 2 c.c. of Fehling's solution, which is equivalent to 1 centigramme of glucose. The difficulty of using the pipettes for this purpose arose from the fact that the size of the drop of urine varies for each urine and for each pipette. To obviate this 1 c.c. of the urine to be experimented upon is drawn up into the

pipette, and allowed to escape guttatim, the drops being counted; if 1 c.c. of the urine contained 20 drops each drop represents $\frac{1}{20}$th of a c.c., and this being ascertained no more measuring of this particular urine is required; 2 c.c. of Fehling's solution are then taken up by the other pipette and passed into a test-tube. Duhomme recommends that this should be diluted with an equal quantity of Liquor Sodæ, but it appears to me that water would do as well. The test fluid is brought to the boiling point and urine dropped in until complete decolorisation is effected in the usual way. The number of drops of urine required represents then 1 centigramme of glucose. Then multiply the number of drops contained in 1 c.c. of the urine examined by 10, and divide the product by the number of drops of urine required for the complete decolorisation of the 2 c.c. of Fehling's solution; the result gives the quantity of glucose per litre in grammes and centigrammes. Example: If the number of drops in 1 c.c. of urine is 20, and the number for decolorisation 8, then $\frac{20 \times 10}{8} = 25$ grammes per litre.

In the books furnished with the apparatus, which only costs four francs, there is a table by which the quantity of sugar per litre can be seen at a glance without any calculation.

If the urine contain much sugar it must be diluted, and 1 part to 9 of distilled water is the most convenient. In a first estimation, when the quantity of sugar is quite unknown, a rough estimation with undiluted urine saves time by enabling you subsequently to go at once within three or four drops of the amount required for decolorisation. The employment of three test tubes simultaneously, the number of drops of urine in each differing by one drop ensures accuracy.

In measuring, the fluid should first be drawn into the pipette *above* the graduation, and then allowed to escape until the bottom of the meniscus just touches the line of graduation.

It is obvious that this plan could also be employed with Pavy's or other test solution if made for the metric system, and might replace the cumbersome burette in many volumetric estimations. The apparatus can now be procured in London.

Report of the Committee appointed to Investigate the Changes Exhibited by Specimens of the Nervous Centres in Cases of Diabetes submitted for Examination by Drs. Dickinson, F. Taylor and Goodhart, Seymour Taylor, S. Mackenzie and Hale White.

Having examined and compared the various sections of tissues from diabetic subjects, we have come to the following conclusions:—Some of the sections certainly present appearances such as are not seen in typically normal tissues. Some of these, such as the miliary bodies, irregular staining, &c., are clearly the result of faulty methods of preparation. Others must be considered as the result of changes during life.

In many specimens the peri-vascular spaces are of considerable size, but neither their size nor their number exceeds that which is frequently found *post mortem* apart from diabetes or any nervous disorder.

In one specimen of Dr. Dickinson's—No. 10—the number and size of the spaces excite surprise, but the section is from beneath the Corpus striatum where numerous and large arteries enter the brain substance.

Granular and amorphous matter, such as is seen in some of the specimens within the peri-vascular spaces, is frequently found in such spaces whatever the cause of death in the subject examined.

In some specimens there is evidence of recent and of old hæmorrhage, small in amount, around the vessels, but this is only such as is often met with in various diseases and after asphyxial modes of death.

We fail to find any abnormal bulgings or dilatations of the vessels, large or small. On the whole, we found the changes in the medulla to be less marked than those in the cerebral hemispheres.

No significance can be attached to the occlusion or to the dilatation of the central canal of the cord, even when as marked as in Dr. Dickinson's specimen—No. 20.

In the one specimen of sympathetic ganglion the pigmentation in the cells is not abnormally great.

We have failed to find in the specimens submitted to us any changes which can be regarded as exclusively or even constantly associated with diabetes.

GEORGE H. SAVAGE.
W. R. GOWERS.
J. F. PAYNE.

October 2nd, 1883.

INDEX.

ABERCROMBIE (*John*), congenital atresia of right ventricle, ductus arteriosus patent 78

ABNORMALITIES, see *Heart*.

ABNORMALITY of bones and muscles near the shoulder-joint (C. B. Lockwood) 227

ABSCESSES, two hundred, in the liver of a kangaroo (J. B. Sutton) . 325

„ miliary, of the heart, and endocarditis in a case of hip-joint disease (N. Moore) 52

ACETONE in diabetes, test for, see *Diabetes* (Ralfe in discussion on) . 329

ACID, see *Sulphuric Acid*.

ADDISON'S DISEASE, dissection of the abdominal sympathetic, from a case of (J. F. Goodhart) 271

„ — without melasma causing death by syncope, apparently from seasickness (W. W. Greene) 270

ADENO-SARCOMA of testis, with secondary growth in the viscera, in a case of cardiac malformation (V. Horsley) 161

ALBUMEN in urine, tests for (C. H. Ralfe) 143

AMPUTATION, changes in nerves (W. H. White and W. Edmunds) . 16

ANASTOMOSIS, see *Arteries* (coronary).

ANEURYSM of aorta (R. E. Carrington) 78

„ — rupturing into the pulmonary artery (S. West) 64

„ of middle part of arch of the aorta, death from embolism of the aorta, clot detached from the left ventricle (S. West) 62

„ (diffuse) of the abdominal aorta (A. Q. Silcock) 68

„ (dissecting,) of the first part of the arch of the aorta (Samuel West) . 65

ANEURYSMS in children (N. Moore) 71

ANIMALS, LOWER, DISEASES, &c., of 308-27

„ see *Bone Disease* in.

ANOPHTHALMOS, one-sided, in an infant, living specimen (R. J. Godlee) . 230

ANTHRACOID affection of intestine, stomach, and lung (F. A. Mahomed) . 294

ANTHRAX of face (J. N. Davies-Colley) 291

„ malignant, case of (T. Bryant) 293

„ *post-mortem* of ditto, with anthracoid affection of intestine, stomach, and lung (F. A. Mahomed) 294

AORTA, see *Aneurysm*.

„ embolism of, clot detached from left ventricle, death (S. West) . 62

AORTIC VALVE, abnormal (W. A. Berridge) 76

„ — recent vegetations on (F. C. Turner) 36

APPENDIX VERMIFORMIS, ulceration of, in typhoid fever (N. Moore) . 113

ARM, FORE-, congenital hypertrophy of (F. S. Eve) . . . 300

ARTERIES, general degeneration of, in a case of gastric ulcer (N. Moore) . 94

ARTERIES, CEREBRAL, morbid conditions of [obstruction by atheroma] (C. H. Jones) 55
„ MIDDLE CEREBRAL, thrombosis of, in secondary syphilis (S. J. Sharkey) . 10
„ CORONARY, anastomosis of (S. West) 66
ARTERITIS, with thrombosis of both middle cerebral arteries in secondary syphilis (S. J. Sharkey) 10
ARTERY, CORONARY, complete obliteration of one; sudden death (S. West) . 66
„ left common ILIAC, thrombosis of, causing gangrene of right leg (J. K. Fowler) 77
„ PULMONARY, rupture of aneurysm of aorta into (S. West) . . 64
„ — thrombosis of, para-vaginal and dermoid cysts (F. A. Mahomed) . 72
ARTHRITIS, rheumatic, from a Roman tomb (N. Moore) . . 226
ASCARIS MYSTAX vel alata (F. C. Turner) 307
ATRESIA, see *Ventricle* (right)
ATROPHY, acute, of the liver (Jas. Cavafy) 122
„ — ditto (W. Cayley) 127
AURICLE, left, sacculated fibrinous coagulum loose in (F. C. Turner) . 36

BABOON, retroflexion of uterus in a (J. B. Sutton) . . . 326
„ rickets in a (J. B. Sutton) 310
„ ditto, "Cynocephalus porcarius" (J. B. Sutton) . . 312
„ skull of, with extraordinary thickness of bone (J. B. Sutton) . . 310
„ see *Monkey*
BACILLI of LEPROSY (J. D. Hillis) 289
„ of TUBERCLE, found in contents of cavities and not in lung tissue (S. West) 26
BARKER (*Arthur E.*), extreme prolapse of uterus, bladder, and vagina beneath the pubic arch; obstruction, with dilatation of kidneys, &c. . . 181
„ cysts, containing clear fluid, probably dilated lymphatic spaces . . 304
BARLOW (*T.*), *report* on Dr. Goodhart's specimen of hyperostosis . 201
BARNES (*Robert*), pigmentation of the cervix uteri . . . 176
BARWELL (*Richard*), extreme deformity from rachitic osteo-malacia . 202
„ juvenile osteo-malacia 205
BECK (*Marcus*), *report* on Mr. Clutton's case of alveolar sarcoma of the skull 215
BERRIDGE (*W. A.*), abnormal aortic valve 76
„ epithelioma of the bladder from a case of hæmaturia . . . 161
BILE-DUCT, common, congenital absence of, in a child, producing cirrhosis of liver (H. Gibbes) 129
BLADDER, epithelioma of, from a case of hæmaturia (W. A. Berridge) . 161
„ multiple growths in (J. H. Morgan) 157
„ secondary growth in, in a case of alveolar sarcoma of skull (H. H. Clutton) 212
„ mucous polypus of (S. G. Shattock) 150
„ extreme prolapse of, beneath the pubic arch, obstruction, &c. (A. E. Barker) 181
„ sacculated, in a female (S. West) 146
„ sarcoma of, of very rapid development (S. West) . . . 145
„ — of a diverticulum of (W. Roger Williams) . . . 152
„ villous sarcoma of (W. Roger Williams) . . . 156
BLOOD, chemical conditions of, in diabetes, see *Diabetes* (F. W. Pavy in discussion on) . . . . . .
„ see *Cyst* (Blood)
„ lipæmic, see *Diabetes* (Dr. Hamilton in discussion on) . . 347

BONE, disease of in animals: Indian monitor lizard—South American ostrich—Macaque monkey—"Cercopithecus Diana" and "cynosurus"(J.B. Sutton) 315-20
„ tabular view of normal and abnormal processes in bone development (J. B. Sutton) 322
„ softening and rickety changes of, probably syphilitic, in hyperostosis of skeleton (Jas. F. Goodhart) 197
„ facial, severe syphilitic disease of; death from pyæmia (V. Horsley) . 208
„ of the leg, calcified round-celled sarcoma of (W. R. Williams) . 267

BONES, ABNORMALITY of, near the shoulder-joint (C. B. Lockwood) . 227
„ DISEASES of 185-220

BONY OUTGROWTH, peculiar, from the fibula (W. Hale White) . 227

BOWLBY (*Anthony A.*), intussusception caused by an intestinal polypus, and cured after sloughing of the strangulated bowel . . . 106
„ very large connective-tissue polypus of rectum . . . 107
„ diffuse polypoid growths of large intestine . . . 108
„ case of double obturator hernia 109
„ two cases of curvature of the femur, one due to osteitis deformans, the other to an injury, followed by chronic inflammation . . . 192

BOYD (*Stanley*), tubercular ulcers of the tongue . . . 134

BRAIN, condition of, in a case of thrombosis of middle cerebral arteries (S. J. Sharkey) 12
„ universal cystic degeneration of, two cases (G. H. Savage and W. Hale White) 1
„ on the causes of holes in the brain (G. H. Savage and W. Hale White) . 1
„ Gruyère cheese or vacuolated condition of, relation to diabetes (Hale White) 351

BROMIDE RASH simulating erythema nodosum (P. Horrocks) . . 272
„ unusual; living specimen (P. Horrocks) 273

BRYANT (*Thomas*), case of charbon or malignant pustule . . 293
„ *post-mortem report* on ditto, by F. A. Mahomed . . . 294

BUTLIN (*Henry T.*), *report* on Mr. Roger Williams' tumour in diverticulum of the urinary bladder 156
„ *report* on Dr. W. B. Hadden's specimen of disseminated sarcoma . 239
„ *report* on Mr. Geo. Lawson's case of recurrent cartilaginous tumour of lower jaw 264

CALCULUS, renal, and abscess, ruptured into left pleural cavity (J. R. Lunn) 138
„ urinary, two specimens from animals, composed of carbonate of lime (S. G. Shattock) 326
„ large, with nucleus of a mulberry calculus, removed from the bladder by lithotomy (G. Lawson) 148

CALVARIA, bossy (D. B. Lees) 228

CANCER of ŒSOPHAGUS, with perforation into right lung; upper lobes filled with decomposing food (F. S. Eve) 80
„ of PANCREAS, primary (P. Kidd) 136
„ of the undescended TESTIS, primary, cancer of thymus, &c. (F. A. Mahomed) 182
„ disseminated, case of (P. Kidd) 240
„ see *Epithelioma*.
„ colloid, of stomach, lymph glands and lungs (P. H. Pye-Smith) . 100

CARBONATE OF LIME, see *Lime*.

CARCINOMA of ŒSOPHAGUS (N. Moore) 79
„ of omentum (B. Fenwick) 269
„ see *Cancer*.

CARIES, dry, of the knee-joint (H. A. Lediard) . . . 229

CARRINGTON (*R. E.*), aneurysm of aorta 78
CAVAFY (*John*), heart disease and subcutaneous fibrous nodules following rheumatism 41
„ acute atrophy of the liver 122
CAYLEY (*William*), cirrhosis and acute atrophy of liver . . 127
CERVIX, see *Uterus* (cervix of).
CHARBON, or malignant pustule, case of (T. Bryant) . . . 293
CHOREA, CANINE, pathology of (W. B. Hadden) . . . 308
CHURCHILL (*Frederick*), case of multiple exostoses . . . 210
CIRCULATION, ORGANS of, diseases, &c., of . . 29-78
CIRRHOSIS of liver (A. Money) 136
„ ditto in a child of seven months from congential absence of the common duct (H. Gibbes) 129
„ and acute atrophy of liver (W. Cayley) 127
CLUTTON (*H. H.*), alveolar sarcoma of skull; secondary growth of bladder 212
„ *Report* on ditto by the Morbid Growths Committee (Marcus Beck and R. J. Godlee) 215
„ case of keloid following lupus scraping and developing in other operation wounds 273
COLON, transverse, intense inflammation of, in a case of sulphuric-acid poisoning (W. Hale White) 96
COMA, duration of, in diabetes (Steph. Mackenzie) . . 356-9
COMMITTEE ON MORBID GROWTHS, REPORTS of:
„ on Mr. Roger Williams's tumour in a diverticulum of the urinary bladder (J. F. Goodhart and H. T. Butlin) 156
„ on Mr. H. H. Clutton's case of tumour of the skull (Marcus Beck and R. J. Godlee) 215
„ on Mr. W. H. Kesteven's specimen of blood-cyst of the spinal column (Marcus Beck and R. J. Godlee) 220
„ on Dr. W. B. Hadden's specimen of disseminated sarcoma (H. T. Butlin and Jas. F. Goodhart) 239
„ on Mr. George Lawson's case of cartilaginous tumour of the lower jaw (J. F. Goodhart and Henry T. Butlin) 264
COMMITTEES, REPORTS OF OTHER:
„ on Dr. Norman Moore's specimen of fibrous structures resembling valves in the left ventricle of the heart (J. F. Payne, P. H. Pye-Smith, and S. Coupland 30
„ on Dr. Handfield Jones's specimens of obstruction of the cerebral vessels by atheroma (S. Coupland and J. F. Payne) 60
„ on Dr. Sharkey's specimen of syphilitic inflammation of the capsule of the liver (S. Coupland and J. F. Payne) 122
„ on Dr. J. F. Goodhart's specimen of extensive hyperostosis, with bone softening and rickety changes (C. Hilton Fagge, Warrington Haward, T. Barlow, and J. F. Goodhart) 201
„ on Mr. Malcolm Morris's case of so-called xanthoma in connection with diabetes (H. R. Crocker, A. Sangster, and Jon. Hutchinson) . . . 284
„ *report* of committee appointed to investigate the changes exhibited by specimens of the nervous centres in cases of diabetes submitted for examination by speakers in the discussion on the morbid anatomy of diabetes (Geo. H. Savage, W. R. Gowers, and J. F. Payne) 397
COUPLAND (*Sydney*), *report* on N. Moore's case of abnormal heart . 30
„ *report* on Dr. Handfield Jones's cases of obstruction of cerebral arteries by atheroma 60
„ *report* on S. J. Sharkey's case of syphilitic inflammation of the capsule of the liver 122
„ analysis of twenty cases of diabetes at the Middlesex Hospital . . 336

CRANIUM, congenital malformation of (F. Treves) . . . 228
„ alveolar sarcoma of; secondary growth of bladder (H. H. Clutton) . 212
„ deep ulceration of (N. Moore) 209
„ of baboon, with extraordinary thickness of bone (J. B. Sutton) . 311
CROCKER (*H. Radcliffe*), *report* on Mr. Malcolm Morris's case of xanthoma in connection with diabetes 284
„ *remarks* in DISCUSSION ON DIABETES [Dr. Duhomme's method of quantitative estimation of sugar in urine, &c.] 395
CURNOW (*John*), hydatid cyst in lung; empyema . . . 24
„ ulceration of large and small intestines in enteric fever . . 116
CURVATURE of the femur, two cases, due to osteitis deformans and to injury followed by chronic inflammation (A. J. Bowlby) . . . 192
CYNOCEPHALUS porcarius, W. Africa, rickets in (J. B. Sutton) . 312
CYSTIC DISEASE, incipient, of parovarium and broad ligament (A. Doran) . 169
CYSTS, sarcomatous blood, of spine, causing paraplegia (W. H. Kesteven) . 216
„ containing clear fluid, probably dilated lymphatic spaces (A. E. Barker) . 304
„ dermoid, in a case of thrombosis of pulmonary artery (F. A. Mahomed) . 72
„ hydatid, see *Hydatid*.
„ para-vaginal, in a case of thrombosis of pulmonary artery (F. A. Mahomed) 72

DAVIES-COLLEY (*J. N. C.*), lympho-sarcoma of the back, accompanied by spreading ulceration 258
„ anthrax of face 291
DEFORMITIES of bones and muscles near the shoulder-joint (C. B. Lockwood) 227
„ extreme, from rachitic osteo-malacia (R. Barwell) . . 202
„ see *Malformation*.
DEGENERATION, universal cystic, of brain, two cases (G. H. Savage and W. Hale White) 1
DERMOID, see *Cysts* (dermoid).
DIABETES, morbid anatomy of, DISCUSSION upon the . . 328-397
„ *remarks* by the President, J. W. Hulke 328
„ — Samuel Wilks . . . 328
„ — C. H. Ralfe [aceto-acetic acid test for indicating presence of acetone, &c.] 329
„ — David W. Finlay [record of a fatal case, and analysis of twenty cases at the Middlesex Hospital by Drs. Finlay and Coupland] . 333
„ — J. F. Goodhart, for Dr. Hamilton, of Aberdeen [specimen of lipæmic blood] 347
„ — W. Hale White [condition of nervous system in diabetes; *post-mortems* of cases at Guy's; examination of urine in insane persons] 348
„ — Stephen Mackenzie [analysis of fatal cases in the London Hospital, naked-eye appearances of the body and results of microscopical examinations] 355
„ — Seymour Taylor . . . 365
„ — Frederick Taylor [condition of nervous system, mode of death in diabetes, &c.] . . . 367
„ — Dawson Williams [cases from records of University College Hospital, deaths from Registrar-General's returns] 374
„ — W. Howship Dickinson [reply to Dr. F. Taylor, microscopic appearances of the organs and perivascular changes] 385
„ — F. W. Pavy [chemical conditions of the blood in diabetes, maltose, &c.] 391
„ — Douglas Powell [non-connection of phthisis and diabetes] . 393
„ — H. Radcliffe Crocker [Dr. Duhomme's method of quantitative estimation of sugar in urine, &c.] 395
„ *report* of Committee appointed to investigate the changes exhibited by specimens of nervous centres in the cases of diabetes submitted for examination (Geo. H. Savage, W. R. Gowers, and J. F. Payne) . 397

DIAPHRAGM in a case of rickets (N. Moore) . . . 185

DICKINSON (*W. Howship*), *remarks* in DISCUSSION on DIABETES [reply to Dr. F. Taylor, microscopic appearances in organs and perivascular changes] . 385

DIGESTION, ORGANS OF, DISEASES, &c., of . . . 79-137

DISCUSSION upon the morbid anatomy of DIABETES . . 328-397
„ see *Diabetes.*

DISEASES, &c., of the NERVOUS SYSTEM . . . 1-18
„ of the ORGANS OF RESPIRATION . . . 19-28
„ of the ORGANS OF CIRCULATION . . . 29-78
„ of the ORGANS OF DIGESTION 79-137
„ of the GENITO-URINARY ORGANS . . . 138-184
„ of the OSSEOUS SYSTEM 185-229
„ of the ORGANS OF SPECIAL SENSE . . . 230-232
„ MORBID GROWTHS and TUMOURS . . . 233-269
„ of SPLEEN, SUPRARENAL CAPSULES, and THYROID . . 270-271
„ of the SKIN 272-290
„ MISCELLANEOUS SPECIMENS 291-307
„ of the LOWER ANIMALS 308-327

DISLOCATION, costo-chondral, in a case of fracture of sternum (W. A. Lane) 223

DIVERTICULUM of BLADDER, sarcoma of (W. Roger Williams) . . 152

DOG, pathology of chorea in the (W. B. Hadden) . . . 308

DORAN (*Alban*), incipient cystic disease of the parovarium and broad ligament 169

DREWITT (*F. Dawtrey*), analogy between rheumatic nodules of children and heart disease (living specimen) 50

DUCTS, see *Bile duct, Hepatic ducts.*

DUCTUS ARTERIOSUS, patent, in congenital atresia of right ventricle (J. Abercrombie) 78

DUHOMME'S method of quantitative estimation of sugar in urine . 395

DUODENUM, two cases of simple ulcer of (N. Moore) . . . 98

„ lympho-sarcoma invading (N. Moore) 99

DURHAM (*Arthur E.*), multiple ulcerating and sloughing sarcomata in various parts of the body, especially in the limbs . . . 243

„ extensive sloughing of the neck, "nondescript," lympho-sarcomatous tumour 245

„ enormous osteo-sarcoma of the left femur in a boy . . . 265

EDMUNDS (*Walter*), spinal nerves from three cases of infantile paralysis . 15
„ see *White* and Edmunds (amputation changes in nerves).

EDWARDS (*F. Swinford*), case of comminuted fracture of the tibia, with impaction of the anterior tibial vessels and nerve, followed by gangrene . . 222

ELBOW-JOINT from a case of scarlet fever (N. Moore) . . 225

EMBOLISM of aorta, clot detached from left ventricle, death (S. West) . 62

EMPYEMA, in a case of hydatid cyst in lung (J. Curnow) . . 24

ENCEPHALOCELE (J. B. Sutton) 18

ENDOCARDITIS, ulcerative, &c (F. Taylor) 38
„ with miliary abscesses of the heart, in a case of hip-joint disease (N. Moore) 52

ENTERIC FEVER, ulceration of large and small intestines in (J. Curnow) . 116
„ see *Typhoid.*

EPITHELIOMA of the bladder, from a case of hæmaturia (W. A. Berridge) 161
„ of stomach, with diffusion of secondary deposits in other viscera and the integuments (D. W. Finlay) 102
ERYTHEMA NODOSUM, bromide rash simulating (P. Horrocks) . . 272
EVE (*Frederic S.*), cancer of œsophagus, with perforation into right lung; upper lobes converted into a cavity filled with decomposing food . . 80
„ hypertrophy of condyle of lower jaw 187
„ two specimens of congenital hypertrophy or giant-growth of limbs . 298
Case 1, congenital hypertrophy of foot and leg, especially of skin and subcutaneous tissue of sole 298
„ 2, ditto of hand and forearm 300
EXOSTOSES, case of multiple (F. Churchill) . . . 210
EYE, see *Anophthalmos.*

FACE, anthrax of (J. N. Davies-Colley) 291
FAGGE (*Hilton*), *report* on Dr. Goodhart's specimen of hyperostosis . 201
FALLOPIAN TUBE, see *Hydrosalpinx.*
FEMUR, curvature of the, two cases, due to osteitis deformans and to an injury followed by chronic inflammation (A. J. Bowlby) . . . 192
„ left, enormous osteo-sarcoma of, in a boy (A. E. Durham) . . 265
FENWICK (*Bedford*), case of tricuspid stenosis . . . 35
„ carcinoma of omentum 269
FEVER, see *Typhoid, Enteric.*
FIBROIDS, see *Tumours.*
FIBROMA, lobulated lamellar, on the pleura (F. C. Turner) . . 19
FIBRO-MYOMA of UTERUS, becoming sarcomatous, with secondary growths (D. W. Finlay) 177
FIBULA, peculiar bony outgrowth from (W. Hale White) . . 227
FINLAY (*David W.*), epithelioma of stomach, with diffusion of secondary deposits in other viscera and the integuments 102
„ fibro-myoma of the uterus becoming sarcomatous, with secondary growths in pleura, heart, and kidney 177
„ *remarks* in DISCUSSION ON DIABETES [fatal case and analysis of twenty cases at the Middlesex Hospital] 333
FOOD, decomposing, in upper lobes of right lung from perforation of cancer of œsophagus (F. S. Eve) 80
FOOT, congenital hypertrophy of, especially the skin of the sole (F. S. Eve) . 298
FOREIGN BODY impacted in lung (N. Moore) . . . 23
FOWLER (*J. Kingston*), vessels from a case of gangrene of the right leg, caused by thrombosis of left common iliac artery, and detachment of a portion of the clot 77
FRACTURE of sternum, with costo-chondral dislocation (W. A. Lane) . 223
„ comminuted, of tibia, with impaction of anterior tibial vessels and nerve, followed by gangrene (F. S. Edwards) 222

GANGRENE of right leg, caused by thrombosis of left common iliac artery, and detachment of clot (J. K. Fowler) 77
„ in a case of comminuted fracture of the tibia (F. S. Edwards) . . 222
„ case of symmetrical (R. Southey) 286
GASTRITIS, phlegmonous, stomach exhibiting the condition known as (A. Q. Silcock) 90
GASTRORRHŒA, acute, stomach from a case of (H. Morris) . . 82
GENERATION, organs of, DISEASES, &c., of . . . 138-184

GIBBES (*Heneage*), cirrhosis of the liver in a child of seven months from congenital absence of the common duct 129
GODLEE (*Rickman J.*), one-sided anophthalmos in an infant (living specimen) 230
„ *report* on Mr. Clutton's case of alveolar sarcoma of the skull . . 215
GOODHART (*Jas. F.*), notes of cases of dilated stomach not due to pyloric obstruction, observed in *post-mortem* room of Guy's Hospital, 1875-82 . 88
„ extensive hyperostosis of skeleton with bone-softening and rickety changes, probably of syphilitic origin 197
„ *report* on ditto (Hilton Fagge, W. Haward, T. Barlow, and J. F. Goodhart) 201
„ dissection of the abdominal sympathetic, from a case of Addison's disease 270
„ *report* on Mr. Roger Williams's tumour in a diverticulum of the urinary bladder 156
„ *report* on Dr. W. B. Hadden's specimen of disseminated sarcoma . 239
„ *report* on Mr. George Lawson's case of recurrent cartilaginous tumour of lower jaw 264
„ see *Greene* (case of Addison's disease).
„ see *Hamilton* (discussion on diabetes).
GOWERS (*W. R.*), *report* on the specimens exhibited in the DISCUSSION ON DIABETES 397
GREENE (*W. Withers*), *per Jas. F. Goodhart*, Addison's disease without melasma causing death by syncope, apparently from sea-sickness . . 270
GROWTH, GIANT, of limbs, see *Hypertrophy* (congenital).
GROWTHS, MORBID 233-269
„ see *Committee* on.
„ multiple, in the bladder (J. H. Morgan) 157
GUMMA, syphilitic, of the heart (G. C. Henderson) . . . 53

HADDEN (*W. B.*), tubercular disease of the tongue . . . 135
„ case of disseminated sarcoma 236
„ *report* on ditto by the Morbid Growths Committee (H. T. Butlin and Jas. F. Goodhart) 239
„ pathology of canine chorea 308
HÆMATURIA, epithelioma of the bladder, from a case of (W. A. Berridge) 161
HAMILTON (*Dr.*), *of Aberdeen*, specimen of lipæmic blood in diabetes (discussion on Diabetes) 347
HAND and FOREARM, congenital hypertrophy of (F. S. Eve) . . 300
HAWARD (*Warrington*), *report* on Dr. Goodhart's specimen of hyperostosis 201
HEAD and NECK, recurrent cartilaginous tumour of (Geo. Lawson) . 261
HEART, variety in the structure of (N. Moore) . . . 31
„ abnormal [fibrous ring in left ventricle attached to ventricular septum and mitral valve] (N. Moore) 29
„ malformed, consisting of two cavities (F. C. Turner) . . . 32
„ malformation of, adeno-sarcoma of testis, &c., in a case of (V. Horsley) . 161
„ disease and subcutaneous fibrous nodules following rheumatism (J. Cavafy) 41
„ disease, analogy between, and the rheumatic nodules of children (F. D. Drewitt) 50
„ disease, adherent pericardium, rheumatic nodules (A. Money) . . 45
„ miliary abscesses of, in a case of hip-joint disease (N. Moore) . . 52
„ secondary growths in, in fibro-myoma of uterus (D. W. Finlay) . 177
„ syphilitic gumma of the (G. C. Henderson) . . . 53
„ see *Endocarditis*.
HEATH (*Christopher*), living specimen of hypertrophy of the left ramus of the lower jaw 185
HENDERSON (*George C.*), syphilitic gumma of the heart . . 53

HEPATIC DUCTS, deposit of lime salts in mucous membrane of, in an ox (B. G. Morison) 137
HERNIA, congenital inguinal, in a case of testicle in the perinæum (W. R. Williams) 168
„ double obturator, case of (A. A. Bowlby) 109
HILLIS (J. D.), of Demerara, per Dr. George Thin, the bacilli of leprosy . 289
HIP-JOINT DISEASE, miliary abscesses of heart in a case of (N. Moore) . 52
HOLES in the BRAIN, on the causes of (G. H. Savage and W. Hale White) . 1
HORROCKS (P.), bromide rash simulating erythema nodosum . . 272
„ unusual bromide rash; living specimen 273
HORSLEY (Victor), adeno-sarcoma of testis with secondary growths in the viscera, occurring in a case of cardiac malformation . . . 161
„ case of severe syphilitic disease of facial bones and viscera; death from pyæmia, 208
„ micrococci in pyæmia 298
HULKE (J. Whitaker), remarks in opening DISCUSSION ON DIABETES . 328
HUTCHINSON (Jonathan), postscript on Mr. M. Morris's case of xanthoma in connection with diabetes 285
HYDATID CYST in lung, empyema (J. Curnow) . . . 24
HYDROCELE, acute, in a case of testicle in the perinæum (W. R. Williams) . 168
HYDROSALPINX, double (N. Moore) 182
HYPEROSTOSIS, extensive, of skeleton, with bone softening and rickety changes, probably syphilitic (Jas. F. Goodhart) 197
HYPERTROPHY of condyle of lower jaw (F. S. Eve) . . . 187
„ of left ramus of lower jaw, living specimen (Ch. Heath) . . 185
„ congenital, or giant growth of limbs. Case I. of foot and leg, and specially skin and subcutaneous tissue of the sole (F. S. Eve) . . 298
„ ditto, case II. of hand and forearm (F. S. Eve) . . . 300
ILEO-CÆCAL VALVE, stricture of intestine at (N. Moore) . . 112
ILEUM, adhesion of, to mesentery, causing intestinal obstruction (F. Taylor) 137
INFLAMMATION, chronic, curvature of the femur due to injury, followed by (A. J. Bowlby) 192
INSPIRATION, obstructed, larynx from an infant the subject of (D. B. Lees) 19
INTESTINES, DISEASES of 96-137
„ see *Intussusception*.
„ obstruction of, from adhesion of the ileum to the mesentery (F. Taylor) . 137
„ diffuse polypoid growths of large (A. A. Bowlby) . . . 108
„ see *Polypus* of.
„ stricture of, at the ileo-cæcal valve (N. Moore) . . . 112
„ ulceration of large and small, in enteric fever (J. Curnow) . . 116
„ ulceration of large, with perforation, in typhoid fever (S. West) . 114
INTUSSUSCEPTION caused by intestinal polypus; cured after sloughing of strangulated bowel (A. S. Bowlby) 106
JAW, LOWER, hypertrophy of condyle of (F. S. Eve) . . . 187
„ hypertrophy of left ramus of; living specimen (Ch. Heath) . . 185
„ ditto, excision of portion of jaw; upper end and neck of left ramus . 186
„ recurrent cartilaginous tumours of (Geo. Lawson) . . . 261
JOINTS, see *Elbow, Knee, Shoulder*.
JONES (C. Handfield), per Samuel Wilks, observations on morbid conditions of the cerebral arteries (obstruction by atheroma) . . . 55
„ *report* on ditto (S. Coupland and J. F. Payne) . . . 60

KANGAROO, two hundred abscesses in the liver of (J. B. Sutton) . 325
KELOID, following lupus scraping, and developing in other operation wounds (H. H. Clutton) 273
KESTEVEN (*W. H.*), sarcomatous blood cyst of spine, causing paraplegia . 216
„ *Report* on ditto by the Morbid Growths Committee (Marcus Beck and R. J. Godlee) 220
KIDD (*Percy*), primary cancer of pancreas 136
„ case of disseminated cancer 240
KIDNEY, calculus and abscess of, ruptured into left pleural cavity (J. R. Lunn) 138
„ dilatation of pelves, and structural changes in a case of prolapse of uterus (A. E. Barker) 181
„ secondary growths in, in fibro-myoma of uterus (D. W. Finlay) . 177
„ infarcts in (F. Taylor) 38
„ inflammation of, see *Nephritis*
„ alveolar sarcoma of the capsule of right (J. K. Thornton) . . 141
„ vacuolation of, in a case of cancer (F. A. Mahomed) . . 182
KNEE-JOINT, dry caries of (H. A. Lediard) . . . 229

LANE (*W. Arbuthnot*) fracture of sternum, with costo-chondral dislocation . 223
LARDACEOUS DISEASE of the liver, following the course of its capillaries (F. C. Turner) 131
LARYNGEAL PHTHISIS, case of (B. G. Morison) . . . 21
LARYNX from an infant the subject of a peculiar obstructed inspiration (D. B. Lees) 19
„ ulceration of, from a case of measles, and from a case of scarlet fever (N. Moore) 22
LAWSON (*George*), large calculus with a nucleus formed of a mulberry calculus, removed from the bladder by lithotomy 148
„ recurrent cartilaginous tumours of the head and neck [lower jaw] 261
„ *report* on ditto by the Morbid Growths Committee (Jas. F. Goodhart and H. T. Butlin) 264
LEDIARD (*Henry A.*), dry caries of the knee-joint . . . 229
„ melanotic spindle-celled alveolar sarcoma and gland . . . 269
LEES (*David B.*), larynx from an infant the subject of peculiar obstructed inspiration 19
„ bossy calvaria 228
LEG, gangrene of right, caused by thrombosis of left common iliac artery (J. K. Fowler) 77
„ congenital hypertrophy of (F. S. Eve) 298
LEPROSY, BACILLI of (J. D. Hillis) 289
LIGAMENT, BROAD, and parovarium incipient cystic disease of (A. Doran) 169
LIMBS, congenital hypertrophy, or giant growth of, two cases foot and leg, and hand and forearm (F. S. Eve) 298
LIME, CARBONATE of, specimens of calculi composed of, from animals (S. G. Shattock) 326
LIME SALTS, deposit, in mucous membrane of hepatic ducts in an ox (B. G. Morison) 137
LITHOTOMY, large calculus, with mulberry calculus nucleus, removed by (G. Lawson) 148

LIVER, &c., DISEASES of 118-137
„ two hundred abscesses in that of a kangaroo (J. B. Sutton) . . 325
„ acute atrophy of the (J. Cavafy) 122
„ ditto of, and cirrhosis (W. Cayley) 127
„ cirrhosis of (A. Money) 136
„ ditto, in a child of seven months from congenital absence of the common duct (H. Gibbes) 129
„ lardaceous disease of, following the course of the capillaries of the organ (F. C. Turner) 131
„ syphilitic inflammation of capsule of (S. J. Sharkey) . . . 122
„ tubercle of, in an adult (N. Moore) 133
„ vacuolation of, in a case of cancer (F. A. Mahomed) . . . 182
LIZARD, "Indian monitor," bone disease in (J. B. Sutton) . . 315
LOCKWOOD (*C. B.*), abnormality of bones and muscles near the shoulder-joint 227
LUNG, colloid cancer of (P. H. Pye-Smith) 100
„ with impacted foreign body (N. Moore) 23
„ hydatid cyst in, empyema (J. Curnow) 24
„ perforation into right, of cancer of the œsophagus (F. S. Eve) . . 80
„ bacilli of tubercle found in cavities of (S. West) . . . 26
„ bacilli of tubercle not found in tissue of (S. West) . . . 26
LUNN (*John R.*), case of ruptured stomach 81
„ renal calculus and abscess, traumatic? ruptured into left pleural cavity . 138
LUPUS SCRAPING, case of keloid following, and developing in other operation wounds (H. H. Clutton) 273
LYMPH GLANDS, colloid cancer of (P. H. Pye-Smith) . . . 100
LYMPHATIC SPACES, dilated, containing clear fluid (A. E. Barker) . 304
LYMPHO-SARCOMA of the back, sloughing, with other lesions of the skin and internal organs (F. Taylor) 247
„ of the back, accompanied by spreading ulceration (J. N. C. Davies-Colley) 258
„ invading the duodenum (N. Moore) 99
„ of the neck (A. E. Durham) 245

MACKENZIE (*Stephen*), *remarks* in DISCUSSION ON DIABETES [analysis of fatal cases in the London Hospital, naked eye appearances of the body and microscopic examination] 355
MACNAMARA (*C.*), case of congenital hypertrophy of limbs, see *Eve* (*F. S.*)
MAHOMED (*F. A.*), thrombosis of the pulmonary artery (para-vaginal and dermoid cysts) 72
„ primary cancer of the undescended testis, cancer of thymus, vacuolation of liver and kidneys 182
„ malignant anthrax (charbon), *post-mortem* of Mr. Bryant's case . 294
MALFORMATION, congenital, of the skull (F. Treves) . . . 228
„ see *Deformities*.
„ cardiac, see *Heart*.
MALIGNANT PUSTULE, see *Pustule* (malignant).
MEASLES, ulceration of larynx from a case of (N. Moore) . . 22
MEDIASTINUM, tumour of, rapid growth; sudden death (S. West) . 233
MELANOTIC SARCOMA, see *Sarcoma*.
MELASMA, case of Addison's disease without; death by syncope after sea-sickness (W. W. Greene) 270
MICROCOCCI in pyæmia (V. Horsley) 298
MITRAL VALVE, abnormal fibrous ring in left ventricle, attached to (N. Moore) 29

MITRAL VALVE, stenosis of, and recent vegetations on (F. C. Turner) . 36
MONEY (*Angel*), morbus cordis, adherent pericardium, rheumatic nodules . 45
„ cirrhosis of liver 136
MONKEY (Macaque), aged 3 years, bone disease in (J. B. Sutton) . 317
„ — thickness of bone in (J. B. Sutton) 320
„ "Cercopithecus Diana," bone disease in (J. B. Sutton) . . 319
„ "Cercopithecus cynosurus," thickness of bones in (J. B. Sutton) . 320
„ see *Baboon*.
MOORE (*Norman*), ulceration of the larynx from a case of measles, and from a case of scarlet fever 22
„ lung with impacted foreign body 23
„ abnormal heart [fibrous structures resembling valves in left ventricle] . 29
„ *report* of Committee on ditto (J. F. Payne, P. H. Pye-Smith, and S. Coupland) 30
„ variety in the structure of the heart 31
„ endocarditis, with miliary abscesses of the heart, in a case of hip-joint disease 52
„ aneurysms in children 71
„ carcinoma of œsophagus 79
„ cases of gastric ulcer associated with general degeneration of the arteries . 94
„ two cases of simple ulcer of the duodenum 98
„ lympho-sarcoma invading the duodenum 99
„ polypus of the stomach 106
„ stricture of intestine at the ileo-cæcal valve . . . 112
„ cases of ulceration of vermiform appendix in typhoid fever . . 113
„ tubercle of the liver in an adult 133
„ case of visceral syphilis 133
„ double hydrosalpinx 182
„ diaphragm in a case of rickets 185
„ deep ulceration of cranium 209
„ elbow-joint from a case of scarlet fever 225
„ rheumatic arthritis from a Roman tomb 226
MORBID GROWTHS 233-269
„ see COMMITTEE on (Reports).
MORGAN (*John H.*), multiple growths in the bladder . . . 157
MORISON (*B. G.*), case of laryngeal phthisis . . . 21
„ deposit of lime salts in mucous membrane of hepatic ducts in an ox . 137
MORRIS (*Henry*), stomach from a case of acute gastrorrhœa, or acute dilatation of the stomach; death in forty hours from onset of vomiting . . 82
„ a case of osteitis deformans (with plate from photographs) . . 188
MORRIS (*Malcolm*), case of so-called xanthoma tuberosum [of diabetes] . 278
„ *report* on ditto (H. R. Crocker and A. Sangster) . . . 284
„ *postscript* to ditto (Jonathan Hutchinson) 285
MUSCLES, abnormality of, near the shoulder-joint (C. B. Lockwood) . 227
MYOMA, see *Fibro-myoma*.

NECK, extensive sloughing of, "nondescript" lympho-sarcomatous tumour (A. E. Durham) 245
„ recurrent cartilaginous tumour of (Geo. Lawson) . . . 261
NEPHRITIS (acute) (F. Taylor) 38
NERVES, amputation changes in (W. H. White and W. Edmunds) . 16
„ spinal, from three cases of infantile paralysis (W. Edmunds) . . 15
„ abdominal sympathetic, dissection of, from a case of Addison's disease (J. F. Goodhart) 271
NERVOUS SYSTEM, DISEASES of, &c. 1-18
„ condition of, in diabetes, see *Diabetes* (discussion on).

NODULES, subcutaneous fibrous, following rheumatism (J. Cavafy) . 41
„ rheumatic (A. Money) 45
„ — analogy between those of children and heart disease (F. D. Drewitt) . 50
„ — microscopical characters of, removed from right elbow and pericardium (A. Money) 49

OBLITERATION, see *Artery* (coronary), obliteration of.

OBSTRUCTION, see *Intestines* (obstruction of).

ŒSOPHAGUS, CANCER of, with perforation into right lung; upper lobes filled with decomposing food (F. S. Eve) 80
„ carcinoma of (N. Moore) 79

OMENTUM, carcinoma of (B. Fenwick) 269

OSSEOUS SYSTEM, DISEASES, &c., of . . . 185-229

OSTEITIS DEFORMANS, case of, with plate from photographs (H. Morris) . 188
„ curvature of the femur due to (A. A. Bowlby) . . . 192

OSTEO-MALACIA, juvenile (R. Barwell) 205
„ rachitic, extreme deformity from (R. Barwell) . . . 202
„ see *Rickets*.

OSTEO-SARCOMA, enormous, of the left femur in a boy (A. E. Durham) . 265

OSTRICH of South America, "Rhea Darwinii," bone disease in (J. B. Sutton) 316

PANCREAS, primary cancer of (P. Kidd) 136

PARALYSIS, INFANTILE, spinal nerves from three cases of (W. Edmunds) . 15

PARAPLEGIA caused by sarcomatous blood-cyst of spine (W. H. Kesteven) 216

PARASITES, remarkable case of, in a small W. African carnivore (J. B. Sutton) 325

PAROVARIUM and broad ligament, incipient cystic disease of (A. Doran) . 169

PAVY (*F. W.*), *remarks* in DISCUSSION ON DIABETES [chemical condition of the blood in diabetes, maltose, &c.] 391

PAYNE (*J. F.*), *report* on N. Moore's case of abnormal heart . . 30
„ *report* on Dr. Handfield Jones's cases of obstruction of cerebral arteries by atheroma 60
„ *report* on S. J. Sharkey's case of syphilitic inflammation of the capsule of the liver 122
„ *report* on the specimens exhibited in the DISCUSSION ON DIABETES . 397

PERICARDIUM, adherent (A. Money) 45

PERIHEPATITIS, syphilitic, case of (S. J. Sharkey) . . . 118

PERINÆUM, testicle in the, with congenital inguinal hernia and acute hydrocele (W. R. Williams) 168

PHTHISIS, non-connection with diabetes, see *Diabetes* (D. Powell in discussion on).
„ laryngeal, case of (B. G. Morison) 21

PIGMENTATION of the cervix uteri (R. Barnes) . . . 176

PLEURA, lobulated lamellar fibroma on the (F. C. Turner) . . 19
„ secondary growths in, in fibro-myoma of uterus (D. W. Finlay) . 177

PLEURAL CAVITY, left, rupture of renal abscess into (J. R. Lunn) . 138

POISONING by sulphuric acid, with intense inflammation of the transverse colon (W. Hale White) 96

POLYPOID GROWTHS, diffuse, of large intestine (A. A. Bowlby) . . 108
POLYPUS, removal of, followed by exfoliation of petrous portion of temporal bone, &c. (W. J. Roeckel) 232
„ intestinal, causing intussusception, cured after sloughing of strangulated bowel (A. A. Bowlby) 106
„ connective-tissue, of rectum, very large (A. A. Bowlby) . . 107
„ of the stomach (N. Moore) 106
„ mucous, of the urinary bladder (S. G. Shattock) . . . 150
POWELL (*Douglas*), *remarks* in DISCUSSION ON DIABETES [non-connection of phthisis and diabetes] 393
PROSTATE, sarcoma of, of very rapid development (S. West) . . 145
PULMONARY DISEASE, see *Lungs*.
PUSTULE, MALIGNANT, case of (T. Bryant) 293
PYÆMIA, death from, in a case of severe syphilitic disease of facial bones (V. Horsley) 208
„ micrococci in (V. Horsley) 298
„ in a male "Python sebæ," W. Africa (J. B. Sutton) . . . 323
PYE-SMITH (*P. H.*), colloid cancer of stomach, lymph-glands, and lungs . 100
„ *report* on N. Moore's case of abnormal heart . . . 30
PYLORIC OBSTRUCTION, cases of dilated stomach not due to (Jas. F. Goodhart) 88
PYTHON SEBÆ, male, pyæmia in (J. B. Sutton) . . . 323
RALFE (*Charles Henry*), tests for albumen in urine . . . 143
„ *remarks* in DISCUSSION ON DIABETES [aceto-acetic acid test for indicating presence of acetone, &c.] 329
RECTUM, very large connective-tissue polypus of (A. A. Bowlby) . . 107
RESPIRATION, ORGANS OF, DISEASES, &c. 19-28
RETROFLEXION of the uterus in a baboon (J. B. Sutton) . . 326
RHEUMATIC NODULES (A. Money) 45
„ — analogy between those of children, and heart disease (F. D. Drewitt) . 50
RHEUMATISM, subcutaneous fibrous nodules following (J. Cavafy) . 41
„ see *Arthritis* (rheumatic).
RICKETS, diaphragm in a case of (N. Moore) . . . 185
„ extreme deformity from rachitic osteo-malacia (R. Barwell) . . 202
„ in a baboon (J. B. Sutton) 310
„ — "Cynocephalus porcarius" (J. B. Sutton) . . . 312
RICKETY CHANGES in bone, in a case of extensive hyperostosis (J. F. Goodhart) 197
ROECKEL (*Waldemar J.*), piece of petrous portion of left temporal bone, including part of external auditory meatus which exfoliated after removal of a polypus 232
SANGSTER (*Alfred*), *report* on Mr. Malcolm Morris's case of xanthoma in connection with diabetes 284
SARCOMA of a diverticulum of the bladder (W. Roger Williams) . 152
„ of prostate and bladder of very rapid development (S. West) . . 145
„ see *Cysts* (sarcomatous).
„ adeno-, of testis, &c., in a case of cardiac malformation (V. Horsley) . 161
„ alveolar, of the capsule of the right kidney (J. K. Thornton) . . 141
„ — of skull, secondary growth of bladder (H. H. Clutton) . . 212
„ and gland, melanotic spindle-celled alveolar (H. A. Lediard) . . 269
„ calcified round-celled, of the bones of the leg (W. R. Williams) . 267
„ disseminated, case of (W. B. Hadden) 236
„ see *Lympho-sarcoma*, *Osteo-sarcoma*.
„ villous, of the bladder (W. Roger Williams) . . . 156

SARCOMATA, multiple ulcérating and sloughing in various parts of body, especially in the limbs (A. E. Durham) 243
SAVAGE (*Geo. H.*) and W. HALE WHITE, on the causes of holes in the brain, together with two cases of universal cystic degeneration . . 1
„ *report* on the specimens exhibited in the DISCUSSION ON DIABETES . 397
SCARLET FEVER, elbow-joint from a case of (N. Moore) . . 225
„ ulceration of larynx from a case of (N. Moore) . . . 22
SEA-SICKNESS, death by syncope after, in a case of *Addison's disease* without melasma (W. W. Greene) 270
SHARKEY (*Seymour J.*), case of arteritis, with thrombosis of both middle cerebral arteries during secondary stage of syphilis . . . 10
„ case of syphilitic perihepatitis 118
„ *report* on ditto (S. Coupland and J. F. Payne) . . . 122
SHATTOCK (*Samuel G.*), mucous polypus of the urinary bladder . . 150
„ two specimens of urinary calculi from animals, composed of carbonate of lime 326
SHOULDER-JOINT, abnormality of bones and muscles near (C. B. Lockwood) 227
SILCOCK (*A. Quarry*), case of diffuse aneurysm of the abdominal aorta . 68
„ stomach exhibiting the condition known as phlegmonous gastritis . 90
SKELETON, extensive hyperostosis of, with bone softening and rickety changes, probably syphilitic (Jas. F. Goodhart) 197
SKIN, DISEASES OF THE 272-290
„ and subcutaneous tissue of the sole, congenital hypertrophy of (F. S. Eve) 298
SKULL, see *Cranium*.
SLOUGHING, extensive, of the neck; lympho-sarcomatous tumour (A. E. Durham) 245
„ lympho-sarcoma of the back, &c. (F. Taylor) . . . 247
SMITH (*P. H. Pye-*), see *Pye-Smith*.
SOLE, hypertrophy of the skin of (F. S. Eve) . . . 298
SOUTHEY (*Reginald*), case of symmetrical gangrene . . . 286
SPECIAL SENSE, ORGANS OF, DISEASES, &c. . . . 230-232
SPECIMENS, MISCELLANEOUS 291-307
„ from the LOWER ANIMALS 308-327
SPINE, sarcomatous blood cyst of, causing paraplegia (W. H. Kesteven) . 216
SPLEEN, infarcts in (F. Taylor) 38
STENOSIS of mitral orifice and valve (F. C. Turner) . . . 36
„ of tricuspid valve (B. Fenwick) 35
STERNUM, fracture of, with costo-chondral dislocation (W. A. Lane) . 223
STOMACH, INTESTINES, &c., DISEASES of . . . 79-137
„ acute dilatation of, death within forty hours of onset of vomiting (H. Morris) 82
„ from a case of acute gastrorrhœa, or acute dilatation of stomach (H. Morris) 82
„ dilated, cases of, not due to pyloric obstruction, observed in *post-mortem* room of Guy's Hospital, 1875-82 (Jas. F. Goodhart) . . . 88
„ colloid cancer of (P. H. Pye-Smith) 100
„ epithelioma of, with diffusion of secondary deposits in other viscera and the integuments (D. W. Finlay) 102
„ exhibiting the condition known as phlegmonous gastritis (A. Q. Silcock) . 90
„ polypus of (N. Moore) 106
„ case of ruptured (J. R. Lunn) 81
„ see *Ulcer* (gastric).

STRICTURE, see *Intestine.*

SUGAR in URINE, see *Diabetes, Urine.*

SULPHURIC ACID, poisoning by, with intense inflammation of the transverse colon (W. Hale White) 96

SUPRA-RENAL CAPSULES, DISEASES of . . . 270, 271

SUTTON (*J. Bland*), encephalocele 18

„ rickets in a baboon 310

„ — skull of a baboon, with extraordinary thickness of its bones . . 311

„ rickets in a baboon, "cynocephalus porcarius," W. Africa . . 312

„ bone disease in animals: an Indian monitor . . . 315

„ ditto: "Rhea Darwinii," South American ostrich . . . 316

„ ditto: Macaque monkey, aged three years . . . 317

„ ditto: "Cercopithecus Diana" 319

„ ditto: "Cercopithecus cynosurus" and Macaque monkey . . 320

„ ditto: tabular view of normal and abnormal processes in bone development 322

„ pyæmia in a male python "Python sebæ," West Africa . . 323

„ two hundred abscesses in the liver of a kangaroo . . . 325

„ remarkable case of parasites 325

„ retroflexion of the uterus in a baboon 326

SYNCOPE, death by, apparently from sea-sickness, in a case of Addison's disease without melasma (W. W. Greene) 270

SYPHILIS, secondary, arteritis and thrombosis of middle cerebral arteries in (S. J. Sharkey) 10

„ visceral, case of (N. Moore) 133

SYPHILITIC bone softening and rickety changes (Jas. F. Goodhart) . 197

„ disease, severe, of facial bones and viscera; death from pyæmia (V. Horsley) 208

„ gumma of the heart (G. C. Henderson) 53

„ peribepatitis, case of (S. J. Sharkey) 118

TÆNIA ELLIPTICA (F. C. Turner) 306

TAYLOR (*Frederick*), ulcerative endocarditis, infarcts in spleen and kidney, acute nephritis 38

„ intestinal obstruction resulting from adhesion of the ileum to the mesentery 137

„ sloughing lympho-sarcoma of the back, with other lesions of the skin and internal organs 247

„ *remarks* in DISCUSSION ON DIABETES [condition of nervous system, mode of death in diabetes] 367

TAYLOR (*Seymour*), *remarks* in DISCUSSION ON DIABETES . . 365

TAYLOR (*Thomas*), examination of calculus with mulberry calculus nucleus 149

TEMPORAL BONE, exfoliation of petrous portion of, including part of external auditory meatus, after removal of a polypus (W. J. Roeckel) . . 232

TESTIS in the perineum, with congenital inguinal hernia and acute hydrocele (W. R. Williams) 168

„ undescended, primary cancer of, &c. (F. A. Mahomed) . . 182

„ adeno-sarcoma of, in a case of cardiac malformation (V. Horsley) . 161

THIN (*George*), see *Hillis.*

THORNTON (*J. Knowsley*), alveolar sarcoma of the capsule of the right kidney 141

THROMBOSIS of middle cerebral arteries, in secondary syphilis (S. J. Sharkey) 10

„ of left common iliac artery, causing gangrene of right leg (J. K. Fowler) . 77

„ of the pulmonary artery (para-vaginal and dermoid cysts) (F. A. Mahomed) 72

THYMUS, cancer of, &c. (F. A. Mahomed) 182
TIBIA, comminuted fracture of, with impaction of the anterior tibial vessels and nerve, followed by gangrene (F. S. Edwards) . . . 222
TONGUE, tubercular disease of (W. B. Hadden) . . . 135
„ tubercular ulcers of (Stanley Boyd) 134
TREVES (*Frederick*), congenital malformation of the skull . . 228
TRICUSPID VALVES, stenosis of (B. Fenwick) . . . 35
„ recent vegetations on (F. C. Turner) 36
TUBERCLE of the liver in an adult (N. Moore) . . . 133
„ bacilli of, found in contents of cavities and not in lung tissue (S. West) . 126
TUBERCULAR DISEASE of the tongue (W. B. Hadden) . . 135
„ ULCERS of the tongue (Stanley Boyd) 134
TUMOUR, recurrent cartilaginous, of the head and neck [lower jaw] (Geo. Lawson) 261
„ lympho-sarcomatous, of the neck (A. E. Durham) . . . 245
„ mediastinal, rapid growth; sudden death (S. West) . . . 233
TUMOURS 233-269
TURNER (*F. Charlewood*), lobulated lamellar fibroma on the pleura . 19
„ malformed heart, consisting of two cavities . . . 32
„ stenosis of the mitral orifice, recent vegetations on the mitral, aortic, and tricuspid valves; sacculated fibrinous coagulum loose in left auricle . 36
„ lardaceous disease of the liver, the infiltration appearing to follow the course of the capillaries within the lobules of the organ . . . 131
„ tænia elliptica 306
„ ascaris mystax vel alata 307
TYPHOID FEVER, cases of ulceration of vermiform appendix in (N. Moore) 113
„ ulceration of large intestine with perforation (S. West) . . 114
„ see *Enteric*.

ULCER, simple, of duodenum, two cases (N. Moore) . . . 98
„ gastric, associated with general degeneration of the arteries (N. Moore) . 94
„ tubercular of the tongue (Stanley Boyd) 134
ULCERATING and sloughing SARCOMATA, multiple, specially in the limbs (A. E. Durham) 243
ULCERATION, deep, of cranium (N. Moore) 209
„ of larynx, from a case of measles and a case of scarlet fever (N. Moore) . 22
„ of large intestine with perforation in typhoid fever (S. West) . . 114
„ of large and small intestines in enteric fever (J. Curnow) . . 116
„ of vermiform appendix in typhoid fever (N. Moore) . . . 113
„ spreading, in a case of lympho-sarcoma of the back (J. N. C. Davies-Colley) 258
URETERS, dilatation of, in case of extreme prolapse of uterus, &c. (A. E. Barker) 181
URINARY ORGANS, DISEASES, &c., of . . . 138-184
URINE, examination of, in insane persons, see *Diabetes* (Hale White in discussion on) 348
„ tests for albumen in (C. H. Ralfe) 113
„ quantitative estimation of sugar in, Duhomme's method . . 395
UTERI, CERVIX, pigmentation of (R. Barnes) . . . 176
UTERUS, fibro-myoma of, becoming sarcomatous, with secondary growths in pleura, heart, and kidney (D. W. Finlay) . . . 177
„ extreme prolapse of, beneath the pubic arch, obstruction, &c. (A. E. Barker) 181

UTERUS, retroflexion of, in a baboon (J. B. Sutton) . . . 326

VACUOLATION of liver and kidneys in a case of cancer (F. A. Mahomed) . 182
VAGINA, extreme prolapse of, beneath the pubic arch, obstruction, &c. (A. E. Barker) 181
VALVES, see *Aortic, Mitral, Tricuspid, Ileo-cæcal.*
VASCULAR SYSTEM, DISEASES, &c., OF . . . 29-78
VEGETATIONS, recent, on mitral, aortic, and tricuspid valves (F. C. Turner) 36
VENTRICLE, LEFT, fibrous structures resembling valves in (N. Moore) . 29
„ RIGHT, congenital atresia of, ductus arteriosus patent (J. Abercrombie) . 78
VENTRICULAR SEPTUM, abnormal fibrous ring attached to (N. Moore) . 29
VERMIFORM APPENDIX, see *Appendix* vermiformis.
VESSELS, see *Arteries, Veins.*

WEST (*Samuel*), the bacilli of tubercle found in contents of cavities and not in lung tissue 26
„ aneurysm of the middle part of the arch of the aorta; death from embolism of the aorta detached from the left ventricle . . . 62
„ aneurysm of the aorta, rupturing into the pulmonary artery . . 64
„ dissecting aneurysm of the first part of the arch of the aorta . . 65
„ complete obliteration of one coronary artery; sudden death; on the anastomosis of the coronary arteries 66
„ typhoid fever, ulceration of large intestine with perforation . . 114
„ sarcoma of prostate and bladder, of very rapid development . . 145
„ mediastinal tumour, rapid growth; sudden death . . . 233
WHITE (*W. Hale*), case of sulphuric acid poisoning, with intense inflammation of the transverse colon 96
„ sacculated bladder in a female 146
„ peculiar bony outgrowth from the fibula 227
„ *remarks* in DISCUSSION ON DIABETES [condition of nervous system in diabetes, *post-mortems* of cases at Guy's, and examination of urine in insane persons] 348
„ and WALTER EDMUNDS, amputation, changes in nerves . . 16
„ see *Savage* and White, on causes of holes in the brain.
WILKS (*Samuel*), *remarks* in DISCUSSION ON DIABETES . . 328
„ see *Jones* on morbid conditions of cerebral arteries.
WILLIAMS (*Dawson*), *remarks* in DISCUSSION ON DIABETES [cases from records of Univ. Coll. Hospital, deaths from Registrar-General's Returns] . 374
WILLIAMS (*W. Roger*), sarcoma of a diverticulum of the bladder . 152
„ villous sarcoma of the bladder 156
„ *report* on ditto by Morbid Growths Committee (J. F. Goodhart and H. T. Butlin) 156
„ case of testicle in the perinæum, with congenital inguinal hernia and acute hydrocele 168
„ calcified round-celled sarcoma of the bones of the leg. . . 267

XANTHOMA TUBEROSUM, case of so-called (M. Morris) . . 278

3 2044 102 983 053